



PATIENT

Eddie Curran

SPECIES

Canine

BREED

Bichon Frise

SEX

Neutered male

AGE

12 years

WEIGHT

14 lbs

INTERPRETED BY

Remo Lobetti, BVSc,
MMedVet (Med),
PhD, Dipl. ECVIM

IMAGING PERFORMED BY

M Santiago

HOSPITAL NAME

Alison AH

REFERRING VET

Dr. Klein

INVOICE

75288

DATE

5/11/26

PRESENTING CLINICAL SIGNS

History: Pt presented for an abdominal ultrasound due to upper GI issues for the past 7-10 days. Pt had analsaculectomy approx 3 weeks ago. Mass came back as adenocarcinoma with margins. Pt has decreased energy, vomiting and decreased appetite. No C/S. CBC/Chem/CPL unremarkable with the exception of a slightly elevated ALT.

ULTRASONOGRAPHIC EXAMINATION OF THE ABDOMEN

Urinary System

The urinary bladder is small with a normal thickness and smooth appearance of the wall. Normal anechoic urine with no sediment or uroliths evident.

Normal appearance of the trigone area, proximal urethra, and iliac blood vessels.

Normal appearance and size of the iliac lymph nodes. Ureters not visualized, which can be considered a normal finding.

Normal renal size (left measured 3.7 cm, right measured 4.2 cm), architecture, echogenic appearance, cortico-medullary differentiation, which maintains a 1:3 cortex to medulla ratio, pelvis, and capsule. No infarcts, mineralization or renoliths evident. The prostate is small and hypoechogenic.

Adrenal Glands

The left adrenal gland is not clearly visualized, but appears to be of normal shape, echogenic appearance and size. The right adrenal gland was not visualized.

Spleen

Normal size and echogenic appearance. Smooth homogenous parenchyma and regular curvilinear capsule. Normal volume of the splenic vasculature without any overt congestion or thrombosis evident. No inflammatory, neoplastic, infarction, or infiltrative changes evident. The spleen measured 1.4 cm.

Liver

Normal size with a diffuse, mottled, echogenic, coarse and nodular appearance, normal portal markings and regular curvilinear capsule. The nodules are diffuse, hypoechogenic, parenchymal and measure up to 0.6 x 0.8 cm in size. No masses evident. Normal appearance of the hepatic and portal vasculature.

Gallbladder

The gallbladder is small containing normal anechoic bile. Normal thickness and echogenic appearance of the wall. Normal size and appearance of the cystic and common bile duct.



PATIENT

Eddie Curran

SPECIES

Canine

BREED

Bichon Frise

SEX

Neutered male

AGE

12 years

WEIGHT

14 lbs

INTERPRETED BY

Remo Lobetti, BVSc,
MMedVet (Med),
PhD, Dipl. ECVIM

IMAGING PERFORMED BY

M Santiago

HOSPITAL NAME

Alison AH

REFERRING VET

Dr. Klein

INVOICE

75288

DATE

5/11/26

Gastrointestinal

Normal appearance of the stomach, duodenum, small intestine, ileo-cecal junction, and colon with no loss of layering, 1:3 muscularis to mucosa ratio, normal wall thickness and peristaltic activity, and no distension of the lumen. A small amount of fluid was present within the stomach.

Pancreas

The visible sections of the pancreas are of normal size and echogenic appearance with a regular capsule. Normal echogenic appearance of the mesentery and fat surrounding the pancreas.

Free Abdomen

Normal mesenteric lymph nodes.

No ascites evident.

ULTRASONOGRAPHIC FINDINGS

- Nodular hepatopathy.

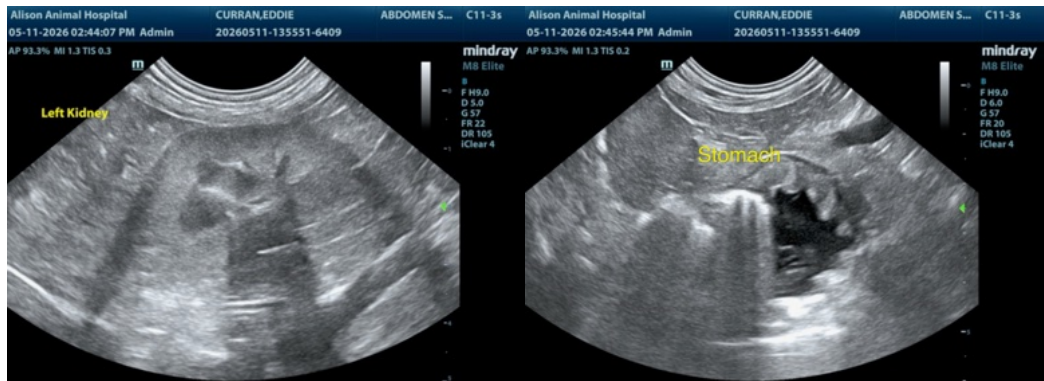
INTERPRETATION OF THE FINDINGS & FURTHER RECOMMENDATIONS

Etiologies for the nodular hepatopathy would be nodular hyperplasia, chronic hepatitis, granulomatous disease and with the history of anal sac adenocarcinoma, infiltrative neoplasia.

Further assessment would be three view thoracic radiographs (if not already done) and FNA cytology of the liver.

A tru cut or wedge biopsy of the liver may be required for a final etiological diagnosis.

Specific therapy would be dependent on an etiological diagnosis.





PATIENT

Eddie Curran

SPECIES

Canine

BREED

Bichon Frise

SEX

Neutered male

AGE

12 years

WEIGHT

14 lbs

INTERPRETED BY

Remo Lobetti, BVSc,
MMedVet (Med),
PhD, Dipl. ECVIM

**IMAGING
PERFORMED BY**

M Santiago

HOSPITAL NAME

Alison AH

REFERRING VET

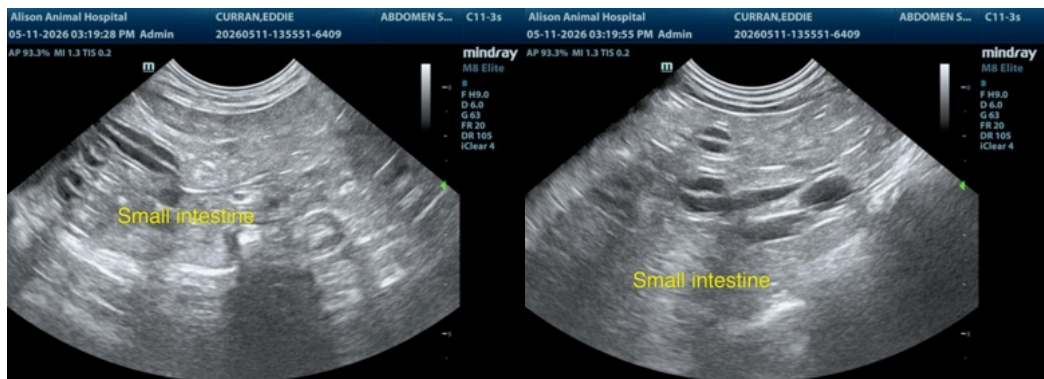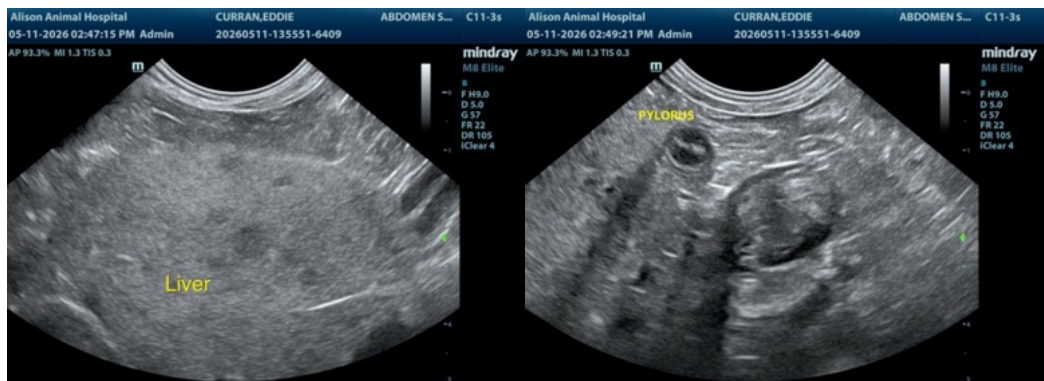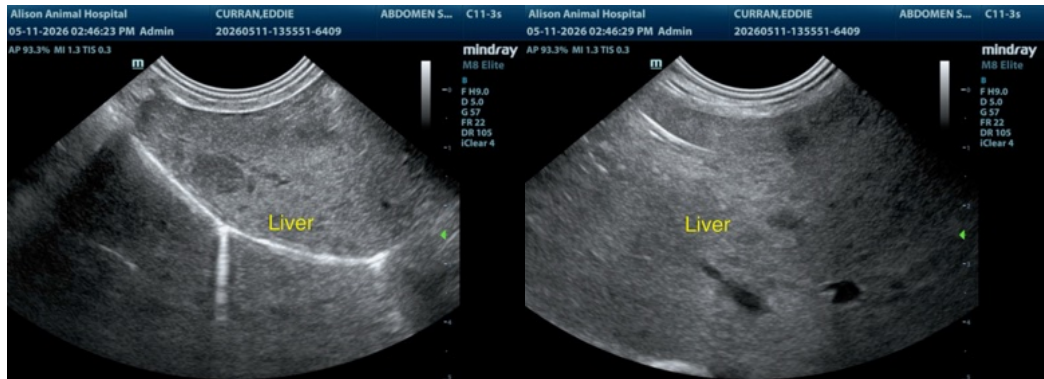
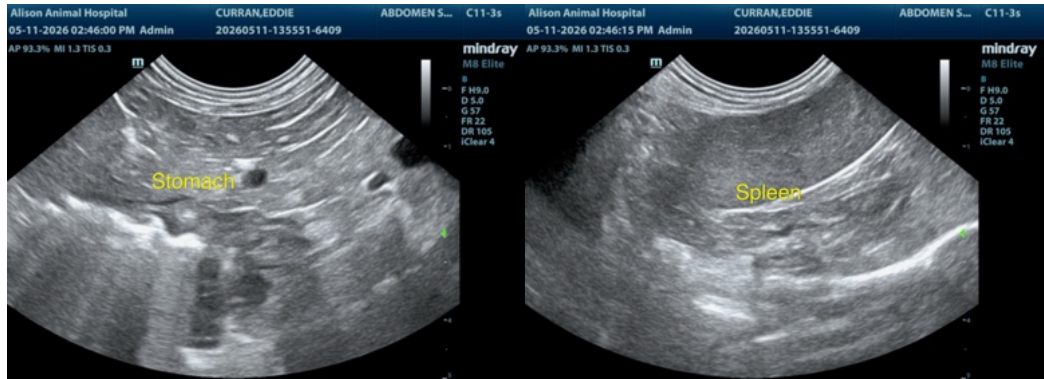
Dr. Klein

INVOICE

75288

DATE

5/11/26





PATIENT

Eddie Curran

SPECIES

Canine

BREED

Bichon Frise

SEX

Neutered male

AGE

12 years

WEIGHT

14 lbs

INTERPRETED BY

Remo Lobetti, BVSc,
MMedVet (Med),
PhD, Dipl. ECVIM

IMAGING PERFORMED BY

M Santiago

HOSPITAL NAME

Alison AH

REFERRING VET

Dr. Klein

INVOICE

75288

DATE

5/11/26

The information and recommendations provided are based on the images presented by the referring veterinarian/sonographer. No evaluation can be communicated regarding pathology that was not visible in the image/video clips provided.

Thank you for this referral. If the clinical or image interpretation does not parallel your findings or if I can be of any further assistance please contact me.

Remo Lobetti, BVSc, MMedVet (Med), PhD, Dipl. ECVIM (Internal Medicine)

info@sonopath.com