



PATIENT

Regy Larsen

SPECIES

Canine

BREED

Miniature Poodle

SEX

Spayed female

AGE

3 years

WEIGHT

9.2 kg

INTERPRETED BY

Remo Lobetti, BVSc,
MMedVet (Med),
PhD, Dipl. ECVIM

IMAGING PERFORMED BY

Matthew Guenther

HOSPITAL NAME

Hidden Tails Mobile
VU

REFERRING VET

Dr. Hall

INVOICE

75081

DATE

5/1/26

PRESENTING CLINICAL SIGNS

History: Hx of IBD being treated with Budesonide. Concern about tense and painful abdomen vs spinal pain. Radiographs show narrowed T10-13 disc spaces and mineralization T10-11. Also narrowed L3-L4 and L4-L5. No proprioceptive deficits. Some urinary incontinence. Ruling out intra-abdominal causes of pain.

Current meds: Cerenia sid prn. Amantadine 100mg bid (recently started). Reconcile 8mg sid. Budesonide once daily (dose not specified).

Abnormal PE/Chem/CBC/UA Results: Idexx Enteropathy panel pending. UA WNL.

ULTRASONOGRAPHIC EXAMINATION OF THE ABDOMEN

Urinary System

The urinary bladder is full with a normal thickness and smooth appearance of the wall. Normal anechoic urine with no sediment or uroliths evident.

Normal appearance of the trigone area, proximal urethra, and iliac blood vessels.

Normal appearance and size of the iliac lymph nodes. Ureters not visualized, which can be considered a normal finding.

Normal renal size (left measured 5.1 cm, right measured 4.8 cm), architecture, echogenic appearance, cortico-medullary differentiation, which maintains a 1:3 cortex to medulla ratio, pelvis, and capsule. No infarcts, mineralization or renoliths evident.

Adrenal Glands

Normal shape, echogenic appearance, size, position, and appearance of the visible peri-adrenal vasculature. Left adrenal gland measured 0.32 cm and 0.28 cm in width. The right adrenal gland measured 0.51 cm in width.

Spleen

Normal size and echogenic appearance. Smooth homogenous parenchyma and regular curvilinear capsule. Normal volume of the splenic vasculature without any overt congestion or thrombosis evident. No inflammatory, neoplastic, infarction, or infiltrative changes evident. The spleen measured 1.5 cm in width.

Liver

Normal size, echogenic appearance, portal markings, and regular curvilinear capsule. No nodules or masses evident. Normal appearance of the hepatic and portal vasculature.



PATIENT

Regy Larsen

SPECIES

Canine

BREED

Miniature Poodle

SEX

Spayed female

AGE

3 years

WEIGHT

9.2 kg

INTERPRETED BY

Remo Lobetti, BVSc,
MMedVet (Med),
PhD, Dipl. ECVIM

IMAGING PERFORMED BY

Matthew Guenther

HOSPITAL NAME

Hidden Tails Mobile
VU

REFERRING VET

Dr. Hall

INVOICE

75081

DATE

5/1/26

Gallbladder

The gallbladder is full containing a moderate amount of non-adhered, hyperechogenic sediment. Normal thickness and echogenic appearance of the wall. Normal size and appearance of the cystic and common bile duct.

Gastrointestinal

Normal appearance of the stomach, duodenum, small intestine, ileo-cecal junction, and colon with no loss of layering, 1:3 muscularis to mucosa ratio, normal wall thickness and peristaltic activity, and no distension of the lumen. A small amount of gas is present within the stomach. Fecal material was present within the colon.

Pancreas

The visible sections of the pancreas are of normal size and echogenic appearance with a regular capsule. Normal echogenic appearance of the mesentery and fat surrounding the pancreas. The right pancreas was 1.2 cm in width.

Free Abdomen

Normal mesenteric lymph nodes.

No ascites evident.

ULTRASONOGRAPHIC FINDINGS

- Gallbladder sediment.

INTERPRETATION OF THE FINDINGS & FURTHER RECOMMENDATIONS

In essence a normal ultrasound examination of the abdomen as the gallbladder sediment can be considered an incidental finding. However, monitoring for the development of a mucocele would be recommended.



PATIENT

Regy Larsen

SPECIES

Canine

BREED

Miniature Poodle

SEX

Spayed female

AGE

3 years

WEIGHT

9.2 kg

INTERPRETED BY

Remo Lobetti, BVSc,
MMedVet (Med),
PhD, Dipl. ECVIM

IMAGING PERFORMED BY

Matthew Guenther

HOSPITAL NAME

Hidden Tails Mobile
VU

REFERRING VET

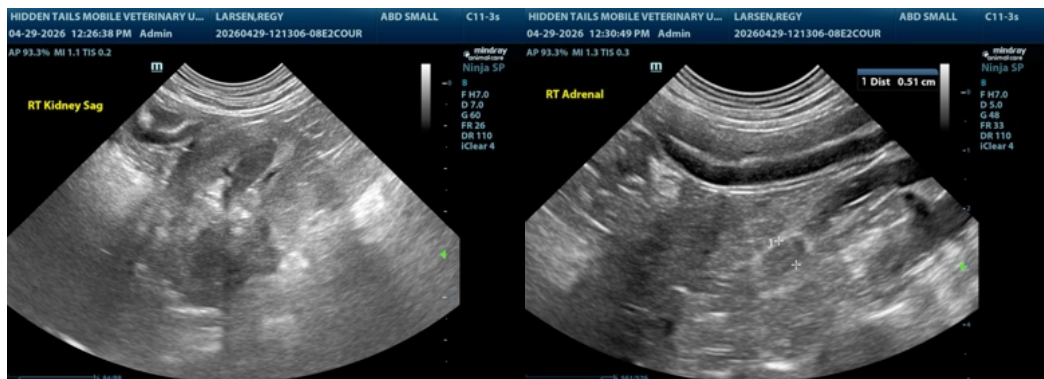
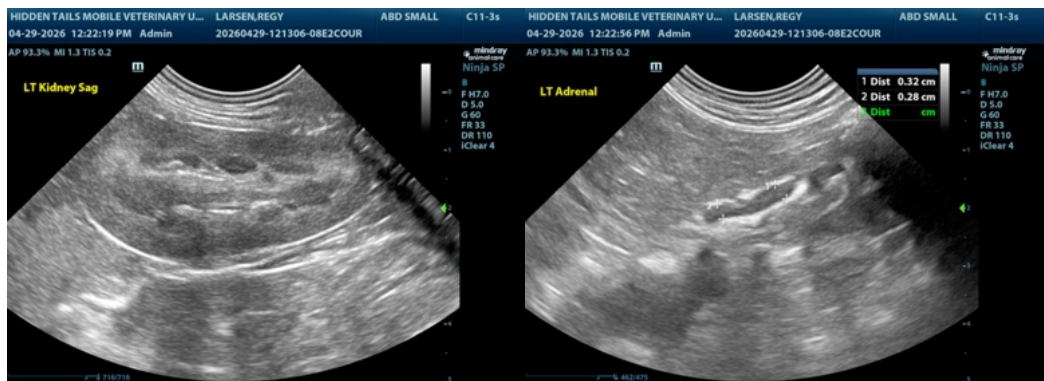
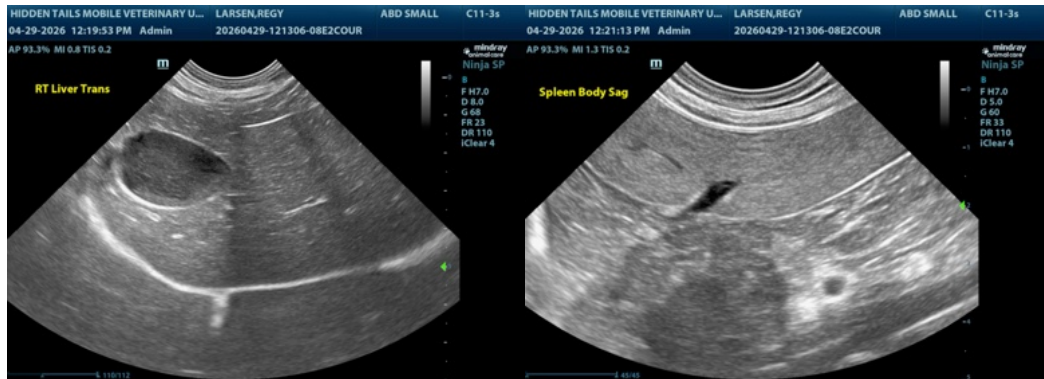
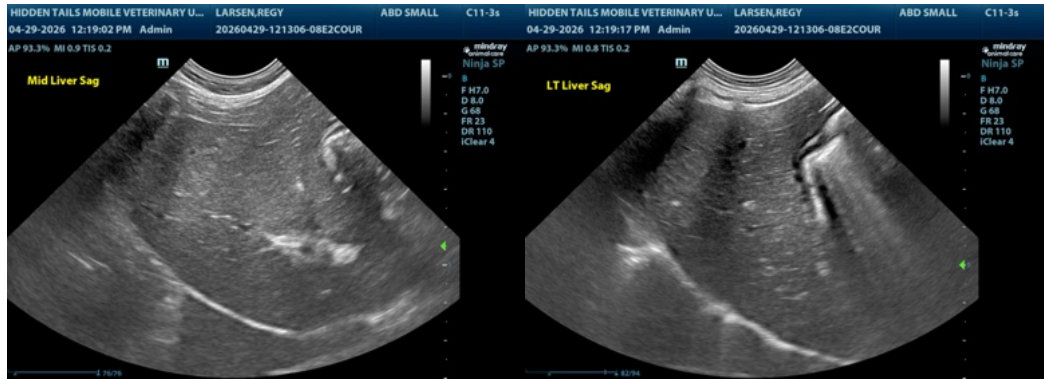
Dr. Hall

INVOICE

75081

DATE

5/1/26





PATIENT

Regy Larsen

SPECIES

Canine

BREED

Miniature Poodle

SEX

Spayed female

AGE

3 years

WEIGHT

9.2 kg

INTERPRETED BY

Remo Lobetti, BVSc,
MMedVet (Med),
PhD, Dipl. ECVIM

IMAGING PERFORMED BY

Matthew Guenther

HOSPITAL NAME

Hidden Tails Mobile
VU

REFERRING VET

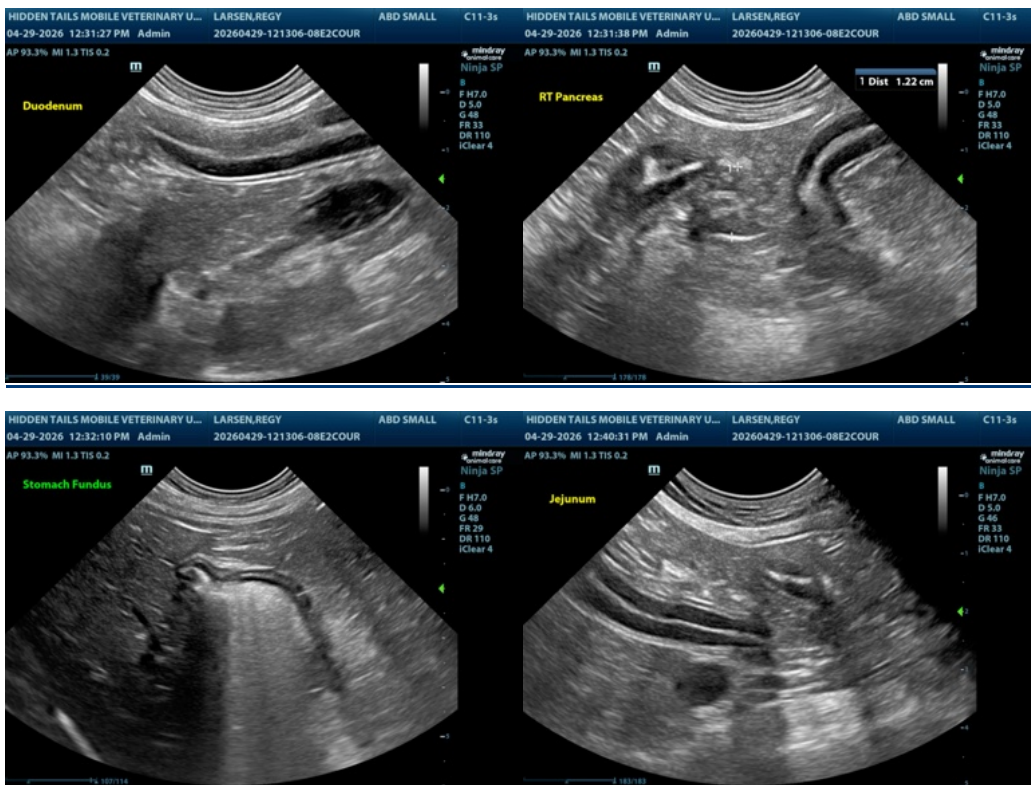
Dr. Hall

INVOICE

75081

DATE

5/1/26



The information and recommendations provided are based on the images presented by the referring veterinarian/sonographer. No evaluation can be communicated regarding pathology that was not visible in the image/video clips provided.

Thank you for this referral. If the clinical or image interpretation does not parallel your findings or if I can be of any further assistance please contact me.

Remo Lobetti, BVSc, MMedVet (Med), PhD, Dipl. ECVIM (Internal Medicine)

info@sonopath.com