



## PATIENT

Vecchi LoConti

## SPECIES

Canine

## BREED

Puggle

## SEX

Spayed female

## AGE

10 years

## WEIGHT

22.7 lbs

## INTERPRETED BY

Remo Lobetti, BVSc,  
MMedVet (Med),  
PhD, Dipl. ECVIM

## IMAGING PERFORMED BY

Dr. Striano Kaplan

## HOSPITAL NAME

Ramsey VH

## REFERRING VET

Dr. Striano Kaplan

## INVOICE

74329

## DATE

4/9/26

## PRESENTING CLINICAL SIGNS

History: pre anesthetic for MCT on vulva

Abnormal PE/Chem/CBC/UA Results: 1. Mast cell tumor left labial fold- ungraded, unstaged 2. Inappropriate urination (1 urinary accident in house): Consider LUTD 3. Acute, isolated incident of vomiting: Consider spurious vs primary GI vs metabolic vs neoplasia 4. Hooded vulva

## ULTRASONOGRAPHIC EXAMINATION OF THE ABDOMEN

### *Urinary System*

The urinary bladder is full with a normal thickness and smooth appearance of the wall. Normal anechoic urine with no sediment or uroliths evident.

Normal appearance of the trigone area, proximal urethra, and iliac blood vessels.

Normal appearance and size of the iliac lymph nodes. Ureters not visualized, which can be considered a normal finding.

Normal renal size (left measured 5.0 cm, right measured 4.9 cm), architecture, echogenic appearance, cortico-medullary differentiation, which maintains a 1:3 cortex to medulla ratio, pelvis, and capsule. No infarcts, mineralization or renoliths evident.

### *Adrenal Glands*

Normal shape, echogenic appearance, size, position, and appearance of the visible peri-adrenal vasculature. Left adrenal gland measured 1.88 cm in length x 0.32 cm and 0.36 cm in width. The right adrenal gland measured 0.39 cm in width.

### *Spleen*

Normal size and echogenic appearance. Smooth homogenous parenchyma and regular curvilinear capsule. Normal volume of the splenic vasculature without any overt congestion or thrombosis evident. No inflammatory, neoplastic, infarction, or infiltrative changes evident. The spleen measures 0.9 cm in width.

### *Liver*

Normal size, echogenic appearance, portal markings, and regular curvilinear capsule. No nodules or masses evident. Normal appearance of the hepatic and portal vasculature.

### *Gallbladder*

The gallbladder is full containing a small amount of adhered, hyperechogenic sediment. Normal thickness and echogenic appearance of the wall. Normal size and appearance of the cystic and common bile duct.



**PATIENT**

Vecchi LoConti

**SPECIES**

Canine

**BREED**

Puggle

**SEX**

Spayed female

**AGE**

10 years

**WEIGHT**

22.7 lbs

**INTERPRETED BY**

Remo Lobetti, BVSc,  
MMedVet (Med),  
PhD, Dipl. ECVIM

**IMAGING PERFORMED BY**

Dr. Striano Kaplan

**HOSPITAL NAME**

Ramsey VH

**REFERRING VET**

Dr. Striano Kaplan

**INVOICE**

74329

**DATE**

4/9/26

**Gastrointestinal**

Normal appearance of the stomach, duodenum, small intestine, ileo-cecal junction, and colon with no loss of layering, 1:3 muscularis to mucosa ratio, normal wall thickness and peristaltic activity, and no distension of the lumen. A small amount of ingesta is present in the stomach compatible with a recent meal. Fecal material is present in the colon.

**Pancreas**

The visible sections of the pancreas are of normal size and echogenic appearance with a regular capsule. Normal echogenic appearance of the mesentery and fat surrounding the pancreas.

**Free Abdomen**

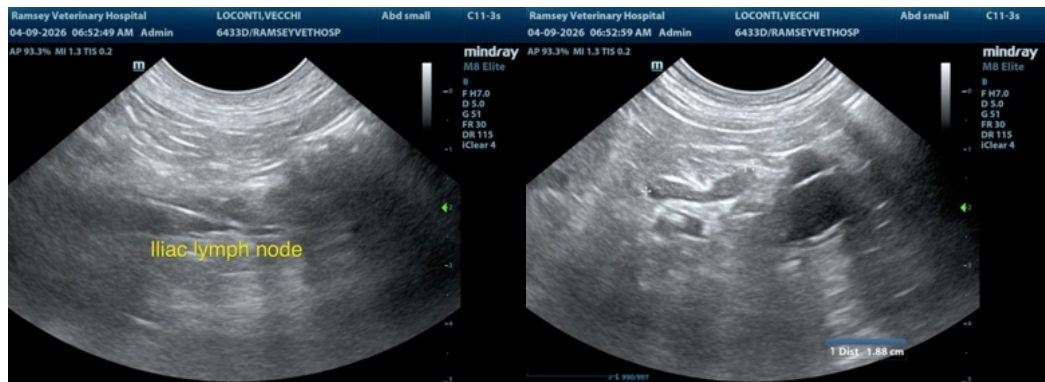
Normal mesenteric lymph nodes.  
No ascites evident.

**ULTRASONOGRAPHIC FINDINGS**

- Gallbladder sediment.

**INTERPRETATION OF THE FINDINGS & FURTHER RECOMMENDATIONS**

On this ultrasound there is no obvious evidence of metastatic mast cell neoplasia. FNA cytology of the liver and spleen could be considered to complete the metastatic screen. Although the gallbladder sediment is most likely an incidental finding, monitoring for the development of a mucocele would be recommended.





**PATIENT**

Vecchi LoConti

**SPECIES**

Canine

**BREED**

Puggle

**SEX**

Spayed female

**AGE**

10 years

**WEIGHT**

22.7 lbs

**INTERPRETED BY**

Remo Lobetti, BVSc,  
MMedVet (Med),  
PhD, Dipl. ECVIM

**IMAGING  
PERFORMED BY**

Dr. Striano Kaplan

**HOSPITAL NAME**

Ramsey VH

**REFERRING VET**

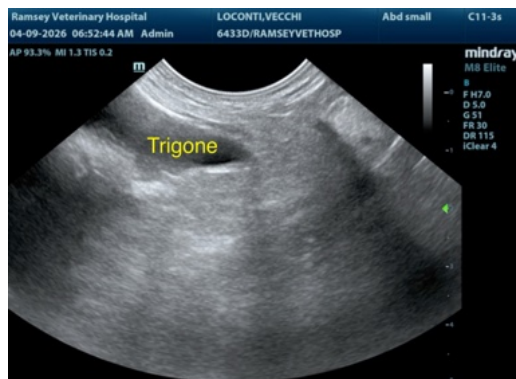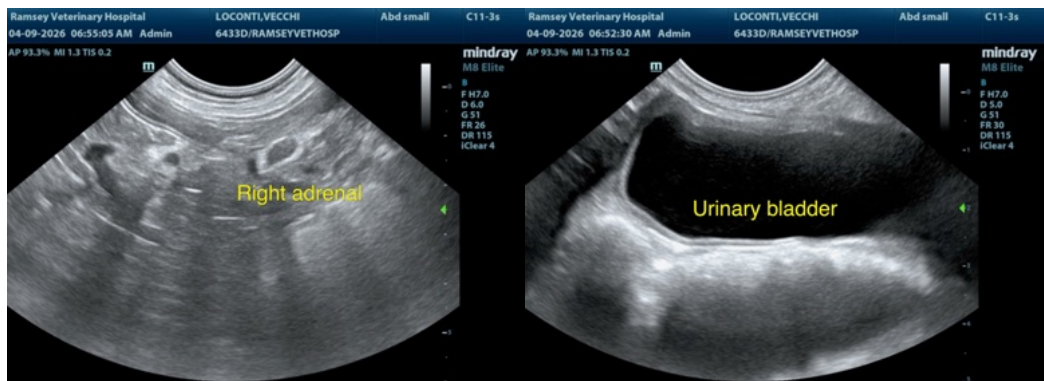
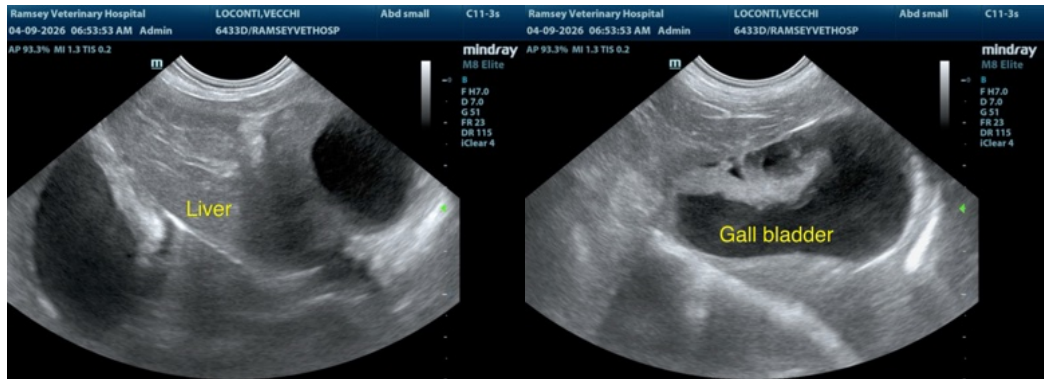
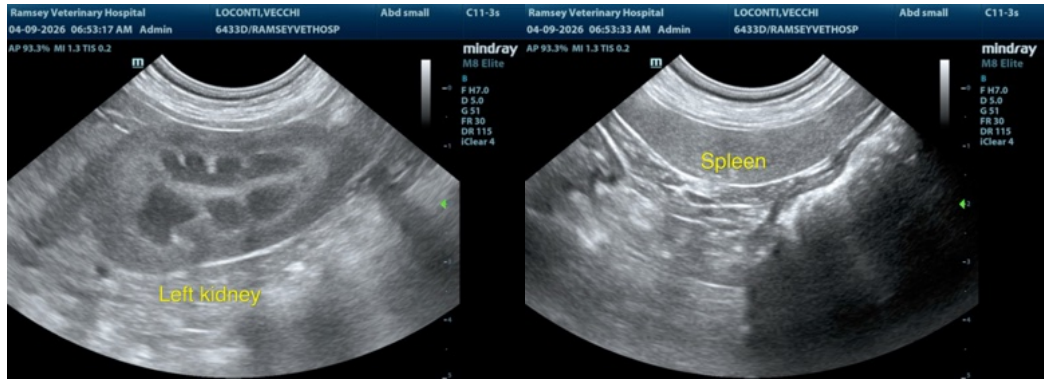
Dr. Striano Kaplan

**INVOICE**

74329

**DATE**

4/9/26





## PATIENT

Vecchi LoConti

## SPECIES

Canine

## BREED

Puggle

## SEX

Spayed female

## AGE

10 years

## WEIGHT

22.7 lbs

## INTERPRETED BY

Remo Lobetti, BVSc,  
MMedVet (Med),  
PhD, Dipl. ECVIM

## IMAGING PERFORMED BY

Dr. Striano Kaplan

## HOSPITAL NAME

Ramsey VH

## REFERRING VET

Dr. Striano Kaplan

## INVOICE

74329

## DATE

4/9/26

The information and recommendations provided are based on the images presented by the referring veterinarian/sonographer. No evaluation can be communicated regarding pathology that was not visible in the image/video clips provided.

Thank you for this referral. If the clinical or image interpretation does not parallel your findings or if I can be of any further assistance please contact me.

Remo Lobetti, BVSc, MMedVet (Med), PhD, Dipl. ECVIM (Internal Medicine)

[info@sonopath.com](mailto:info@sonopath.com)