



## PATIENT

Anya Matz

## SPECIES

Canine

## BREED

Mix

## SEX

Spayed female

## AGE

9 ½ years

## WEIGHT

53 lbs

## INTERPRETED BY

Remo Lobetti, BVSc,  
MMedVet (Med),  
PhD, Dipl. ECVIM

## IMAGING PERFORMED BY

Dr. Arms

## HOSPITAL NAME

Gilbertsville VH

## REFERRING VET

Dr. Arms

## INVOICE

74374

## DATE

4/9/26

## PRESENTING CLINICAL SIGNS

History: Progressive increased LES  
Started medical management for torn CCL, started rimadyl. Hx mild increased ALT.  
after rimadyl x 2 weeks - ALT 285, ALKP 299 - stopped rimadyl  
presented for ACL sx 4/7 but ALT 813, ALKP 467 - postponed surgery for AUS  
Abnormal PE/Chem/CBC/UA Results: 2019 ALT 47, 2021 ALT 63, 2022 ALT 240, 2023 ALT 159,  
3/2026 after starting rimadyl ALT 285, ALKP 299. Off rimadyl presx 4/7/26 ALT 813, ALKP 467.

## ULTRASONOGRAPHIC EXAMINATION OF THE ABDOMEN

### *Urinary System*

The urinary bladder is full with a normal thickness and smooth appearance of the wall. Normal anechoic urine with no sediment or uroliths evident.

Normal appearance of the trigone area, proximal urethra, and iliac blood vessels.

Normal appearance and size of the iliac lymph nodes. Ureters not visualized, which can be considered a normal finding.

Normal renal size (left measured 5.9 cm, right measured 6.3 cm), architecture, echogenic appearance, cortico-medullary differentiation, which maintains a 1:3 cortex to medulla ratio, pelvis, and capsule. No infarcts, mineralization or renoliths evident. Normal color flow pattern is evident in both kidneys.

### *Adrenal Glands*

The left adrenal gland is normal in shape, echogenic appearance, size, position, and appearance of the visible peri-adrenal vasculature. Left adrenal gland measured 0.62 cm in width. The right adrenal gland was enlarged measuring 1.4 cm in width with a rounded shape, but maintained a normal echogenic appearance, position and appearance of the visible peri-adrenal vasculature.

### *Spleen*

The spleen was not visualized.

### *Liver*

Normal size with a diffuse, increased echogenic and coarse appearance, normal portal markings, and regular curvilinear capsule. No nodules or masses evident. Normal appearance of the hepatic and portal vasculature.



## PATIENT

Anya Matz

## SPECIES

Canine

## BREED

Mix

## SEX

Spayed female

## AGE

9 ½ years

## WEIGHT

53 lbs

## INTERPRETED BY

Remo Lobetti, BVSc,  
MMedVet (Med),  
PhD, Dipl. ECVIM

## IMAGING PERFORMED BY

Dr. Arms

## HOSPITAL NAME

Gilbertsville VH

## REFERRING VET

Dr. Arms

## INVOICE

74374

## DATE

4/9/26

## ***Gallbladder***

The gallbladder is full containing a scant amount of non-adhered hyperechogenic sediment. Normal thickness and echogenic appearance of the wall. Normal size and appearance of the cystic and common bile duct.

## ***Gastrointestinal***

Normal appearance of the stomach, duodenum, small intestine, ileo-cecal junction, and colon with no loss of layering, 1:3 muscularis to mucosa ratio, normal wall thickness and peristaltic activity, and no distension of the lumen.

## ***Pancreas***

The visible sections of the pancreas are of normal size and echogenic appearance with a regular capsule. Normal echogenic appearance of the mesentery and fat surrounding the pancreas.

## ***Free Abdomen***

Normal mesenteric lymph nodes.

No ascites evident.

## **ULTRASONOGRAPHIC FINDINGS**

- Hepatopathy.
- Right adrenomegaly.

## **INTERPRETATION OF THE FINDINGS & FURTHER RECOMMENDATIONS**

Etiologies for the hepatopathy would be reactive hyperplasia, vacuolar and metabolic with hepatitis and infiltrative neoplasia an unlikely differential diagnosis.

Etiologies for the right adrenomegaly would be age related reactive hyperplasia, disease, stress and possibly emerging pituitary dependent Cushing's disease.

Further assessment would be urine specific gravity and urine cortisol to creatinine ratio and if abnormal then adrenal function testing (ACTH stimulation/LDDST) would then be indicated.

If Cushing's disease has been excluded then further assessment of the hepatopathy would be FNA cytology. However, tru cut or wedge biopsy may be required for a final etiological diagnosis.

Specific therapy would be dependent on an etiological diagnosis.

Symptomatic management that can be considered for the hepatopathy would be use of Ursodiol with regular monitoring of liver enzyme activity.



## PATIENT

Anya Matz

## SPECIES

Canine

## BREED

Mix

## SEX

Spayed female

## AGE

9 ½ years

## WEIGHT

53 lbs

## INTERPRETED BY

Remo Lobetti, BVSc,  
MMedVet (Med),  
PhD, Dipl. ECVIM

## IMAGING PERFORMED BY

Dr. Arms

## HOSPITAL NAME

Gilbertsville VH

## REFERRING VET

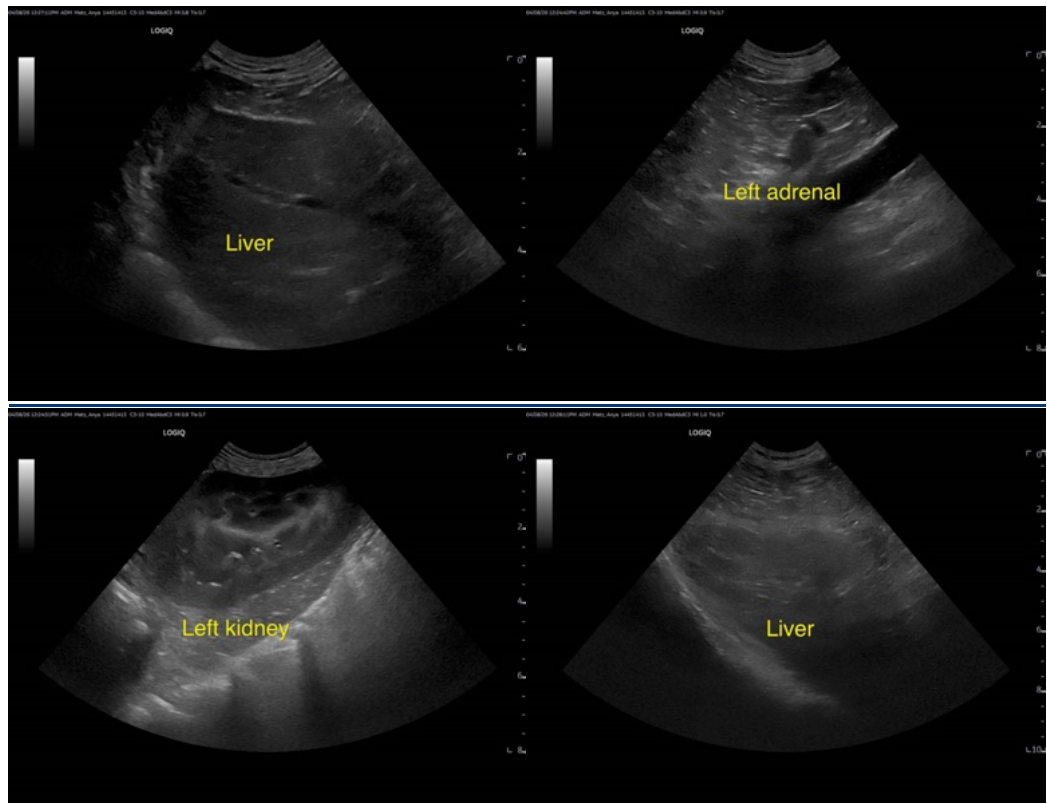
Dr. Arms

## INVOICE

74374

## DATE

4/9/26





## PATIENT

Anya Matz

## SPECIES

Canine

## BREED

Mix

## SEX

Spayed female

## AGE

9 ½ years

## WEIGHT

53 lbs

## INTERPRETED BY

Remo Lobetti, BVSc,  
MMedVet (Med),  
PhD, Dipl. ECVIM

## IMAGING PERFORMED BY

Dr. Arms

## HOSPITAL NAME

Gilbertsville VH

## REFERRING VET

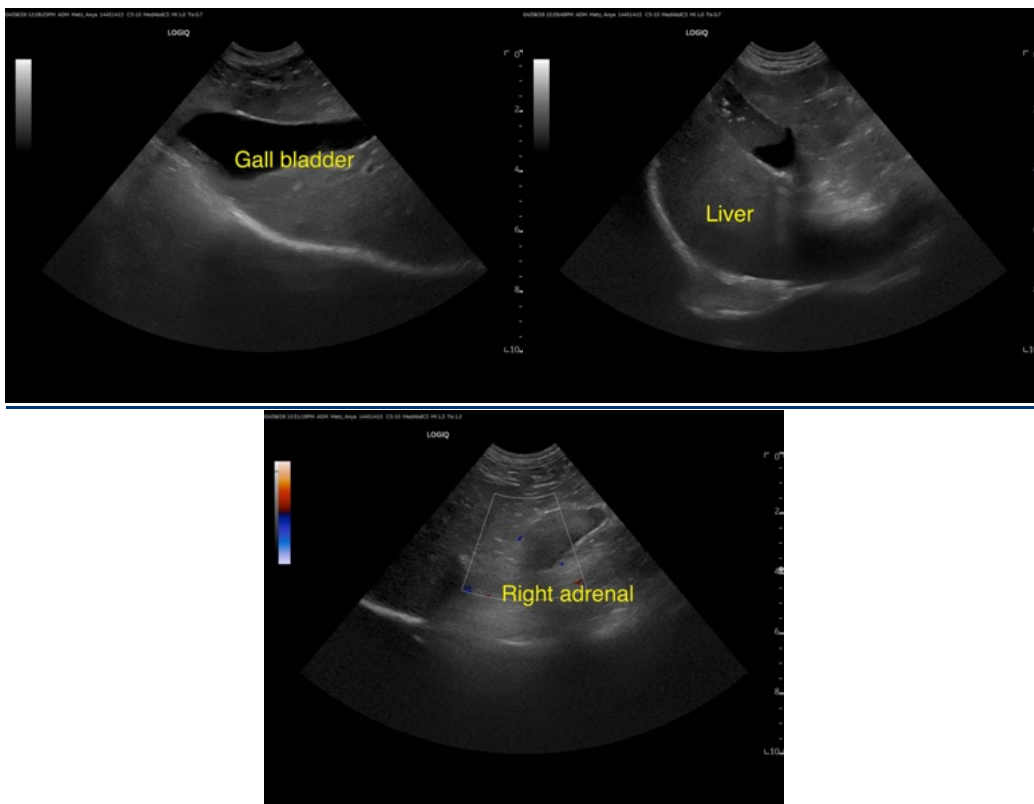
Dr. Arms

## INVOICE

74374

## DATE

4/9/26



The information and recommendations provided are based on the images presented by the referring veterinarian/sonographer. No evaluation can be communicated regarding pathology that was not visible in the image/video clips provided.

Thank you for this referral. If the clinical or image interpretation does not parallel your findings or if I can be of any further assistance please contact me.

Remo Lobetti, BVSc, MMedVet (Med), PhD, Dipl. ECVIM (Internal Medicine)

[info@sonopath.com](mailto:info@sonopath.com)