



PATIENT

Hoover White

SPECIES

Canine

BREED

Beagle Mix

SEX

Neutered male

AGE

10 years

WEIGHT

88 lbs

INTERPRETED BY

Remo Lobetti, BVSc,
MMedVet (Med),
PhD, Dipl. ECVIM

IMAGING PERFORMED BY

Dr. Ashley Whitesell

HOSPITAL NAME

Dickson AC

REFERRING VET

Dr. Hovis

INVOICE

74174

DATE

4/7/26

PRESENTING CLINICAL SIGNS

- Pt presented on 3/16/26 for mouth bleeding after chewing on bones. Bloodwork showed low platelets. Prednisone and Doxycycline started on 3/20/26. Recheck bloodwork on 3/28/26 showed normal platelet number normal. O wanted ultrasound to ensure no coagulation concerns or liver concerns.
- Bloodwork 3/16/26: Platelet count (22) ALKP (434) Bloodwork on 3/28/26: Platelets WNL WBC's increased (29.7) Neutrophils increased (85) & Bands increased (4) ALT increased (150) ALKP increased (2278) PSL increased (625) USG (1.009)

ULTRASONOGRAPHIC EXAMINATION OF THE ABDOMEN

Urinary System

The urinary bladder is full with a normal thickness and smooth appearance of the wall. Normal anechoic urine with no sediment or uroliths evident.

Normal appearance of the trigone area, proximal urethra, and iliac blood vessels.

Normal appearance and size of the iliac lymph nodes. Ureters not visualized, which can be considered a normal finding.

Normal renal size (left measured 8.7 cm, right measured 9.0 cm), architecture, echogenic appearance, cortico-medullary differentiation, which maintains a 1:3 cortex to medulla ratio, pelvis, and capsule. No infarcts, mineralization or renoliths evident. Normal color flow pattern is evident in both kidneys.

The prostate is small and hypoechogenic measuring 1.2 cm in width.

Adrenal Glands

The adrenal glands were not clearly visualized, but appears to be of normal shape, echogenic appearance and size.

Spleen

Normal size and echogenic appearance. Smooth homogenous parenchyma and regular curvilinear capsule. Normal volume of the splenic vasculature without any overt congestion or thrombosis evident. No inflammatory, neoplastic, infarction, or infiltrative changes evident. The spleen measured 2.8 cm in width.

Liver

Normal size, echogenic appearance, portal markings, and regular curvilinear capsule. No nodules or masses evident. Normal appearance of the hepatic and portal vasculature.



PATIENT

Hoover White

SPECIES

Canine

BREED

Beagle Mix

SEX

Neutered male

AGE

10 years

WEIGHT

88 lbs

INTERPRETED BY

Remo Lobetti, BVSc,
MMedVet (Med),
PhD, Dipl. ECVIM

IMAGING PERFORMED BY

Dr. Ashley Whitesell

HOSPITAL NAME

Dickson AC

REFERRING VET

Dr. Hovis

INVOICE

74174

DATE

4/7/26

Gallbladder

The gallbladder is small containing normal anechoic bile. Normal thickness and echogenic appearance of the wall. Normal size and appearance of the cystic and common bile duct.

Gastrointestinal

Normal appearance of the stomach, duodenum, small intestine, ileo-cecal junction, and colon with no loss of layering, 1:3 muscularis to mucosa ratio, normal wall thickness and peristaltic activity, and no distension of the lumen. A small amount of chyme was present in the proximal duodenum compatible with a recent meal.

Pancreas

The visible sections of the pancreas are of normal size and echogenic appearance with a regular capsule. Normal echogenic appearance of the mesentery and fat surrounding the pancreas.

Free Abdomen

Normal mesenteric lymph nodes.

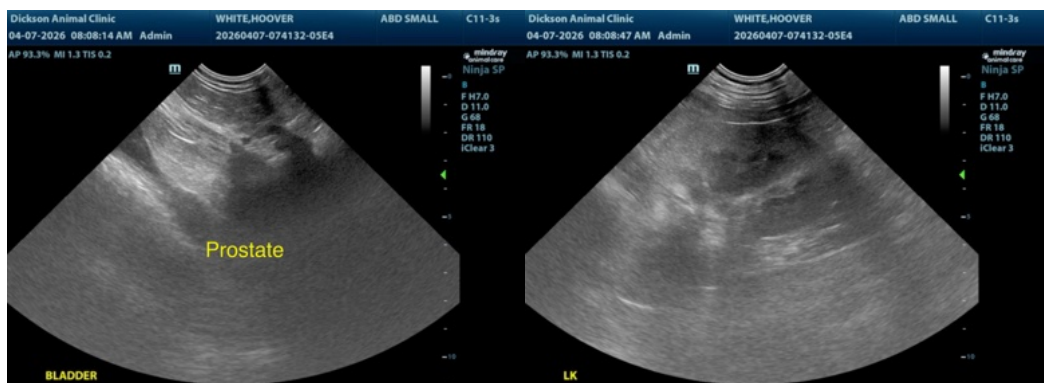
No ascites evident.

ULTRASONOGRAPHIC FINDINGS

- Normal ultrasound examination of the abdomen.

INTERPRETATION OF THE FINDINGS & FURTHER RECOMMENDATIONS

The elevated liver enzyme activity, PCL, and isosthenuria can all be ascribed to the recent prednisolone therapy.





PATIENT

Hoover White

SPECIES

Canine

BREED

Beagle Mix

SEX

Neutered male

AGE

10 years

WEIGHT

88 lbs

INTERPRETED BY

Remo Lobetti, BVSc,
MMedVet (Med),
PhD, Dipl. ECVIM

**IMAGING
PERFORMED BY**

Dr. Ashley Whitesell

HOSPITAL NAME

Dickson AC

REFERRING VET

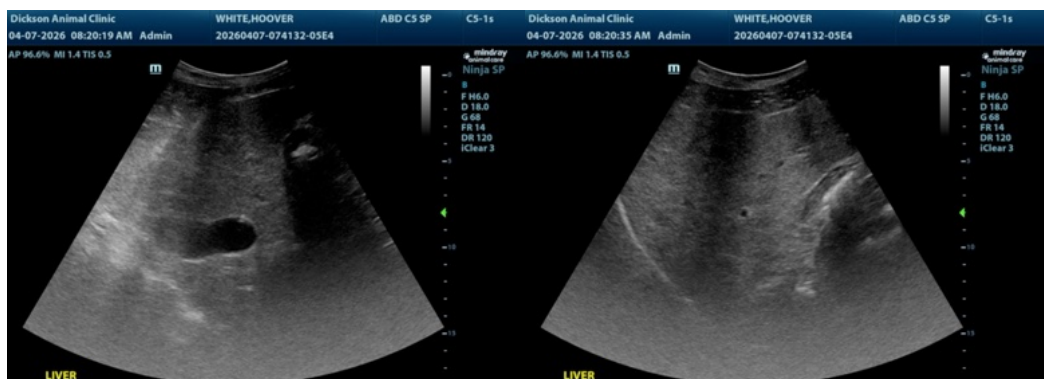
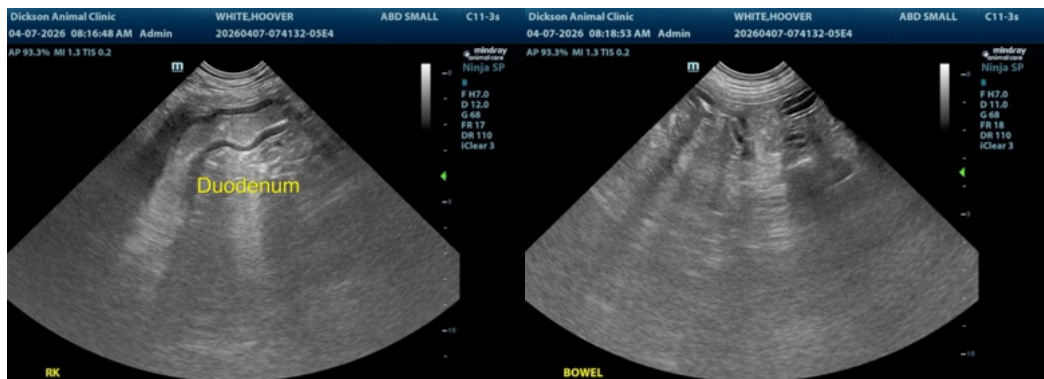
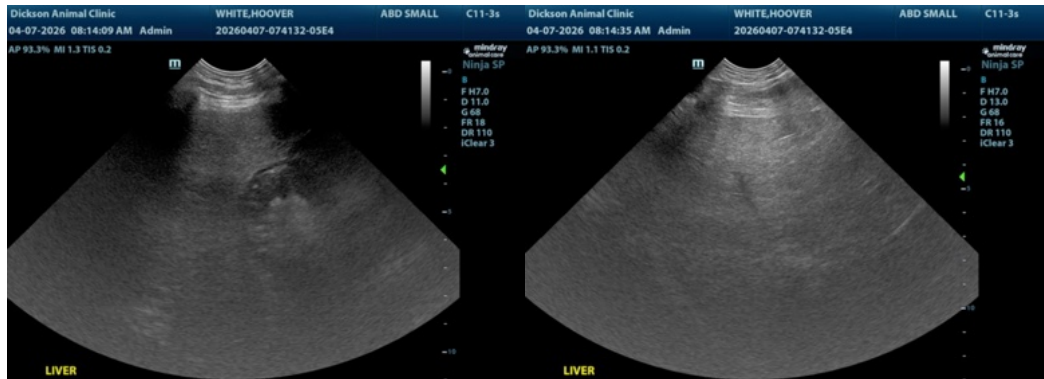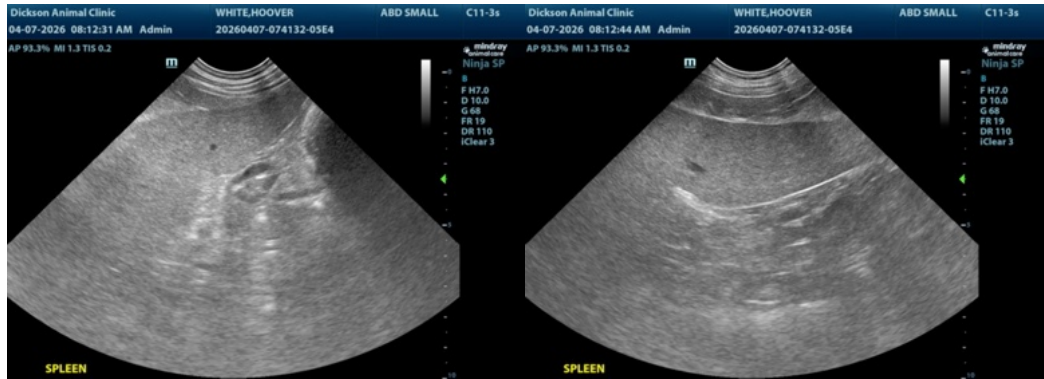
Dr. Hovis

INVOICE

74174

DATE

4/7/26





PATIENT

Hoover White

SPECIES

Canine

BREED

Beagle Mix

SEX

Neutered male

AGE

10 years

WEIGHT

88 lbs

INTERPRETED BY

Remo Lobetti, BVSc,
MMedVet (Med),
PhD, Dipl. ECVIM

IMAGING PERFORMED BY

Dr. Ashley Whitesell

HOSPITAL NAME

Dickson AC

REFERRING VET

Dr. Hovis

INVOICE

74174

DATE

4/7/26

The information and recommendations provided are based on the images presented by the referring veterinarian/sonographer. No evaluation can be communicated regarding pathology that was not visible in the image/video clips provided.

Thank you for this referral. If the clinical or image interpretation does not parallel your findings or if I can be of any further assistance please contact me.

Remo Lobetti, BVSc, MMedVet (Med), PhD, Dipl. ECVIM (Internal Medicine)

info@sonopath.com