



PATIENT

Baldwin Cronin

SPECIES

Feline

BREED

Domestic Shorthair

SEX

Neutered male

AGE

14 years

WEIGHT

9.8 lbs

INTERPRETED BY

Remo Lobetti, BVSc,
MMedVet (Med),
PhD, Dipl. ECVIM

IMAGING PERFORMED BY

Dr. Cronin

HOSPITAL NAME

Ark AH

REFERRING VET

Dr. Cronin

INVOICE

74220

DATE

4/6/26

PRESENTING CLINICAL SIGNS

- Weight loss since October, has lost over 1# since February
- Has been PU/PD for the past few months
- Recent episode of inappropriate urination
- CBC/chem/T4/UA pending from today 2/12/26 - SDMA 19, ALT 197, AST 80, CK 490, USG 1.017

ULTRASONOGRAPHIC EXAMINATION OF THE ABDOMEN

Urinary System

The urinary bladder is full with a normal thickness and smooth appearance of the wall. A moderate amount of floating, hyperechogenic sediment.

Normal appearance of the trigone area, proximal urethra, and iliac blood vessels.

Normal appearance and size of the iliac lymph nodes. Ureters not visualized, which can be considered a normal finding.

Normal renal size (left measured 3.5 cm, right measured 3.6 cm), architecture, echogenic appearance, cortico-medullary differentiation, which maintains a 1:3 cortex to medulla ratio, pelvis, and capsule. No infarcts, mineralization or renoliths evident.

Adrenal Glands

Normal shape, echogenic appearance, size, position, and appearance of the visible peri-adrenal vasculature. Left adrenal gland measured 0.35 cm in width. The right adrenal gland measured 0.32 cm in width.

Spleen

Normal size and echogenic appearance. Smooth homogenous parenchyma and regular curvilinear capsule. Normal volume of the splenic vasculature without any overt congestion or thrombosis evident. No inflammatory, neoplastic, infarction, or infiltrative changes evident. The spleen measured 0.8 cm in width.

Liver

Normal size, echogenic appearance, portal markings, and regular curvilinear capsule. No nodules or masses evident. Normal appearance of the hepatic and portal vasculature.



PATIENT

Baldwin Cronin

SPECIES

Feline

BREED

Domestic Shorthair

SEX

Neutered male

AGE

14 years

WEIGHT

9.8 lbs

INTERPRETED BY

Remo Lobetti, BVSc,
MMedVet (Med),
PhD, Dipl. ECVIM

IMAGING PERFORMED BY

Dr. Cronin

HOSPITAL NAME

Ark AH

REFERRING VET

Dr. Cronin

INVOICE

74220

DATE

4/6/26

Gallbladder

The gallbladder is small containing normal anechoic bile. Normal thickness and echogenic appearance of the wall. Normal size and appearance of the cystic and common bile duct.

Gastrointestinal

Normal appearance of the stomach, duodenum, ileo-cecal junction, and colon with no loss of layering, 1:3 muscularis to mucosa ratio, normal wall thickness and peristaltic activity, and no distension of the lumen. Normal thickness of the small intestine up to 0.3 cm with no loss of layering, but with an increase in the muscularis to mucosa ratio, normal peristaltic activity and no distension of the lumen.

Pancreas

The visible sections of the pancreas are of normal size and echogenic appearance with a regular capsule. Normal echogenic appearance of the mesentery and fat surrounding the pancreas.

Free Abdomen

Normal mesenteric lymph nodes.

No ascites evident.

ULTRASONOGRAPHIC FINDINGS

- Enteropathy.
- Urinary bladder sediment.

INTERPRETATION OF THE FINDINGS & FURTHER RECOMMENDATIONS

Etiologies for the enteropathy would be parasitic enteritis, dietary hypersensitivity and inflammatory bowel disease with emerging lymphoma a possible differential diagnosis.

The likely etiologies for the urinary bladder sediment would be incidental debris, crystalluria with bacterial cystitis a less likely differential diagnosis.

Further assessment would be urine and fecal analysis, possible urine culture, cobalamin and folate assay and endoscopy of the upper GI tract with biopsies.

Specific therapy would be dependent on an etiological diagnosis.

Symptomatic management that could be considered would be feeding a novel protein/hypoallergenic diet, course of Fenbendazole, cobalamin supplementation and if there is still not a satisfactory improvement then a course of Prednisolone would then be indicated.



PATIENT

Baldwin Cronin

SPECIES

Feline

BREED

Domestic Shorthair

SEX

Neutered male

AGE

14 years

WEIGHT

9.8 lbs

INTERPRETED BY

Remo Lobetti, BVSc,
MMedVet (Med),
PhD, Dipl. ECVIM

IMAGING PERFORMED BY

Dr. Cronin

HOSPITAL NAME

Ark AH

REFERRING VET

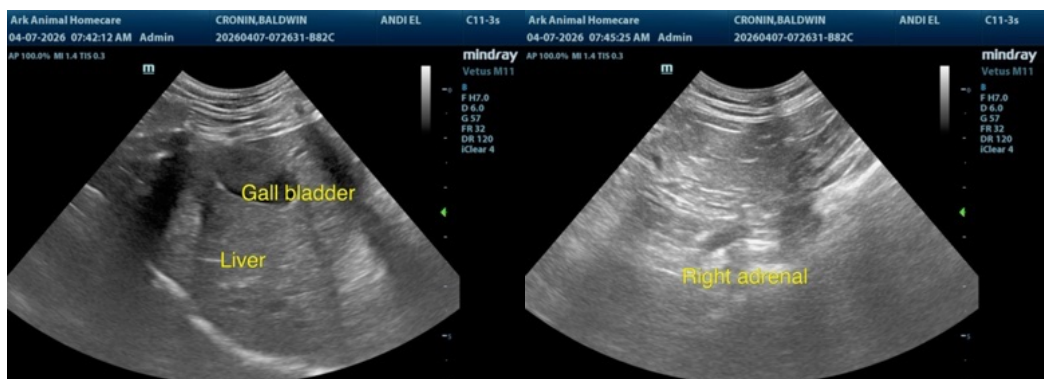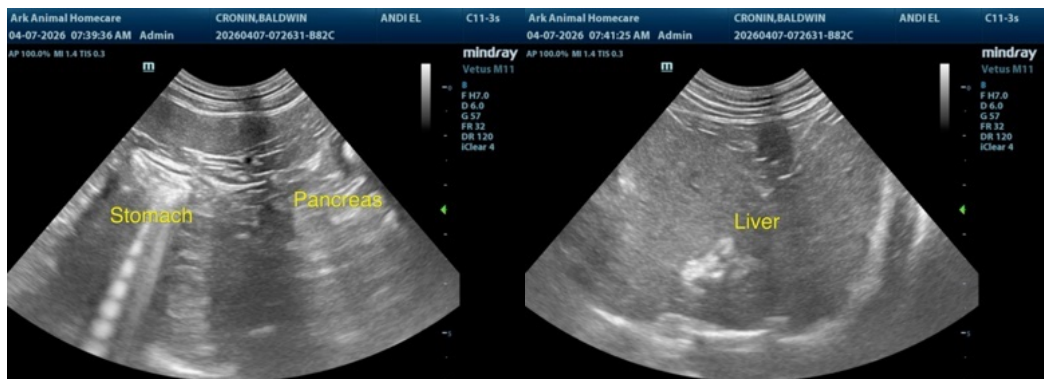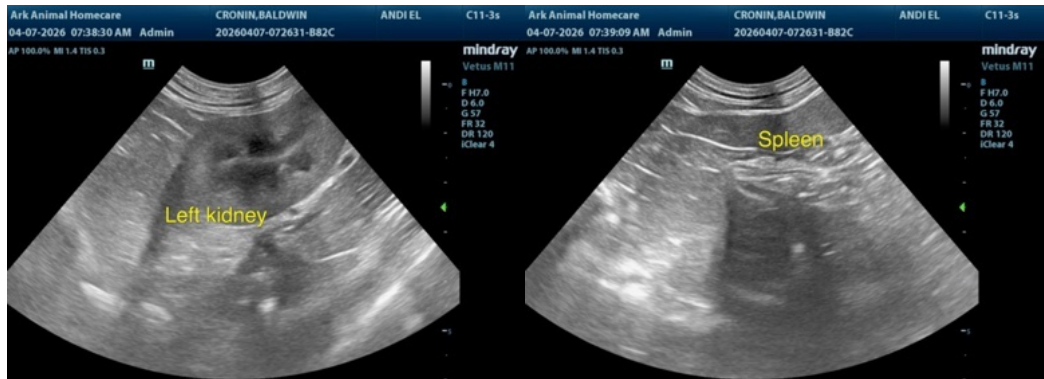
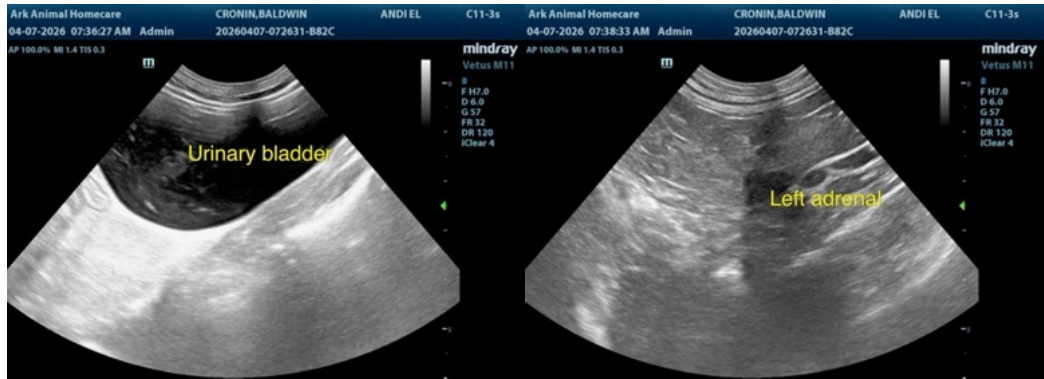
Dr. Cronin

INVOICE

74220

DATE

4/6/26





PATIENT

Baldwin Cronin

SPECIES

Feline

BREED

Domestic Shorthair

SEX

Neutered male

AGE

14 years

WEIGHT

9.8 lbs

INTERPRETED BY

Remo Lobetti, BVSc,
MMedVet (Med),
PhD, Dipl. ECVIM

IMAGING PERFORMED BY

Dr. Cronin

HOSPITAL NAME

Ark AH

REFERRING VET

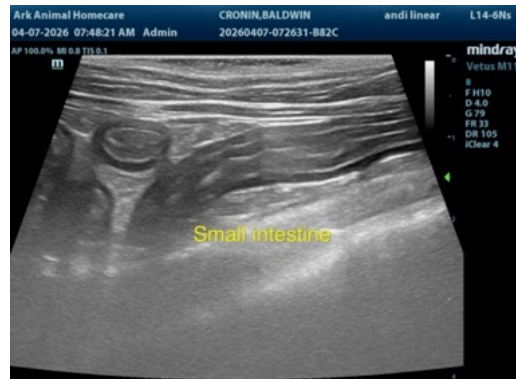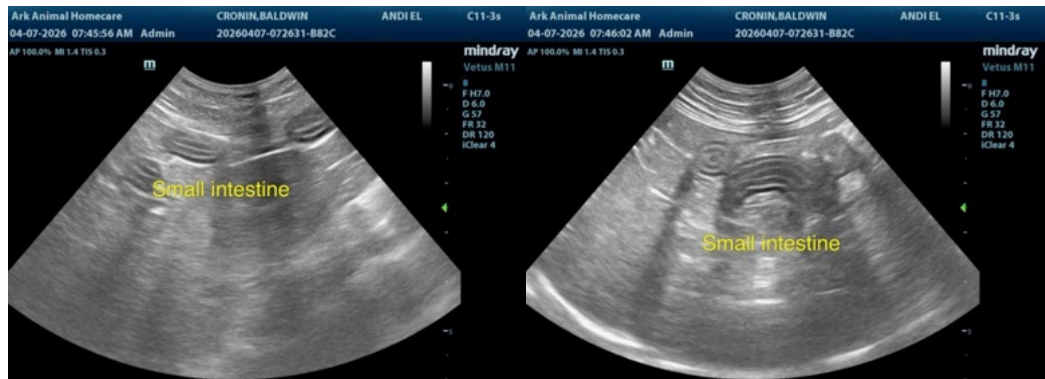
Dr. Cronin

INVOICE

74220

DATE

4/6/26



The information and recommendations provided are based on the images presented by the referring veterinarian/sonographer. No evaluation can be communicated regarding pathology that was not visible in the image/video clips provided.

Thank you for this referral. If the clinical or image interpretation does not parallel your findings or if I can be of any further assistance please contact me.

Remo Lobetti, BVSc, MMedVet (Med), PhD, Dipl. ECVIM (Internal Medicine)

info@sonopath.com