



PATIENT

Roxy Beatrice

SPECIES

Canine

BREED

Terrier Mix

SEX

Spayed female

AGE

14 years

WEIGHT

11 lbs

INTERPRETED BY

Remo Lobetti, BVSc,
MMedVet (Med),
PhD, Dipl. ECVIM

IMAGING PERFORMED BY

Nikki Kollman, RVT

HOSPITAL NAME

Airpark AH

REFERRING VET

Dr. Marciszewski

INVOICE

74177

DATE

4/6/26

PRESENTING CLINICAL SIGNS

Chronic intermittent upper GI signs; hx of pancreatitis
Presented in March 2026 for inappropriate urination
Treated empirically with Cefpodoxime
Creatinine 1.6 BUN 47 Calcium 12.1 Ionized calcium pending..... ALT 233 ALP 312 Cholesterol 399
Lipase 466 USG 1.014 RBC >50/HPF TT4, FT4: WNL 4DX: NEG

ULTRASONOGRAPHIC EXAMINATION OF THE ABDOMEN

Urinary System

The urinary bladder is full with a normal thickness and smooth appearance of the wall. Normal anechoic urine with no sediment or uroliths evident.

Normal appearance of the trigone area, proximal urethra, and iliac blood vessels.

Normal appearance and size of the iliac lymph nodes. Ureters not visualized, which can be considered a normal finding.

Normal renal size (left measured 3.4 cm, right measured 3.1 cm), architecture, echogenic appearance, cortico-medullary differentiation, which maintains a 1:3 cortex to medulla ratio, pelvis, and capsule. No infarcts, mineralization or renoliths evident.

Adrenal Glands

Normal shape, echogenic appearance, size, position, and appearance of the visible peri-adrenal vasculature. Left adrenal gland measured 0.42 cm and 0.38 cm in width. The right adrenal gland measured 0.53 cm in width.

Spleen

Normal size and echogenic appearance. Smooth homogenous parenchyma and regular curvilinear capsule. Incidental myelolipomas are present. Normal volume of the splenic vasculature without any overt congestion or thrombosis evident. No inflammatory, neoplastic, infarction, or infiltrative changes evident. The spleen measured 1.0 cm in width.

Liver

Normal size, echogenic appearance, portal markings, and regular curvilinear capsule. No nodules or masses evident. Normal appearance of the hepatic and portal vasculature.



PATIENT

Roxy Beatrice

SPECIES

Canine

BREED

Terrier Mix

SEX

Spayed female

AGE

14 years

WEIGHT

11 lbs

INTERPRETED BY

Remo Lobetti, BVSc,
MMedVet (Med),
PhD, Dipl. ECVIM

IMAGING PERFORMED BY

Nikki Kollman, RVT

HOSPITAL NAME

Airpark AH

REFERRING VET

Dr. Marciszewski

INVOICE

74177

DATE

4/6/26

Gallbladder

The gallbladder is full containing a scant amount of adhered, hyperechogenic sediment. Normal thickness and echogenic appearance of the wall. Normal size and appearance of the cystic and common bile duct.

Gastrointestinal

Normal appearance of the stomach, duodenum, small intestine, ileo-cecal junction, and colon with no loss of layering, 1:3 muscularis to mucosa ratio, normal wall thickness and peristaltic activity, and no distension of the lumen.

Pancreas

The visible sections of the pancreas are of normal size and echogenic appearance with a regular capsule. Normal echogenic appearance of the mesentery and fat surrounding the pancreas.

Free Abdomen

Normal mesenteric lymph nodes.

No ascites evident.

ULTRASONOGRAPHIC FINDINGS

- Normal ultrasound examination of the abdomen.

INTERPRETATION OF THE FINDINGS & FURTHER RECOMMENDATIONS

On this ultrasound there is no obvious etiology for the hematuria, possible hypercalcemia and elevated liver enzyme activity.

Although the kidneys appear ultrasonographically normal this does not exclude early chronic kidney disease as per the patient's azotemia and low urine specific gravity.



PATIENT

Roxy Beatrice

SPECIES

Canine

BREED

Terrier Mix

SEX

Spayed female

AGE

14 years

WEIGHT

11 lbs

INTERPRETED BY

Remo Lobetti, BVSc,
MMedVet (Med),
PhD, Dipl. ECVIM

**IMAGING
PERFORMED BY**

Nikki Kollman, RVT

HOSPITAL NAME

Airpark AH

REFERRING VET

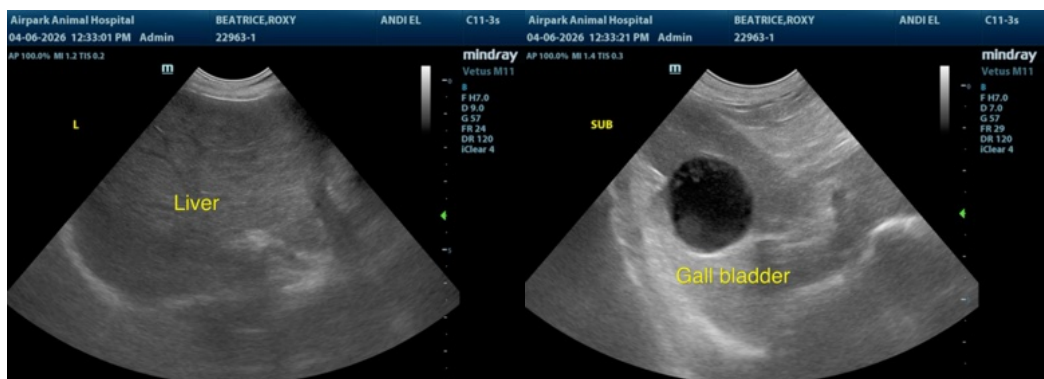
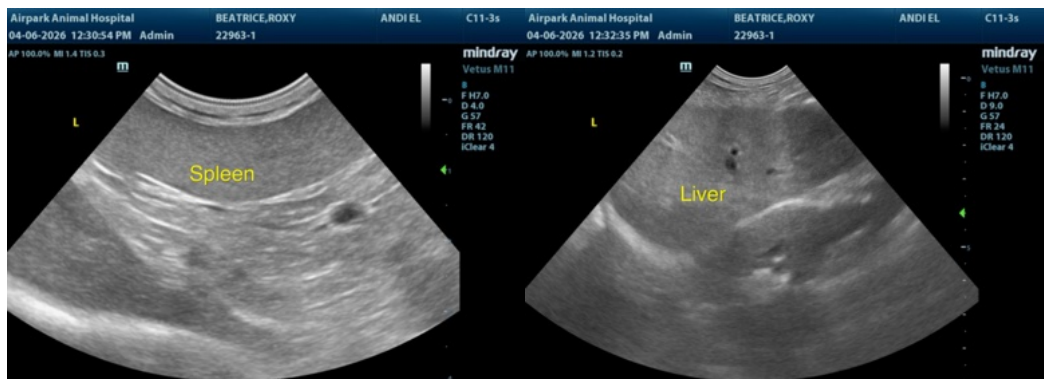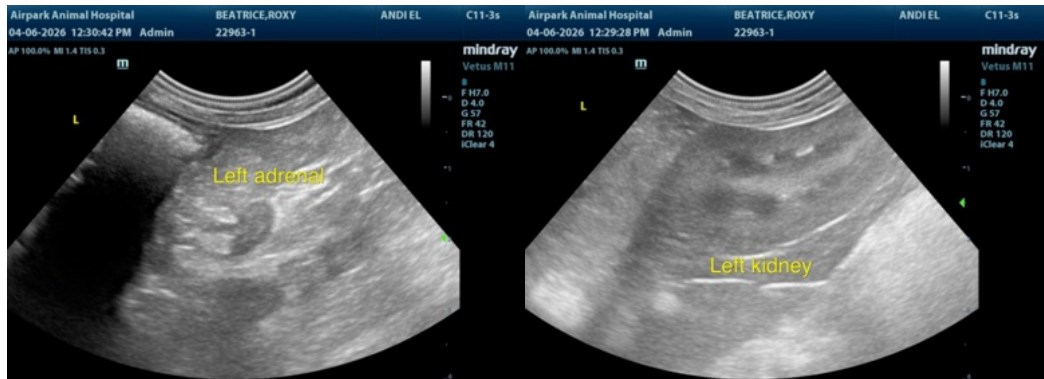
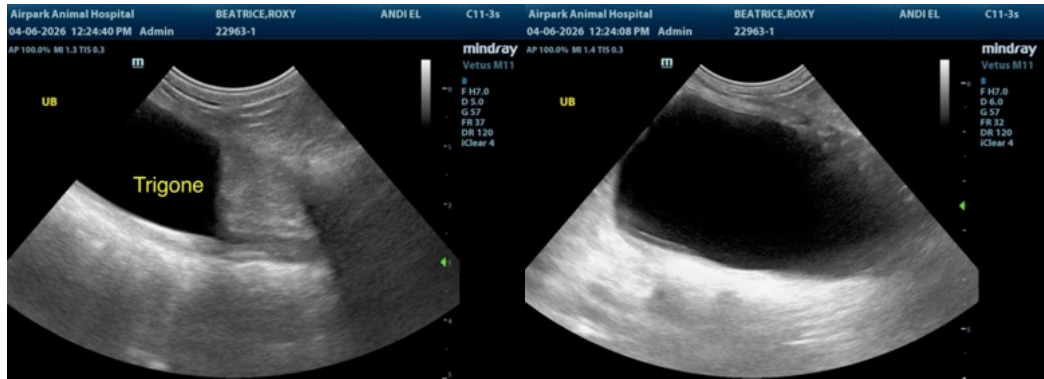
Dr. Marciszewski

INVOICE

74177

DATE

4/6/26





PATIENT

Roxy Beatrice

SPECIES

Canine

BREED

Terrier Mix

SEX

Spayed female

AGE

14 years

WEIGHT

11 lbs

INTERPRETED BY

Remo Lobetti, BVSc,
MMedVet (Med),
PhD, Dipl. ECVIM

IMAGING PERFORMED BY

Nikki Kollman, RVT

HOSPITAL NAME

Airpark AH

REFERRING VET

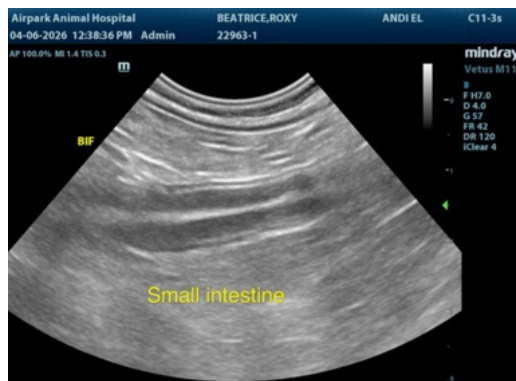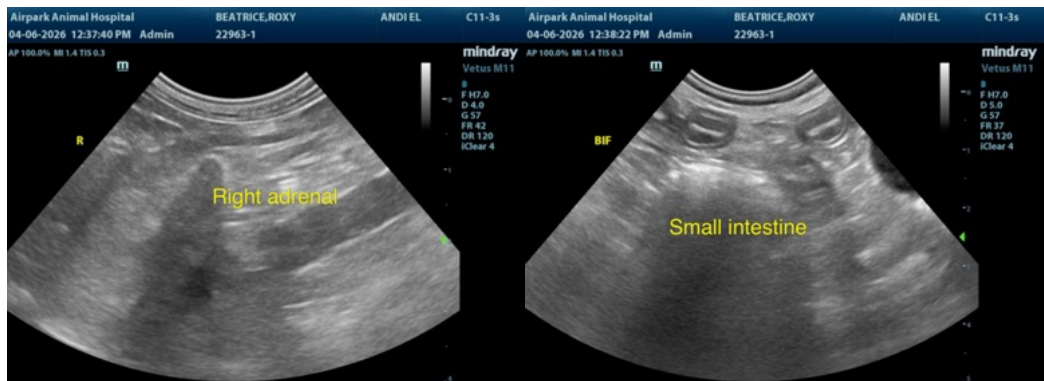
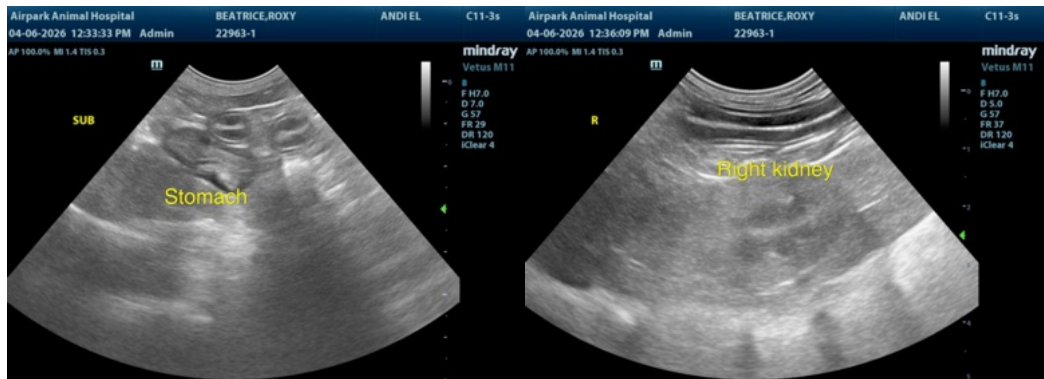
Dr. Marciszewski

INVOICE

74177

DATE

4/6/26



The information and recommendations provided are based on the images presented by the referring veterinarian/sonographer. No evaluation can be communicated regarding pathology that was not visible in the image/video clips provided.

Thank you for this referral. If the clinical or image interpretation does not parallel your findings or if I can be of any further assistance please contact me.

Remo Lobetti, BVSc, MMedVet (Med), PhD, Dipl. ECVIM (Internal Medicine)

info@sonopath.com