



PATIENT

Kenzo Eichelberger

SPECIES

Canine

BREED

Boxer

SEX

Neutered male

AGE

4 years

WEIGHT

72 lbs

INTERPRETED BY

Remo Lobetti, BVSc,
MMedVet (Med),
PhD, Dipl. ECVIM

IMAGING PERFORMED BY

Dr. Tiffany Brady

HOSPITAL NAME

Shiloh VH

REFERRING VET

Dr. Onstott

INVOICE

74132

DATE

4/3/26

PRESENTING CLINICAL SIGNS

- High Grade MCT removed from end of pinna per histopath
- Normal thoracic rads and bloodwork
- Abdominal ultrasound performed as part of staging to assess for metastasis

ULTRASONOGRAPHIC EXAMINATION OF THE ABDOMEN

Urinary System

The urinary bladder is small with a normal thickness and smooth appearance of the wall. Normal anechoic urine with no sediment or uroliths evident.

Normal appearance of the trigone area, proximal urethra, and iliac blood vessels.

Normal appearance and size of the iliac lymph nodes. Ureters not visualized, which can be considered a normal finding.

Normal renal size (left measured 6.4 cm), architecture, echogenic appearance, cortico-medullary differentiation, which maintains a 1:3 cortex to medulla ratio, pelvis, and capsule. No infarcts, mineralization or renoliths evident.

The right kidney is poorly visualized, but appears to be of normal shape, echogenic appearance and size.

The prostate is small and hypoechogenic.

Adrenal Glands

The left adrenal gland was not clearly visualized, but appears to be of normal shape, echogenic appearance and size. The right adrenal gland was not visualized.

Spleen

Normal size and echogenic appearance. Smooth homogenous parenchyma and regular curvilinear capsule. Normal volume of the splenic vasculature without any overt congestion or thrombosis evident. No inflammatory, neoplastic, infarction, or infiltrative changes evident. The spleen measured 2.8 cm in width.

Liver

Normal size, echogenic appearance, portal markings, and regular curvilinear capsule. No nodules or masses evident. Normal appearance of the hepatic and portal vasculature.



PATIENT

Kenzo Eichelberger

SPECIES

Canine

BREED

Boxer

SEX

Neutered male

AGE

4 years

WEIGHT

72 lbs

INTERPRETED BY

Remo Lobetti, BVSc,
MMedVet (Med),
PhD, Dipl. ECVIM

IMAGING PERFORMED BY

Dr. Tiffany Brady

HOSPITAL NAME

Shiloh VH

REFERRING VET

Dr. Onstott

INVOICE

74132

DATE

4/3/26

Gallbladder

The gallbladder is full containing normal anechoic bile. Normal thickness and echogenic appearance of the wall. Normal size and appearance of the cystic and common bile duct.

Gastrointestinal

Normal appearance of the stomach, duodenum, small intestine, ileo-cecal junction, and colon with no loss of layering, 1:3 muscularis to mucosa ratio, normal wall thickness and peristaltic activity, and no distension of the lumen.

Pancreas

The visible sections of the pancreas are of normal size and echogenic appearance with a regular capsule. Normal echogenic appearance of the mesentery and fat surrounding the pancreas.

Free Abdomen

Normal mesenteric lymph nodes.

No ascites evident.

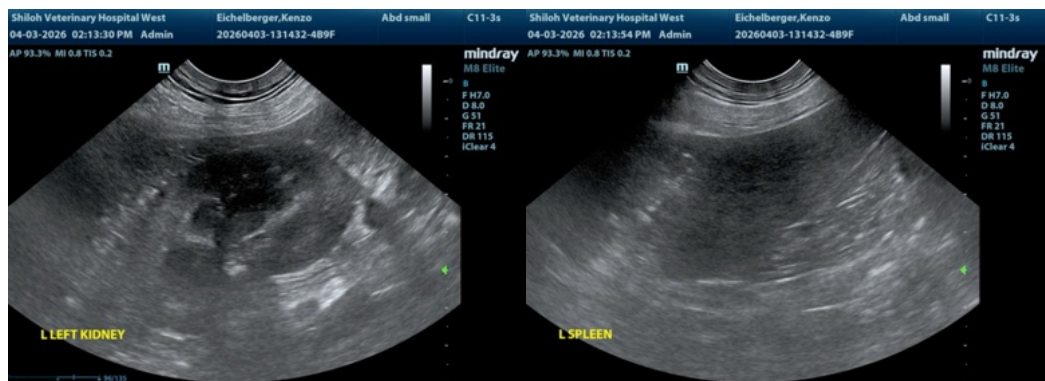
ULTRASONOGRAPHIC FINDINGS

- Normal ultrasound examination of the abdomen.

INTERPRETATION OF THE FINDINGS & FURTHER RECOMMENDATIONS

On this ultrasound there is no obvious evidence of metastatic mast cell neoplasia.

Further assessment that could be considered to complete the metastatic screen would be FNA cytology of the liver and spleen.





PATIENT

Kenzo Eichelberger

SPECIES

Canine

BREED

Boxer

SEX

Neutered male

AGE

4 years

WEIGHT

72 lbs

INTERPRETED BY

Remo Lobetti, BVSc,
MMedVet (Med),
PhD, Dipl. ECVIM

IMAGING PERFORMED BY

Dr. Tiffany Brady

HOSPITAL NAME

Shiloh VH

REFERRING VET

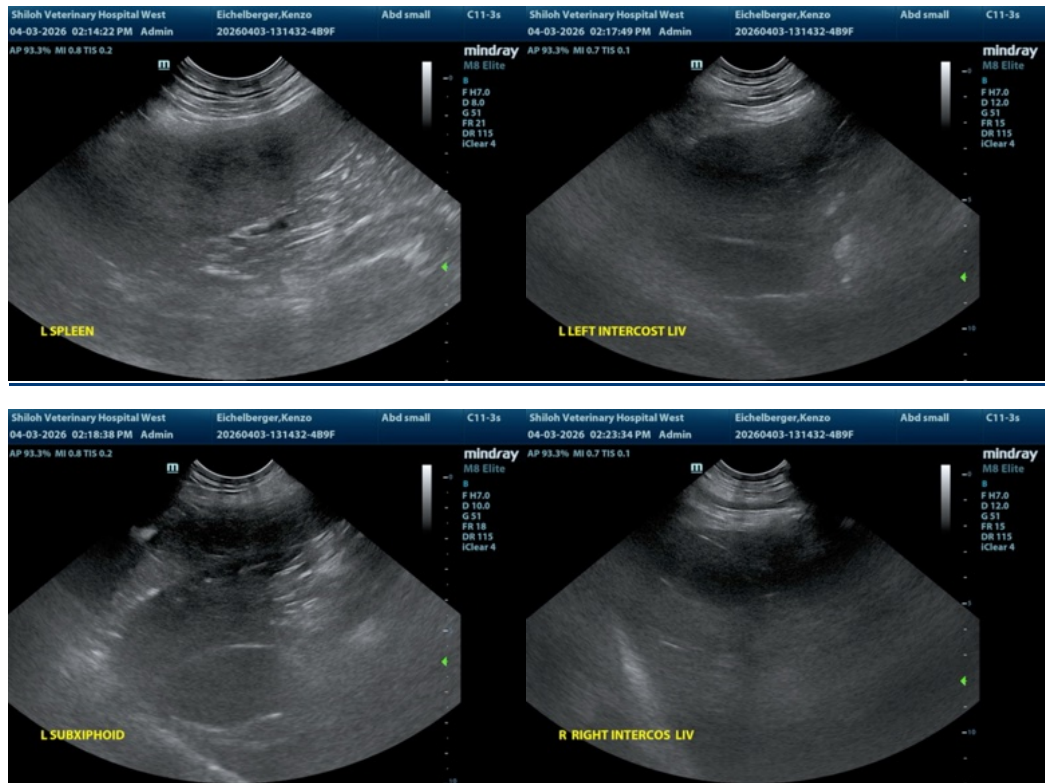
Dr. Onstott

INVOICE

74132

DATE

4/3/26



The information and recommendations provided are based on the images presented by the referring veterinarian/sonographer. No evaluation can be communicated regarding pathology that was not visible in the image/video clips provided.

Thank you for this referral. If the clinical or image interpretation does not parallel your findings or if I can be of any further assistance please contact me.

Remo Lobetti, BVSc, MMedVet (Med), PhD, Dipl. ECVIM (Internal Medicine)

info@sonopath.com