



## PATIENT

Jameson Lynoff

## SPECIES

Canine

## BREED

Wheaton Terrier

## SEX

Neuered male

## AGE

11 years

## WEIGHT

84.5 lbs

## INTERPRETED BY

Remo Lobetti, BVSc,  
MMedVet (Med),  
PhD, Dipl. ECVIM

## IMAGING PERFORMED BY

JK

## HOSPITAL NAME

Hamburg VC

## REFERRING VET

Dr. DenHeyer

## INVOICE

74122

## DATE

4/3/26

## PRESENTING CLINICAL SIGNS

- Black Tarry stools
- Blood and stool pending

## ULTRASONOGRAPHIC EXAMINATION OF THE ABDOMEN

### *Urinary System*

The urinary bladder is small with a normal thickness and smooth appearance of the wall. Normal anechoic urine with no sediment or uroliths evident.

Normal appearance of the trigone area, proximal urethra, and iliac blood vessels.

Normal appearance and size of the iliac lymph nodes. Ureters not visualized, which can be considered a normal finding.

Normal renal size (left measured 7.6 cm, right measured 7.5 cm), architecture, echogenic appearance, cortico-medullary differentiation, which maintains a 1:3 cortex to medulla ratio, pelvis, and capsule. No infarcts, mineralization or renoliths evident.

The prostate is small and hypoechogenic.

### *Adrenal Glands*

The left adrenal gland is normal in shape, echogenic appearance, size, position, and appearance of the visible peri-adrenal vasculature. Left adrenal gland measured 2.22 cm in length x 0.71 cm and 0.56 cm in width. The right adrenal gland was not clearly visualized, but appears to be of normal shape, echogenic appearance and size.

### *Spleen*

Normal size and echogenic appearance. Smooth homogenous parenchyma and regular curvilinear capsule. Normal volume of the splenic vasculature without any overt congestion or thrombosis evident. No inflammatory, neoplastic, infarction, or infiltrative changes evident. The spleen measured 1.7 cm in width.

### *Liver*

Normal size, echogenic appearance, portal markings, and regular curvilinear capsule. No nodules or masses evident. Normal appearance of the hepatic and portal vasculature.

### *Gallbladder*

The gallbladder is small containing normal anechoic bile. Normal thickness and echogenic appearance of the wall. Normal size and appearance of the cystic and common bile duct.



## PATIENT

Jameson Lynoff

## SPECIES

Canine

## BREED

Wheaton Terrier

## SEX

Neuered male

## AGE

11 years

## WEIGHT

84.5 lbs

## INTERPRETED BY

Remo Lobetti, BVSc,  
MMedVet (Med),  
PhD, Dipl. ECVIM

## IMAGING PERFORMED BY

JK

## HOSPITAL NAME

Hamburg VC

## REFERRING VET

Dr. DenHeyer

## INVOICE

74122

## DATE

4/3/26

## *Gastrointestinal*

Normal appearance of the stomach, duodenum, small intestine, ileo-cecal junction, and colon with no loss of layering, 1:3 muscularis to mucosa ratio, normal wall thickness and peristaltic activity, and no distension of the lumen.

## *Pancreas*

The visible sections of the pancreas are of normal size and echogenic appearance with a regular capsule. Normal echogenic appearance of the mesentery and fat surrounding the pancreas.

## *Free Abdomen*

Normal mesenteric lymph nodes.

No ascites evident.

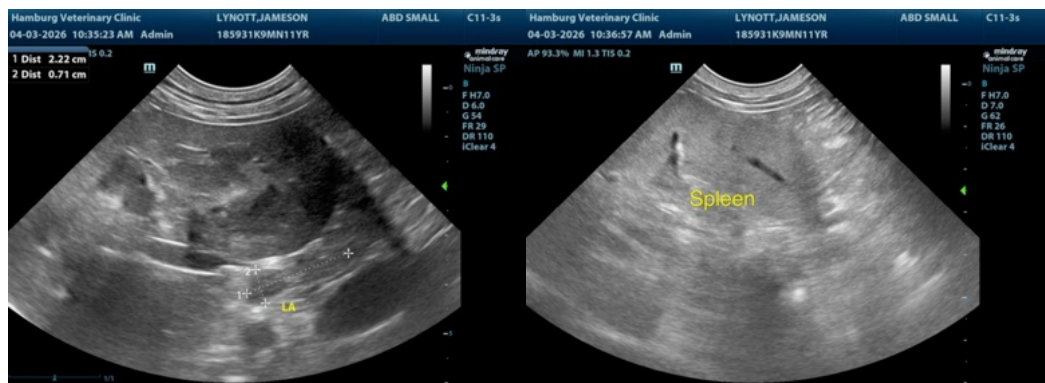
## ULTRASONOGRAPHIC FINDINGS

- Normal ultrasound examination of the abdomen.

## INTERPRETATION OF THE FINDINGS & FURTHER RECOMMENDATIONS

On this ultrasound there is no obvious etiology for the melena.

Further assessment and therapy needs to be based on physical examination findings and results of the pending blood work and fecal analysis.





**PATIENT**

Jameson Lynoff

**SPECIES**

Canine

**BREED**

Wheaton Terrier

**SEX**

Neuered male

**AGE**

11 years

**WEIGHT**

84.5 lbs

**INTERPRETED BY**

Remo Lobetti, BVSc,  
MMedVet (Med),  
PhD, Dipl. ECVIM

**IMAGING  
PERFORMED BY**

JK

**HOSPITAL NAME**

Hamburg VC

**REFERRING VET**

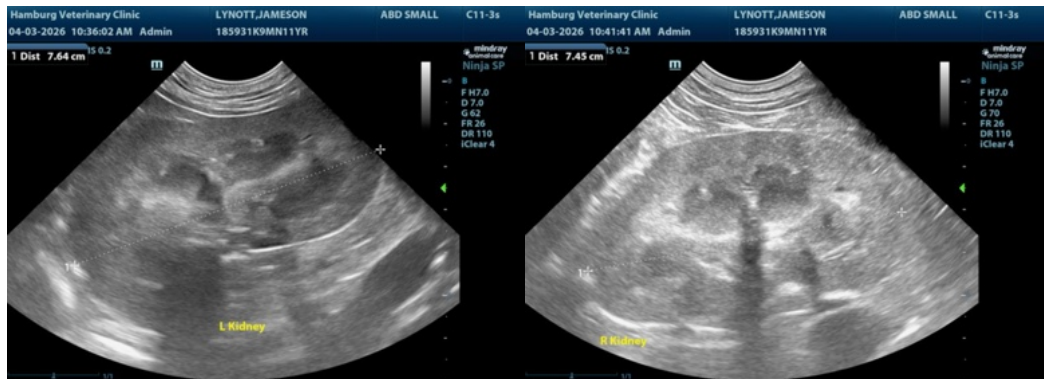
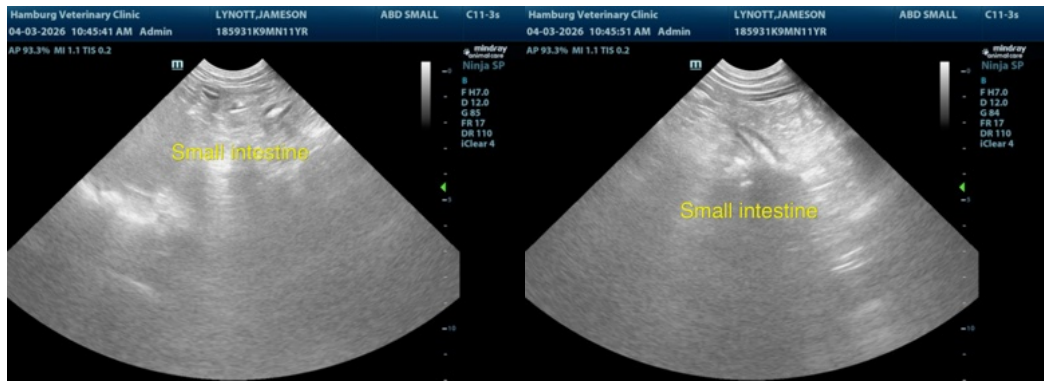
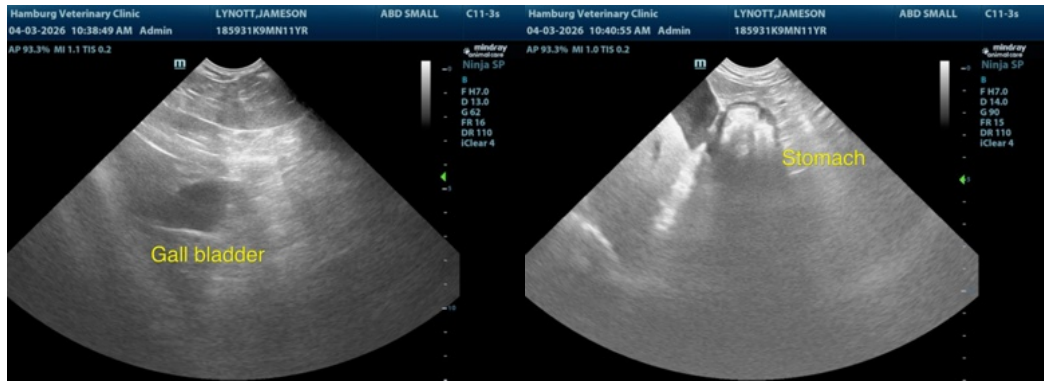
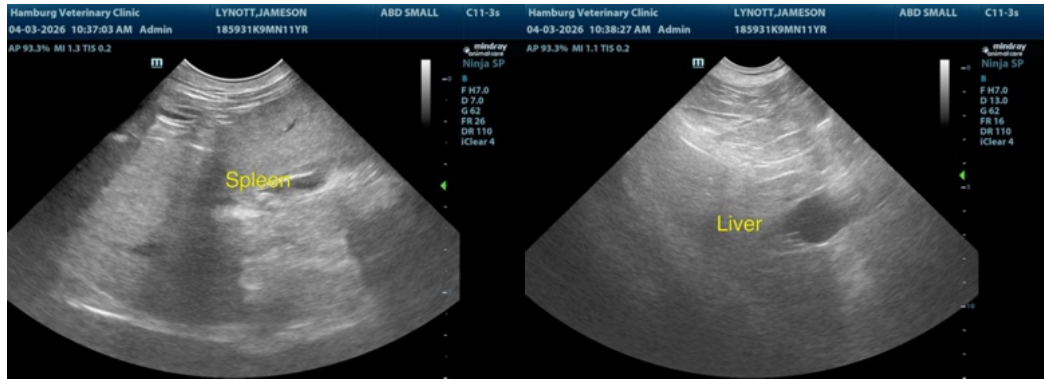
Dr. DenHeyer

**INVOICE**

74122

**DATE**

4/3/26





## PATIENT

Jameson Lynoff

## SPECIES

Canine

## BREED

Wheaton Terrier

## SEX

Neuered male

## AGE

11 years

## WEIGHT

84.5 lbs

## INTERPRETED BY

Remo Lobetti, BVSc,  
MMedVet (Med),  
PhD, Dipl. ECVIM

## IMAGING PERFORMED BY

JK

## HOSPITAL NAME

Hamburg VC

## REFERRING VET

Dr. DenHeyer

## INVOICE

74122

## DATE

4/3/26

The information and recommendations provided are based on the images presented by the referring veterinarian/sonographer. No evaluation can be communicated regarding pathology that was not visible in the image/video clips provided.

Thank you for this referral. If the clinical or image interpretation does not parallel your findings or if I can be of any further assistance please contact me.

Remo Lobetti, BVSc, MMedVet (Med), PhD, Dipl. ECVIM (Internal Medicine)

[info@sonopath.com](mailto:info@sonopath.com)