



PATIENT

Gigi Pontoriero

SPECIES

Canine

BREED

Shih Tzu

SEX

Neutered Male

AGE

9 Years

WEIGHT

11.2 lbs

INTERPRETED BY

Remo Lobetti, BVSc,
MMedVet (Med),
PhD, Dipl. ECVIM

IMAGING PERFORMED BY

Vincent Ravancho, CVT

HOSPITAL NAME

St Georges Veterinary
Hospital

REFERRING VET

Dr. Ng

INVOICE

74725

DATE

4/23/26

PRESENTING CLINICAL SIGNS

Distal colon ventral mass about 2cm. Hx of severe atopy. Recent hx of rectal prolapse and hematochezia. Fecal Negative. Current medications - Prednisone tapering, Tacrolimus for KCS.

Abnormal PE/Chem/CBC/UA Results: Creat 1.8, Glob 3.7. USG 1.040

ULTRASONOGRAPHIC EXAMINATION OF THE ABDOMEN

Urinary System

Full urinary bladder with a normal thickness and smooth appearance of the wall. Normal anechoic urine with no sediment or uroliths evident.

Normal appearance of the trigone area, proximal urethra, and iliac blood vessels.

Normal appearance and size of the iliac lymph nodes. Ureters not visualized, which can be considered a normal finding.

Normal renal size, architecture, echogenic appearance, cortico-medullary differentiation, which maintains a 1:3 cortex to medulla ratio, pelvis, and capsule. No infarcts, mineralization or renoliths evident. The kidneys measure 3.9 cm each, with normal color flow pattern evident.

Reproductive System

Small, hypoechogenic prostate.

Adrenal Glands

Normal shape, echogenic appearance, size, position, and appearance of the visible peri-adrenal vasculature. Left measures 1.84 cm in width x 0.44 cm and 0.40 cm in width. Right measures 1.05 cm in length x 0.45 cm and 0.70 cm in width.

Spleen

Normal size (1.1 cm in width) and echogenic appearance. Smooth homogenous parenchyma and regular curvilinear capsule. Normal volume of the splenic vasculature without any overt congestion or thrombosis evident. No inflammatory, neoplastic, infarction, or infiltrative changes evident.

Liver

Normal size, echogenic appearance, portal markings, and regular curvilinear capsule. No nodules or masses evident. Normal appearance of the hepatic and portal vasculature.

Gallbladder

Full containing normal anechoic bile. Normal thickness and echogenic appearance of the wall. Normal size and appearance of the cystic and common bile duct.

Gastrointestinal

Normal appearance of the stomach, duodenum, small intestine, ileo-cecal junction, and colon with no loss of layering, 1:3 muscularis to mucosa ratio, normal wall thickness and peristaltic activity, and no distension of the lumen. Fecal material present within the colon.



PATIENT

Gigi Pontoriero

SPECIES

Canine

BREED

Shih Tzu

SEX

Neutered Male

AGE

9 Years

WEIGHT

11.2 lbs

INTERPRETED BY

Remo Lobetti, BVSc,
MMedVet (Med),
PhD, Dipl. ECVIM

IMAGING PERFORMED BY

Vincent Ravancho, CVT

HOSPITAL NAME

St Georges Veterinary
Hospital

REFERRING VET

Dr. Ng

INVOICE

74725

DATE

4/23/26

Pancreas

Visible sections present normal size and echogenic appearance. Regular capsule. Normal echogenic appearance of the mesentery and fat surrounding the pancreas.

Free Abdomen

Normal mesenteric lymph nodes.

No ascites evident.

ULTRASONOGRAPHIC FINDINGS

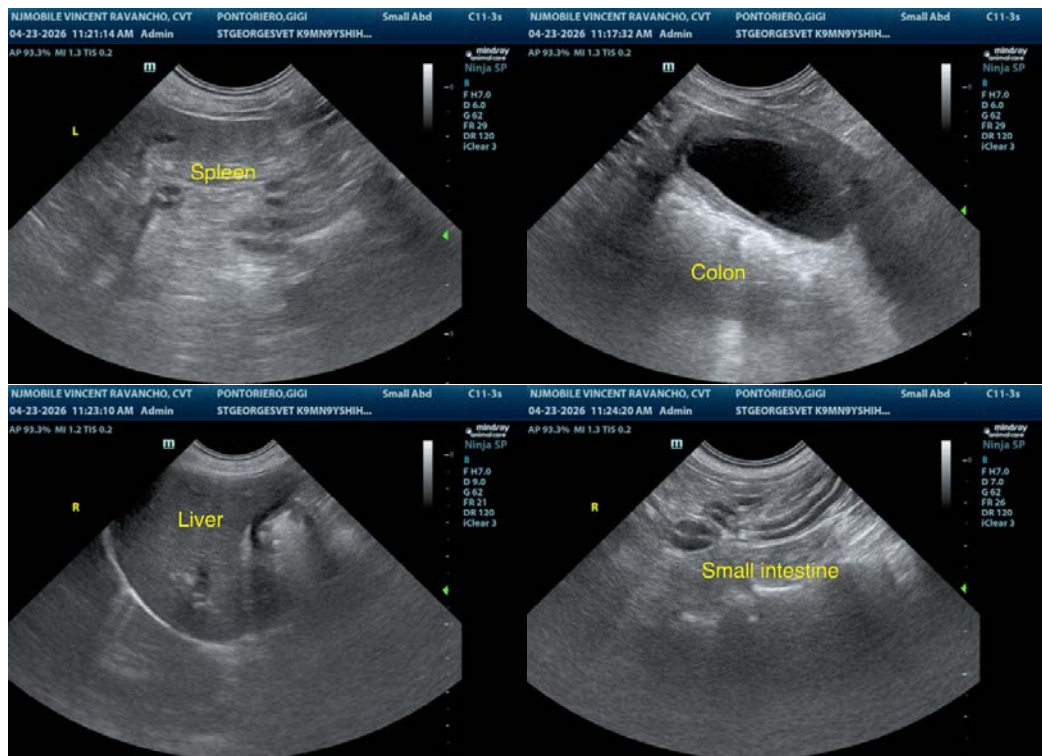
- Normal ultrasound examination of the abdomen.

INTERPRETATION OF THE FINDINGS & FURTHER RECOMMENDATIONS

On this ultrasound there is no obvious etiology for the presenting clinical signs, and no obvious colonic mass evident, which may have been affected by the Prednisolone therapy.

Further assessment that could be considered would be rectal cytobrush cytology and colonoscopy with biopsies.

Further specific therapy would be dependent on an etiological diagnosis.





PATIENT

Gigi Pontoriero

SPECIES

Canine

BREED

Shih Tzu

SEX

Neutered Male

AGE

9 Years

WEIGHT

11.2 lbs

INTERPRETED BY

Remo Lobetti, BVSc,
MMedVet (Med),
PhD, Dipl. ECVIM

IMAGING PERFORMED BY

Vincent Ravancho, CVT

HOSPITAL NAME

St Georges Veterinary
Hospital

REFERRING VET

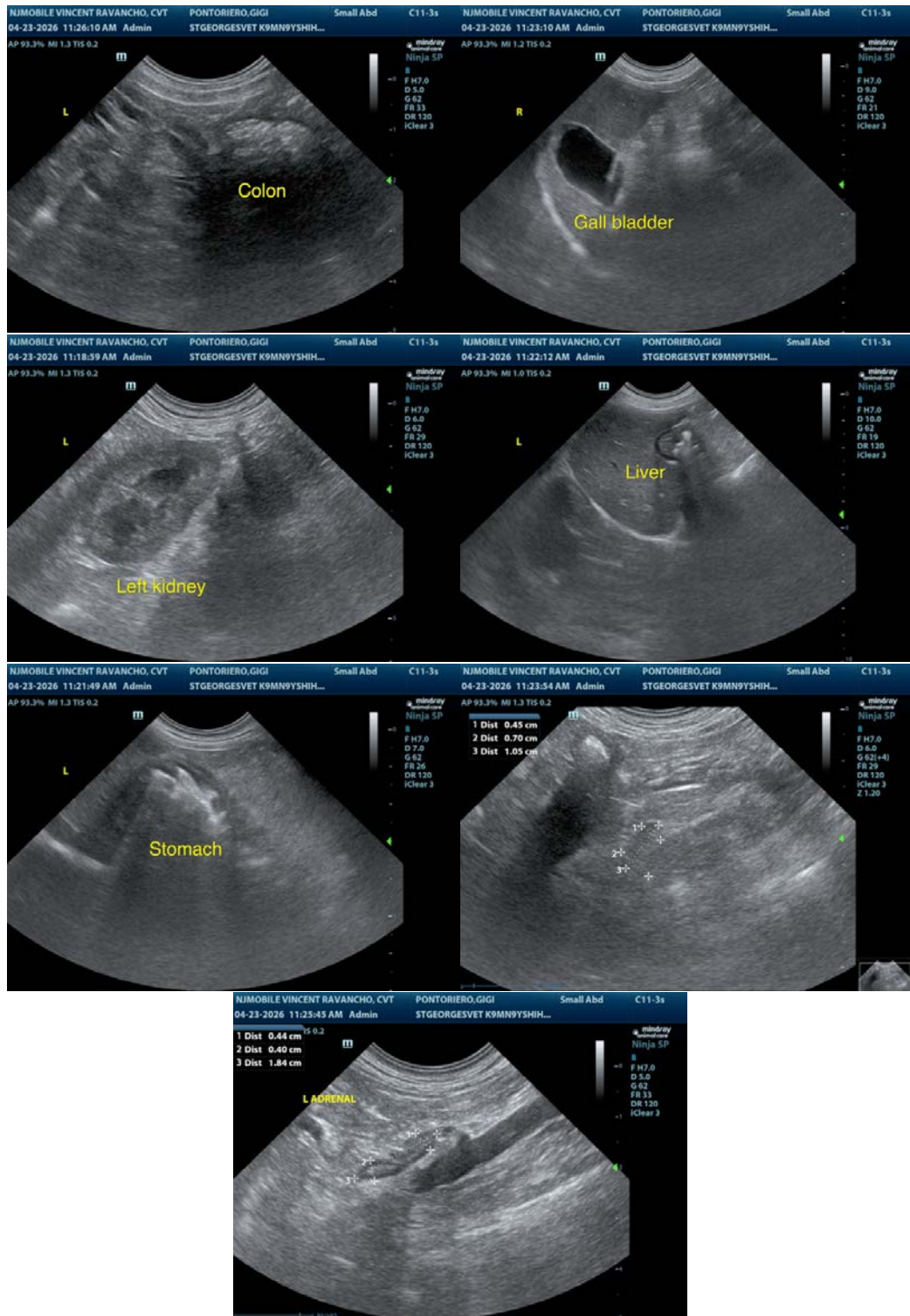
Dr. Ng

INVOICE

74725

DATE

4/23/26





PATIENT

Gigi Pontoriero

SPECIES

Canine

BREED

Shih Tzu

SEX

Neutered Male

AGE

9 Years

WEIGHT

11.2 lbs

INTERPRETED BY

Remo Lobetti, BVSc,
MMedVet (Med),
PhD, Dipl. ECVIM

**IMAGING
PERFORMED BY**

Vincent Ravancho, CVT

HOSPITAL NAME

St Georges Veterinary
Hospital

REFERRING VET

Dr. Ng

INVOICE

74725

DATE

4/23/26

The information and recommendations provided are based on the images presented by the referring veterinarian. No evaluation can be communicated regarding pathology that was not visible in the image/video clips provided.

Thank you for this referral. If the clinical or image interpretation does not parallel your findings or if I can be of any further assistance, please contact me.

Remo Lobetti, BVSc, MMedVet (Med), PhD, Dipl. ECVIM (Internal Medicine)

info@sonopath.com