



## PATIENT

Mimi Mann

## SPECIES

Canine

## BREED

Boxer Mix

## SEX

Spayed female

## AGE

8 years

## WEIGHT

58 lbs

## INTERPRETED BY

Remo Lobetti, BVSc,  
MMedVet (Med),  
PhD, Dipl. ECVIM

## IMAGING PERFORMED BY

Nikki Wright

## HOSPITAL NAME

Bush AH

## REFERRING VET

Dr. Blystone

## INVOICE

74750

## DATE

4/22/26

## PRESENTING CLINICAL SIGNS

History: Reason for ultrasound, relevant medical history: Chronic low appetite. Acute v/d  
PVPs: Trazodone/Gabapentin  
sedated with torb/midaz

Abnormal PE/Chem/CBC/UA Results: CBC: Mild stress leukogram Chem: Alb 2.6, Glob 4.3, Cystatin  
B 302 Spec Cpl 1162

## ULTRASONOGRAPHIC EXAMINATION OF THE ABDOMEN

### Urinary System

The urinary bladder is small with a normal thickness and smooth appearance of the wall. Normal anechoic urine with no sediment or uroliths evident.

Normal appearance of the trigone area, proximal urethra, and iliac blood vessels.

Normal appearance and size of the iliac lymph nodes. Ureters not visualized, which can be considered a normal finding.

The left kidney was not clearly visualized, but appears to be of normal size, shape and echogenicity appearance. The left kidney measured 6.4 cm. Normal color flow pattern is evident.

The right kidney is not clearly visualized, but appears to be of normal size, shape and echogenic appearance.

### Adrenal Glands

The left adrenal gland is normal in shape, echogenic appearance, size, position, and appearance of the visible peri-adrenal vasculature. Left adrenal gland measured 0.59 cm in width. The right adrenal gland was not visualized.

### Spleen

Normal size and echogenic appearance. Smooth homogenous parenchyma and regular curvilinear capsule. Normal volume of the splenic vasculature without any overt congestion or thrombosis evident. No inflammatory, neoplastic, infarction, or infiltrative changes evident. The spleen measured 2.5 cm in width.

### Liver

Normal size, echogenic appearance, portal markings, and regular curvilinear capsule. No nodules or masses evident. Normal appearance of the hepatic and portal vasculature.



## PATIENT

Mimi Mann

## SPECIES

Canine

## BREED

Boxer Mix

## SEX

Spayed female

## AGE

8 years

## WEIGHT

58 lbs

## INTERPRETED BY

Remo Lobetti, BVSc,  
MMedVet (Med),  
PhD, Dipl. ECVIM

## IMAGING PERFORMED BY

Nikki Wright

## HOSPITAL NAME

Bush AH

## REFERRING VET

Dr. Blystone

## INVOICE

74750

## DATE

4/22/26

## ***Gallbladder***

The gallbladder is small containing normal anechoic bile. Normal thickness and echogenic appearance of the wall. Normal size and appearance of the cystic and common bile duct.

## ***Gastrointestinal***

Normal appearance of the stomach, duodenum, small intestine, ileo-cecal junction, and colon with no loss of layering, 1:3 muscularis to mucosa ratio, normal wall thickness and peristaltic activity, and no distension of the lumen.

## ***Pancreas***

The pancreas is not clearly visualized, but the visible sections of the pancreas are of normal size and echogenic appearance with a regular capsule. Normal echogenic appearance of the mesentery and fat surrounding the pancreas.

## ***Free Abdomen***

Normal mesenteric lymph nodes.

A moderate amount of acellular ascites is present.

Hyperechogenic and nodular appearance of the mesentery.

## **ULTRASONOGRAPHIC FINDINGS**

- Mesenteric inflammation
- Ascites.

## **INTERPRETATION OF THE FINDINGS & FURTHER RECOMMENDATIONS**

Etiologies for the mesenteric inflammation and ascites would be pancreatitis (in line with the severely elevated CPL), sterile peritonitis, bacterial peritonitis and possibly abdominal carcinomatosis.

Further assessment would be three view thoracic radiographs, analysis of the ascitic fluid and possibly FNA cytology of the mesentery.

Specific therapy would be dependent on an etiological diagnosis.



## PATIENT

Mimi Mann

## SPECIES

Canine

## BREED

Boxer Mix

## SEX

Spayed female

## AGE

8 years

## WEIGHT

58 lbs

## INTERPRETED BY

Remo Lobetti, BVSc,  
MMedVet (Med),  
PhD, Dipl. ECVIM

## IMAGING PERFORMED BY

Nikki Wright

## HOSPITAL NAME

Bush AH

## REFERRING VET

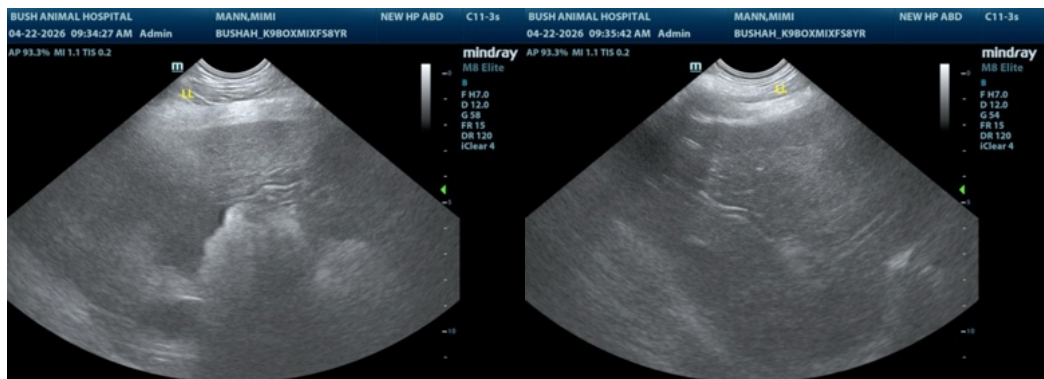
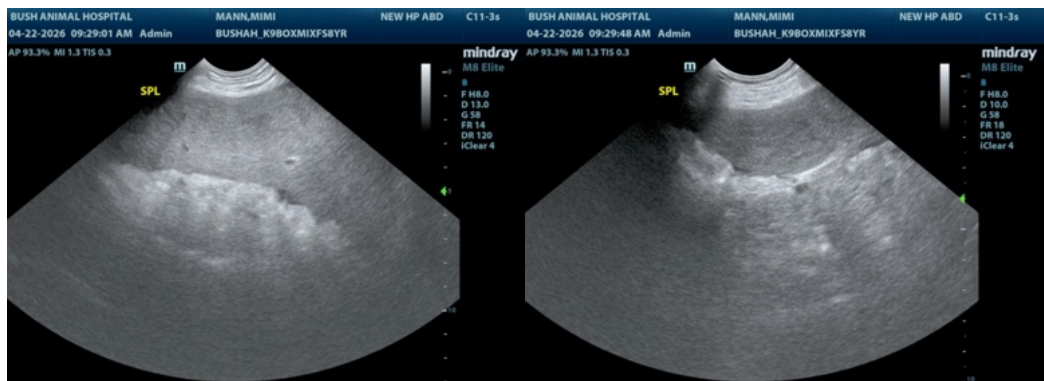
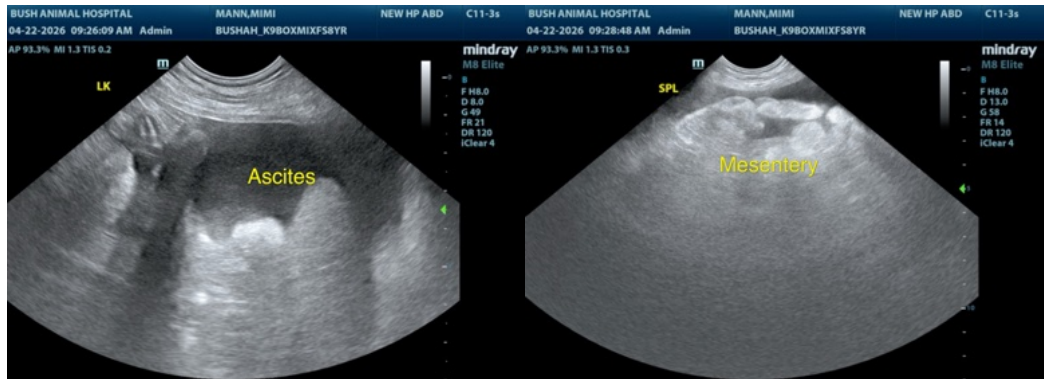
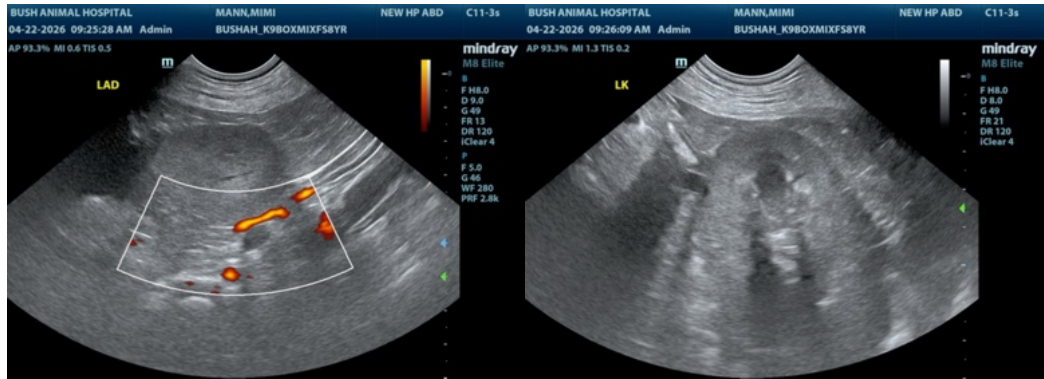
Dr. Blystone

## INVOICE

74750

## DATE

4/22/26





## PATIENT

Mimi Mann

## SPECIES

Canine

## BREED

Boxer Mix

## SEX

Spayed female

## AGE

8 years

## WEIGHT

58 lbs

## INTERPRETED BY

Remo Lobetti, BVSc,  
MMedVet (Med),  
PhD, Dipl. ECVIM

## IMAGING PERFORMED BY

Nikki Wright

## HOSPITAL NAME

Bush AH

## REFERRING VET

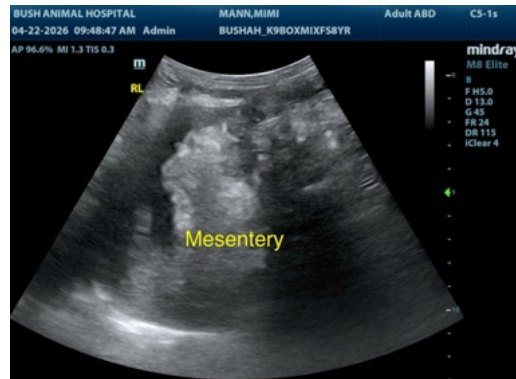
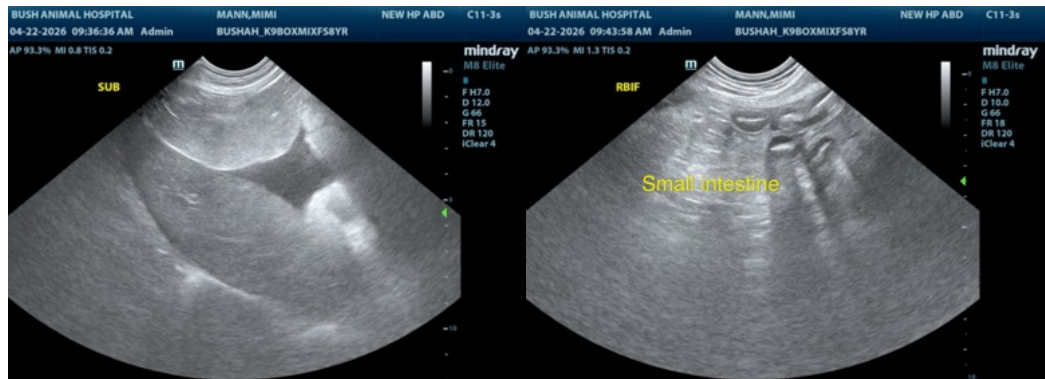
Dr. Blystone

## INVOICE

74750

## DATE

4/22/26



The information and recommendations provided are based on the images presented by the referring veterinarian/sonographer. No evaluation can be communicated regarding pathology that was not visible in the image/video clips provided.

Thank you for this referral. If the clinical or image interpretation does not parallel your findings or if I can be of any further assistance please contact me.

Remo Lobetti, BVSc, MMedVet (Med), PhD, Dipl. ECVIM (Internal Medicine)

[info@sonopath.com](mailto:info@sonopath.com)