

PATIENT

Duke Williams

SPECIES

Canine

BREED

Cane Corso

SEX

Neutered male

AGE

10 years

WEIGHT

132 lbs

INTERPRETED BY

Remo Lobetti, BVSc,
MMedVet (Med),
PhD, Dipl. ECVIM

IMAGING PERFORMED BY

Ukachi Ugorgi DVM

HOSPITAL NAME

Craig Road AH

REFERRING VET

Dr. Lutz

INVOICE

74762

DATE

4/22/26

PRESENTING CLINICAL SIGNS

History: ascites found on PE -drained 1500ml prior to ultrasound. Very large heart on chest xrays (concern for DCM)

Abnormal PE/Chem/CBC/UA Results: Albumin 2.3

ULTRASONOGRAPHIC EXAMINATION OF THE ABDOMEN

Urinary System

The urinary bladder is full with a normal thickness and smooth appearance of the wall. Normal anechoic urine with no sediment or uroliths evident.

Normal appearance of the trigone area, proximal urethra, and iliac blood vessels.

Normal appearance and size of the iliac lymph nodes. Ureters not visualized, which can be considered a normal finding.

Normal renal size (left measured 7.8 cm, right measured 8.3 cm), architecture, echogenic appearance, cortico-medullary differentiation, which maintains a 1:3 cortex to medulla ratio, pelvis, and capsule. No infarcts, mineralization or renoliths evident.

The prostate is small and hypoechogenic measuring 1.1 cm in width.

Adrenal Glands

Normal shape, echogenic appearance, size, position, and appearance of the visible peri-adrenal vasculature. Left adrenal gland measured 0.64 cm and 0.6 cm in width. The right adrenal gland measured 0.62 cm and 0.64 cm in width.

Spleen

Normal size and echogenic appearance. Smooth homogenous parenchyma and regular curvilinear capsule. Normal volume of the splenic vasculature without any overt congestion or thrombosis evident. No inflammatory, neoplastic, infarction, or infiltrative changes evident. The spleen measured 3.5 cm in width.

Liver

Normal size, echogenic appearance, portal markings, and regular curvilinear capsule. No nodules or masses evident. Normal appearance of the hepatic and portal vasculature.

Gallbladder

The gallbladder is full containing normal anechoic bile. Thickened and hyperechogenic appearance of the wall with a hypoechogenic rim around the gallbladder wall (halo effect) with a hypoechogenic rim around the gallbladder. Normal size and appearance of the cystic and common bile duct.



PATIENT

Duke Williams

SPECIES

Canine

BREED

Cane Corso

SEX

Neutered male

AGE

10 years

WEIGHT

132 lbs

INTERPRETED BY

Remo Lobetti, BVSc,
MMedVet (Med),
PhD, Dipl. ECVIM

IMAGING PERFORMED BY

Ukachi Ugorgi DVM

HOSPITAL NAME

Craig Road AH

REFERRING VET

Dr. Lutz

INVOICE

74762

DATE

4/22/26

Gastrointestinal

Normal appearance of the stomach, duodenum, small intestine, ileo-cecal junction, and colon with no loss of layering, 1:3 muscularis to mucosa ratio, normal wall thickness and peristaltic activity, and no distension of the lumen. A small amount of ingesta was present within the stomach. Chyme was present in the small intestine both compatible with a recent meal. Fecal material is present within the colon.

Pancreas

The visible sections of the pancreas are of normal size and echogenic appearance with a regular capsule. Normal echogenic appearance of the mesentery and fat surrounding the pancreas.

Free Abdomen

Enlarged mesenteric lymph nodes measuring up to 0.8 x 2.0 cm in size maintaining a normal shape and echogenic appearance.

A moderate amount of acellular ascites is present.

ULTRASONOGRAPHIC FINDINGS

- Mesenteric lymphadenomegaly.
- Ascites.
- Gallbladder halo effect

INTERPRETATION OF THE FINDINGS & FURTHER RECOMMENDATIONS

The most likely etiology for the mesenteric lymphadenomegaly would be reactive hyperplasia with lymphadenitis and infiltrative neoplasia a highly unlikely differential diagnosis.

With the presence of cardiomegaly on survey thoracic radiographs the most likely etiology for the ascites would be secondary to heart disease.

Etiologies for the appearance of the gallbladder would be previous cholecystitis secondary to hypoalbuminemia or secondary to heart failure.

Further assessment would be echocardiography, FNA cytology of the mesenteric lymph nodes and analysis of the ascitic fluid could also be considered.

Specific therapy would be dependent on an etiological diagnosis.



PATIENT

Duke Williams

SPECIES

Canine

BREED

Cane Corso

SEX

Neutered male

AGE

10 years

WEIGHT

132 lbs

INTERPRETED BY

Remo Lobetti, BVSc,
MMedVet (Med),
PhD, Dipl. ECVIM

IMAGING PERFORMED BY

Ukachi Ugorgi DVM

HOSPITAL NAME

Craig Road AH

REFERRING VET

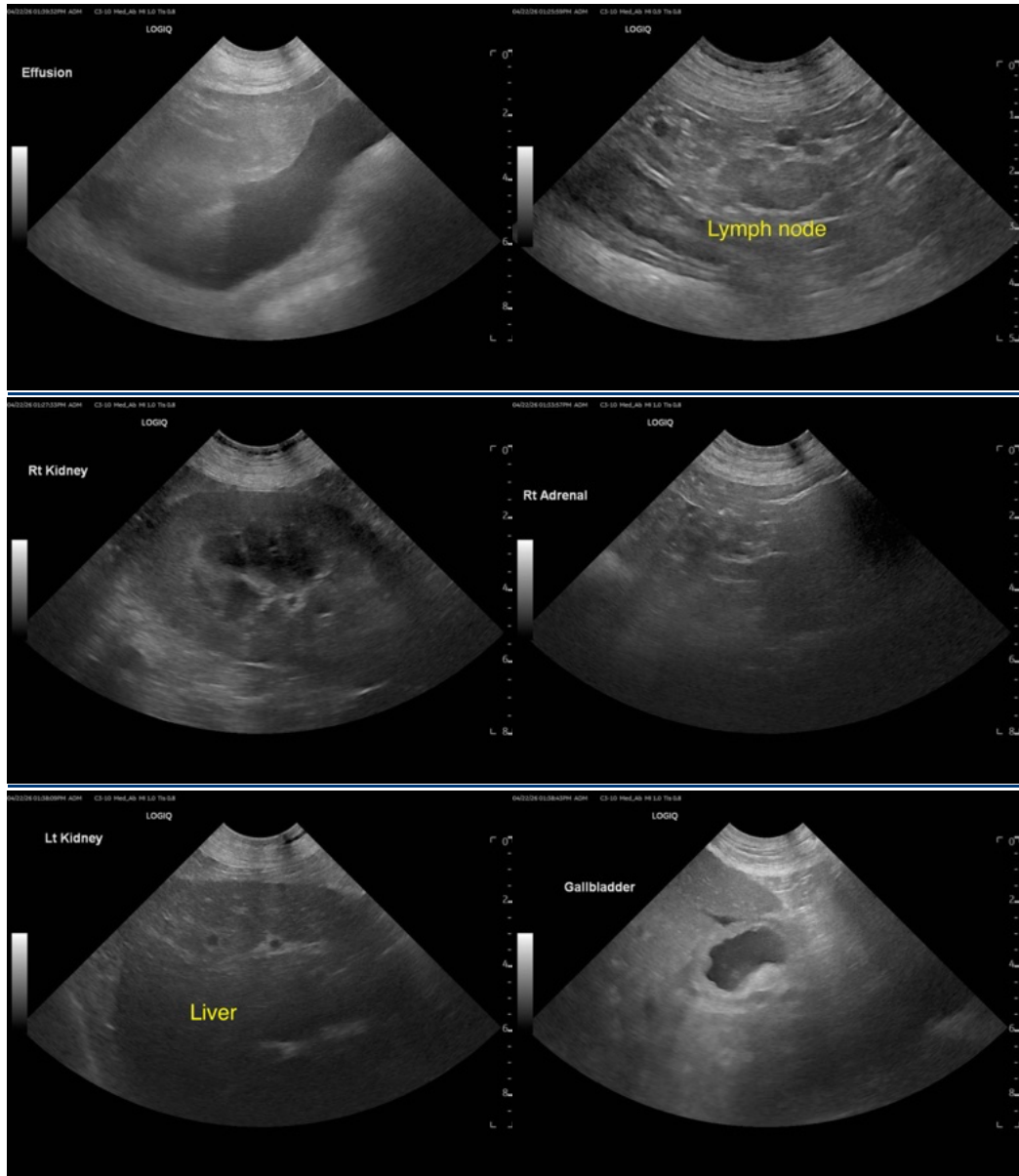
Dr. Lutz

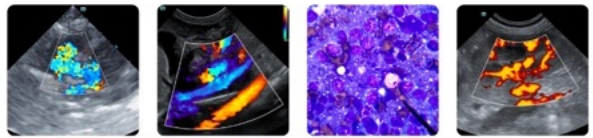
INVOICE

74762

DATE

4/22/26





PATIENT

Duke Williams

SPECIES

Canine

BREED

Cane Corso

SEX

Neutered male

AGE

10 years

WEIGHT

132 lbs

INTERPRETED BY

Remo Lobetti, BVSc,
MMedVet (Med),
PhD, Dipl. ECVIM

IMAGING PERFORMED BY

Ukachi Ugorgi DVM

HOSPITAL NAME

Craig Road AH

REFERRING VET

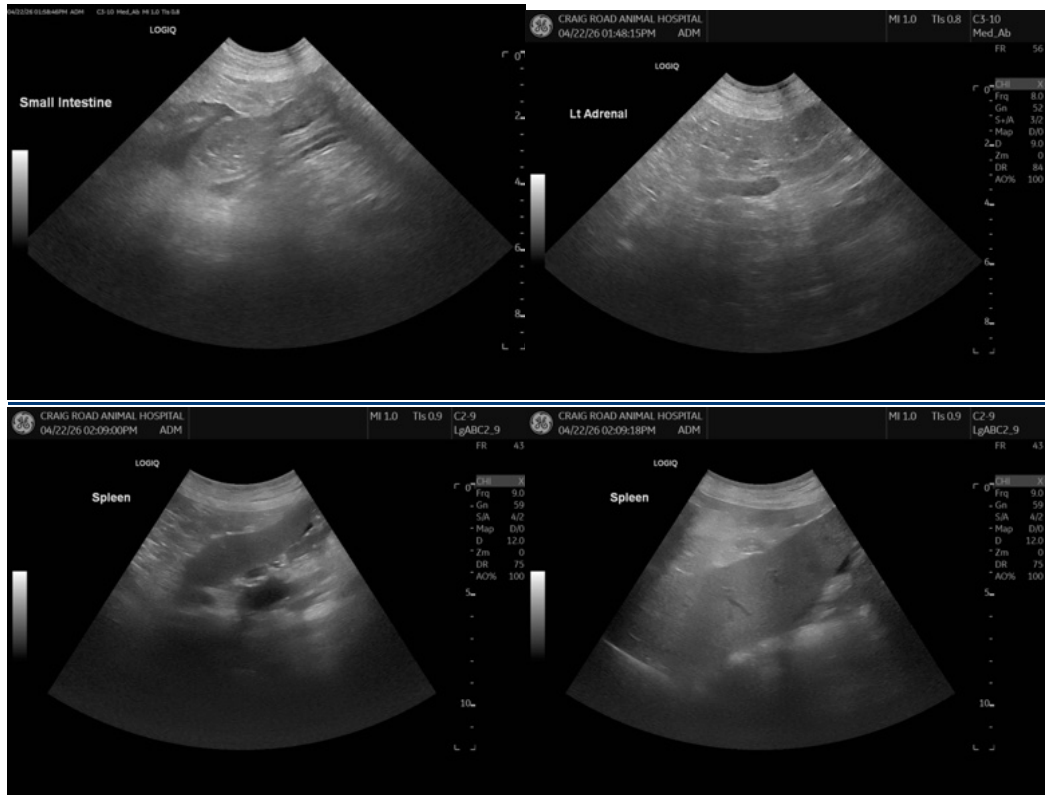
Dr. Lutz

INVOICE

74762

DATE

4/22/26



The information and recommendations provided are based on the images presented by the referring veterinarian/sonographer. No evaluation can be communicated regarding pathology that was not visible in the image/video clips provided.

Thank you for this referral. If the clinical or image interpretation does not parallel your findings or if I can be of any further assistance please contact me.

Remo Lobetti, BVSc, MMedVet (Med), PhD, Dipl. ECVIM (Internal Medicine)

info@sonopath.com