



PATIENT

Bailey Fertenbaugh

SPECIES

Canine

BREED

Cockapoo

SEX

Spayed female

AGE

4 years

WEIGHT

14.4 kg

INTERPRETED BY

Remo Lobetti, BVSc,
MMedVet (Med),
PhD, Dipl. ECVIM

IMAGING PERFORMED BY

Erin Wicks

HOSPITAL NAME

Shores Veterinary
Emergency Center

REFERRING VET

Dr. Law

INVOICE

74706

DATE

4/21/26

PRESENTING CLINICAL SIGNS

History: Seen 3/31/26 for vomiting, hx of intermittent vomiting/dh for years, switched foods to gastro foods several times since last seen, now back on royal canin gastro food, it seems to help the most. When seen here DVM mentioned that next step would be AUS if not improving on medication and diet change.

Meds Provable ; Cosequin

Prev on : Famotidine ; Prednisone; Emeprev

Abnormal PE/Chem/CBC/UA Results: Rads: 3/31 Round soft tissue gastric content. This likely is likely secondary to the patient's diet and likely represents ingesta. Gastric foreign content cannot be excluded. Mild hepatomegaly. This is a nonspecific finding. Differential diagnoses to consider include metabolic disease (hyperadrenocorticism, steroid induced or diabetes mellitus), hepatitis, nodular hyperplasia, congestion or neoplasia. Bloodwork 3/24 : HCT 62.9; HGB 20.7; RBC 8.93; Na 152; Lac 3.36

ULTRASONOGRAPHIC EXAMINATION OF THE ABDOMEN

Urinary System

The urinary bladder is small with a normal thickness and smooth appearance of the wall. Normal anechoic urine with no sediment or uroliths evident.

Normal appearance of the trigone area, proximal urethra, and iliac blood vessels.

Normal appearance and size of the iliac lymph nodes. Ureters not visualized, which can be considered a normal finding.

Normal renal size (left measured 5.4 cm, right measured 5.6 cm), architecture, echogenic appearance, cortico-medullary differentiation, which maintains a 1:3 cortex to medulla ratio, pelvis, and capsule. No infarcts, mineralization or renoliths evident.

Adrenal Glands

Normal shape, echogenic appearance, size, position, and appearance of the visible peri-adrenal vasculature. Left adrenal gland measured 2.22 cm in length x 0.44 cm and 0.34 cm in width. The right adrenal gland measured 1.73 cm in length x 0.44 cm and 0.28 cm in width.

Spleen

Normal size and echogenic appearance. Smooth homogenous parenchyma and regular curvilinear capsule. Normal volume of the splenic vasculature without any overt congestion or thrombosis evident. No inflammatory, neoplastic, infarction, or infiltrative changes evident. The spleen measured 1.7 cm in width.



PATIENT

Bailey Fertenbaugh

SPECIES

Canine

BREED

Cockapoo

SEX

Spayed female

AGE

4 years

WEIGHT

14.4 kg

INTERPRETED BY

Remo Lobetti, BVSc,
MMedVet (Med),
PhD, Dipl. ECVIM

IMAGING PERFORMED BY

Erin Wicks

HOSPITAL NAME

Shores Veterinary
Emergency Center

REFERRING VET

Dr. Law

INVOICE

74706

DATE

4/21/26

Liver

Normal size, echogenic appearance, portal markings, and regular curvilinear capsule. No nodules or masses evident. Normal appearance of the hepatic and portal vasculature.

Gallbladder

The gallbladder is full containing normal anechoic bile. Normal thickness and echogenic appearance of the wall. Normal size and appearance of the cystic and common bile duct.

Gastrointestinal

Normal appearance of the stomach, duodenum, small intestine, ileo-cecal junction, and colon with no loss of layering, 1:3 muscularis to mucosa ratio, normal wall thickness and peristaltic activity, and no distension of the lumen. A small amount of gas was present in the stomach. Fecal material is present within the colon.

Pancreas

The visible sections of the pancreas are of normal size and echogenic appearance with a regular capsule. Normal echogenic appearance of the mesentery and fat surrounding the pancreas.

Free Abdomen

Normal mesenteric lymph nodes.

No ascites evident.

ULTRASONOGRAPHIC FINDINGS

- Normal ultrasound examination of the abdomen.

INTERPRETATION OF THE FINDINGS & FURTHER RECOMMENDATIONS

On this ultrasound there is no obvious etiology for the chronic vomiting.

Although the GI tract appears ultrasonographically normal, with the presenting clinical signs an underlying gastroenteropathy such as chronic gastritis, Helicobacter gastritis, parasitic gastroenteritis, dietary hypersensitivity and inflammatory bowel disease should still be considered.

Further assessment would be fecal analysis, cobalamin and folate assay and endoscopy of the upper GI tract with biopsies.

Specific therapy would be dependent on an etiological diagnosis.



PATIENT

Bailey Fertenbaugh

SPECIES

Canine

BREED

Cockapoo

SEX

Spayed female

AGE

4 years

WEIGHT

14.4 kg

INTERPRETED BY

Remo Lobetti, BVSc,
MMedVet (Med),
PhD, Dipl. ECVIM

IMAGING PERFORMED BY

Erin Wicks

HOSPITAL NAME

Shores Veterinary
Emergency Center

REFERRING VET

Dr. Law

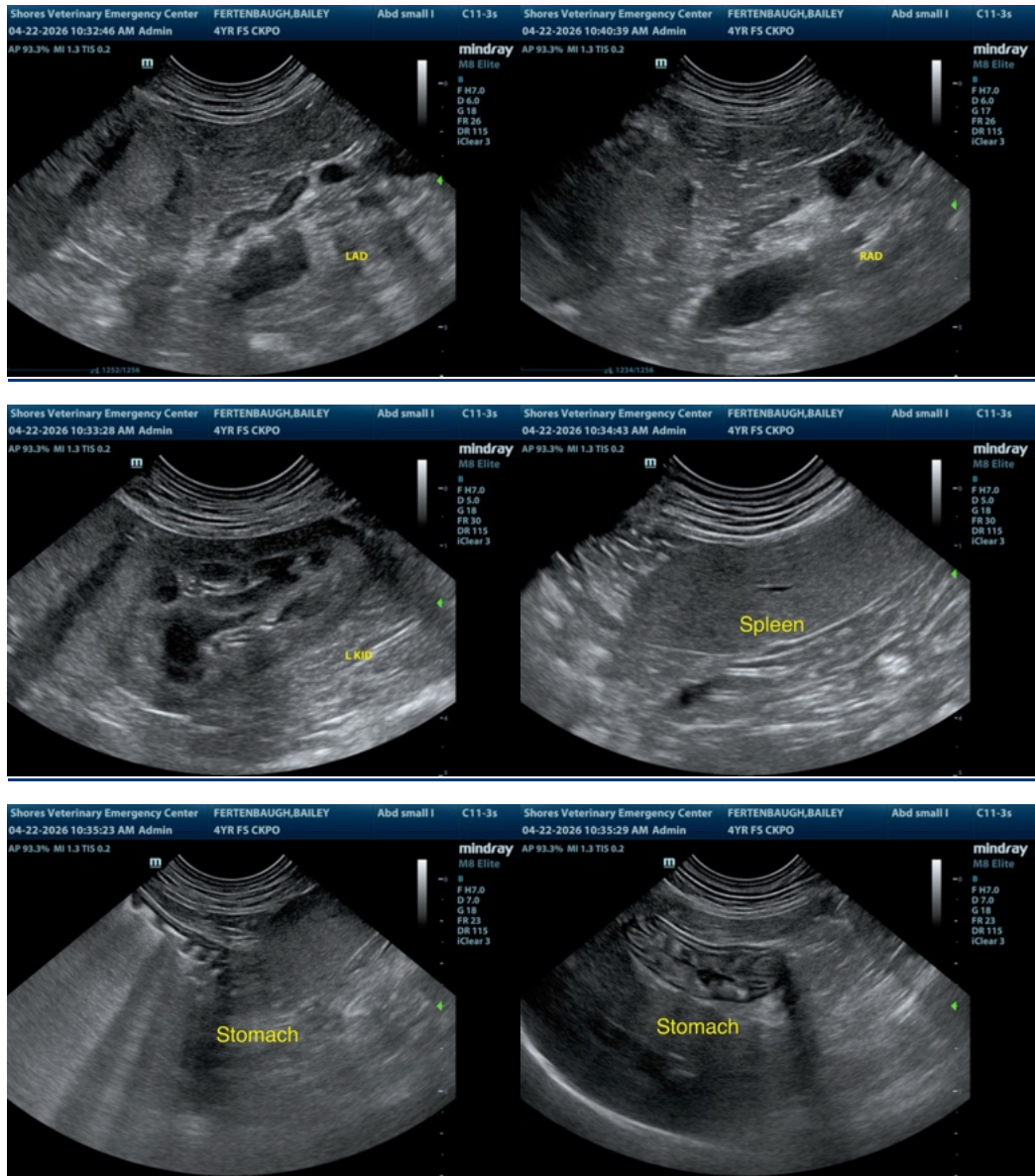
INVOICE

74706

DATE

4/21/26

Symptomatic management that could be considered would be feeding small frequent meals of a novel protein/hypoallergenic diet, course of Fenbendazole, cobalamin supplementation and if there is still not a satisfactory improvement then triple therapy for Helicobacter gastritis and if there is still not a satisfactory improvement then a course of Prednisolone would then be indicated.





PATIENT

Bailey Fertenbaugh

SPECIES

Canine

BREED

Cockapoo

SEX

Spayed female

AGE

4 years

WEIGHT

14.4 kg

INTERPRETED BY

Remo Lobetti, BVSc,
MMedVet (Med),
PhD, Dipl. ECVIM

IMAGING PERFORMED BY

Erin Wicks

HOSPITAL NAME

Shores Veterinary
Emergency Center

REFERRING VET

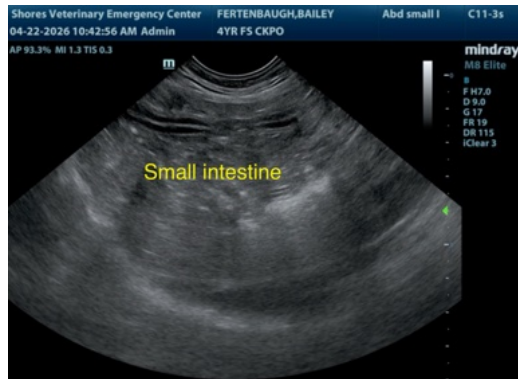
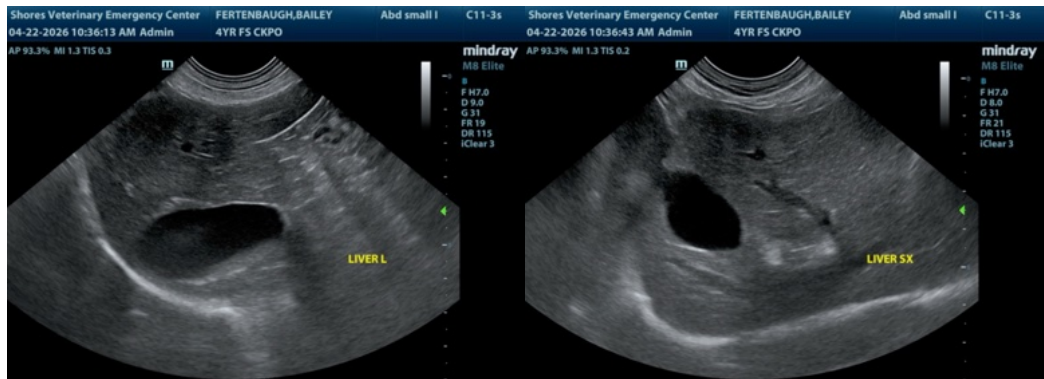
Dr. Law

INVOICE

74706

DATE

4/21/26



The information and recommendations provided are based on the images presented by the referring veterinarian/sonographer. No evaluation can be communicated regarding pathology that was not visible in the image/video clips provided.

Thank you for this referral. If the clinical or image interpretation does not parallel your findings or if I can be of any further assistance please contact me.

Remo Lobetti, BVSc, MMedVet (Med), PhD, Dipl. ECVIM (Internal Medicine)

info@sonopath.com