



PATIENT

Sven Thomas

SPECIES

Feline

BREED

Domestic Shorthair

SEX

Intact male

AGE

9 ½ years

WEIGHT

15.1 lbs

INTERPRETED BY

Remo Lobetti, BVSc,
MMedVet (Med),
PhD, Dipl. ECVIM

IMAGING PERFORMED BY

Dr. Arms

HOSPITAL NAME

Gilbertsville VH

REFERRING VET

Dr. Arms

INVOICE

74046

DATE

4/2/26

PRESENTING CLINICAL SIGNS

- Chronic vomit, often with hair/hairball
- Hx jejunal foreign body 2021 with 10cm resection and bx of mild-moderate eosinophilic enteritis.
- vomit well managed up until 2 months ago on GI biome with recently added Purina EN.
- Also has history soft tissue sarcoma left hind (intermediate grade) and cutaneous MCT low grade all completely excised.
- Hx HCM monitored with echo Q6m - no meds currently
- Hx allergies with skin / hair loss/ otitis managed with antihistamines and fatty acids - rare pred taper needed.

ULTRASONOGRAPHIC EXAMINATION OF THE ABDOMEN

Urinary System

The urinary bladder is small with a normal thickness and smooth appearance of the wall. Normal anechoic urine with no sediment or uroliths evident.

Normal appearance of the trigone area, proximal urethra, and iliac blood vessels.

Normal appearance and size of the iliac lymph nodes. Ureters not visualized, which can be considered a normal finding.

Normal renal size (left measured 3.7 cm, right measured 3.8 cm), architecture, echogenic appearance, cortico-medullary differentiation, which maintains a 1:3 cortex to medulla ratio, pelvis, and capsule. No infarcts, mineralization or renoliths evident.

Adrenal Glands

The left adrenal gland is normal in shape, echogenic appearance, size, position, and appearance of the visible peri-adrenal vasculature. Left adrenal gland measured 0.3 cm in width. The right adrenal gland was not clearly visualized, but appears to be of normal shape, echogenic appearance and size.

Spleen

Normal size and echogenic appearance. Smooth homogenous parenchyma and regular curvilinear capsule. Normal volume of the splenic vasculature without any overt congestion or thrombosis evident. No inflammatory, neoplastic, infarction, or infiltrative changes evident. The spleen measured 0.7 cm in width.

Liver

Normal size, echogenic appearance, portal markings, and regular curvilinear capsule. No nodules or masses evident. Normal appearance of the hepatic and portal vasculature.



PATIENT

Sven Thomas

SPECIES

Feline

BREED

Domestic Shorthair

SEX

Intact male

AGE

9 ½ years

WEIGHT

15.1 lbs

INTERPRETED BY

Remo Lobetti, BVSc,
MMedVet (Med),
PhD, Dipl. ECVIM

IMAGING PERFORMED BY

Dr. Arms

HOSPITAL NAME

Gilbertsville VH

REFERRING VET

Dr. Arms

INVOICE

74046

DATE

4/2/26

Gallbladder

The gallbladder is full containing normal anechoic bile. Normal thickness and echogenic appearance of the wall. Normal size and appearance of the cystic and common bile duct.

Gastrointestinal

Normal appearance of the stomach, duodenum, ileo-cecal junction, and colon with no loss of layering, 1:3 muscularis to mucosa ratio, normal wall thickness and peristaltic activity, and no distension of the lumen. Normal thickness of the small intestine (up to 0.3 cm) with no loss of layering, but with a segmental increase in the muscularis to mucosa ratio, normal peristaltic activity and no distension of the lumen. A moderate amount of ingesta is present in the stomach.

Pancreas

The visible sections of the pancreas are of normal size and echogenic appearance with a regular capsule. Normal echogenic appearance of the mesentery and fat surrounding the pancreas.

Free Abdomen

Normal mesenteric lymph nodes.

No ascites evident.

ULTRASONOGRAPHIC FINDINGS

- Enteropathy.

INTERPRETATION OF THE FINDINGS & FURTHER RECOMMENDATIONS

The ingesta present in the stomach may either present a recent meal or possibly delayed gastric emptying.

Etiologies for the enteropathy would be parasitic enteritis, dietary hypersensitivity and inflammatory bowel disease.

Emerging lymphoma would be a highly unlikely differential diagnosis.

Further assessment would be fecal analysis, cobalamin and folate assay and endoscopy of the upper GI tract with biopsies.

Specific therapy would be dependent on an etiological diagnosis.

Symptomatic management that can be considered would be feeding small frequent meals of a novel protein/hypoallergenic diet, course of Fenbendazole, cobalamin supplementation, antiemetics and if there is still not a satisfactory improvement then a course of Prednisolone would then be indicated.



PATIENT

Sven Thomas

SPECIES

Feline

BREED

Domestic Shorthair

SEX

Intact male

AGE

9½ years

WEIGHT

15.1 lbs

INTERPRETED BY

Remo Lobetti, BVSc,
MMedVet (Med),
PhD, Dipl. ECVIM

IMAGING PERFORMED BY

Dr. Arms

HOSPITAL NAME

Gilbertsville VH

REFERRING VET

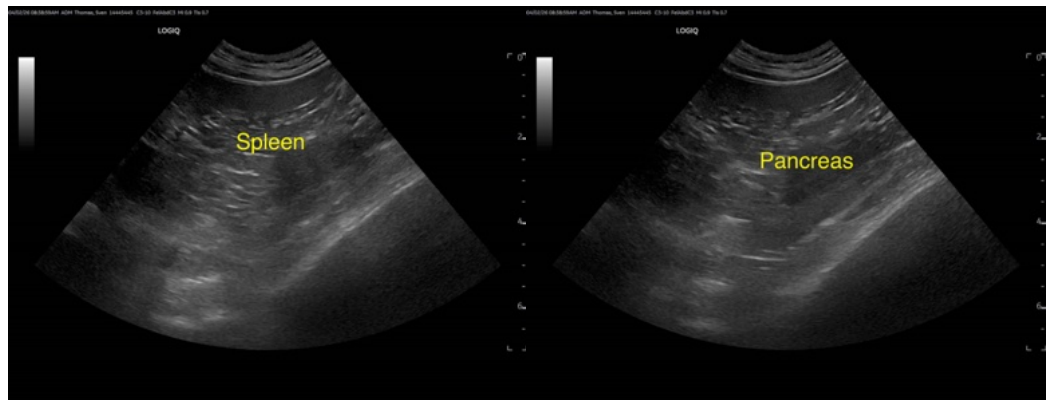
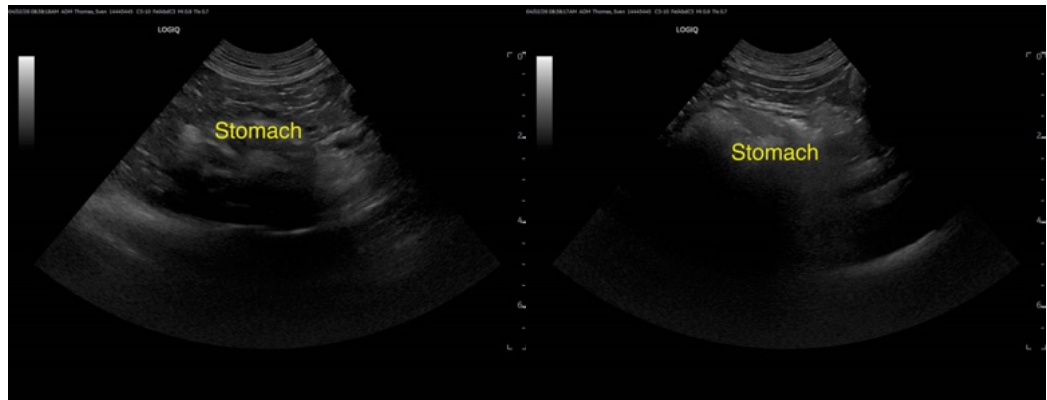
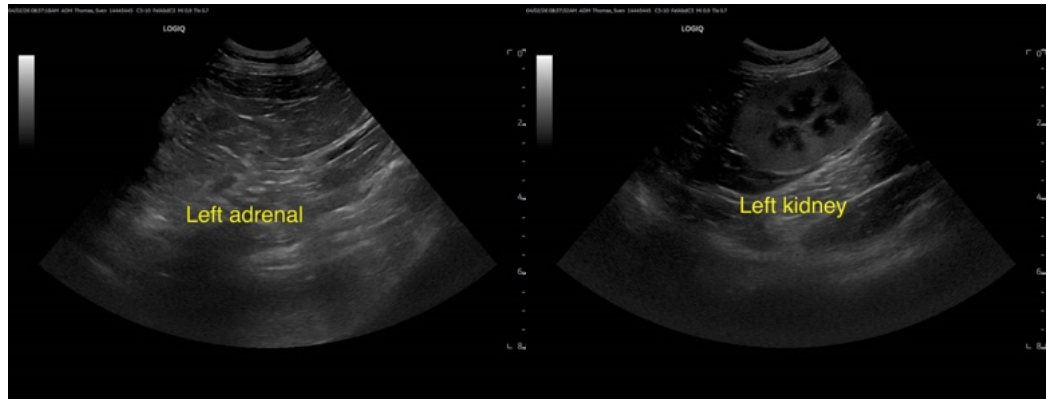
Dr. Arms

INVOICE

74046

DATE

4/2/26





PATIENT

Sven Thomas

SPECIES

Feline

BREED

Domestic Shorthair

SEX

Intact male

AGE

9 ½ years

WEIGHT

15.1 lbs

INTERPRETED BY

Remo Lobetti, BVSc,
MMedVet (Med),
PhD, Dipl. ECVIM

IMAGING PERFORMED BY

Dr. Arms

HOSPITAL NAME

Gilbertsville VH

REFERRING VET

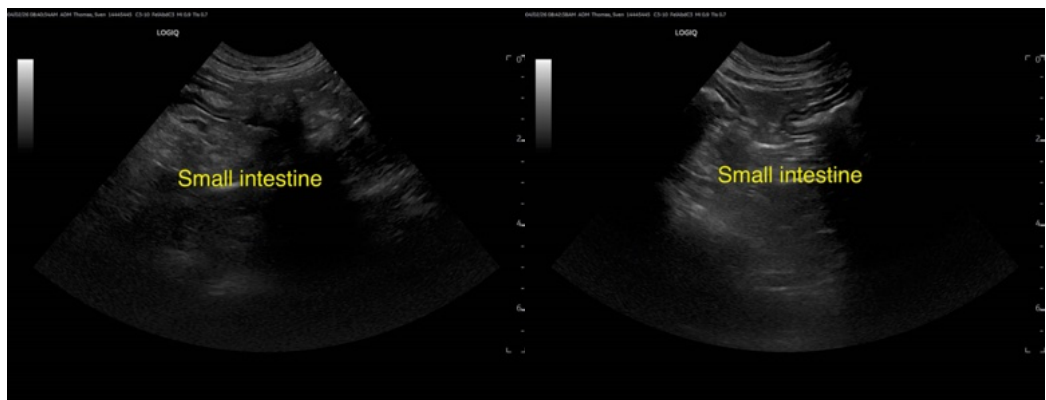
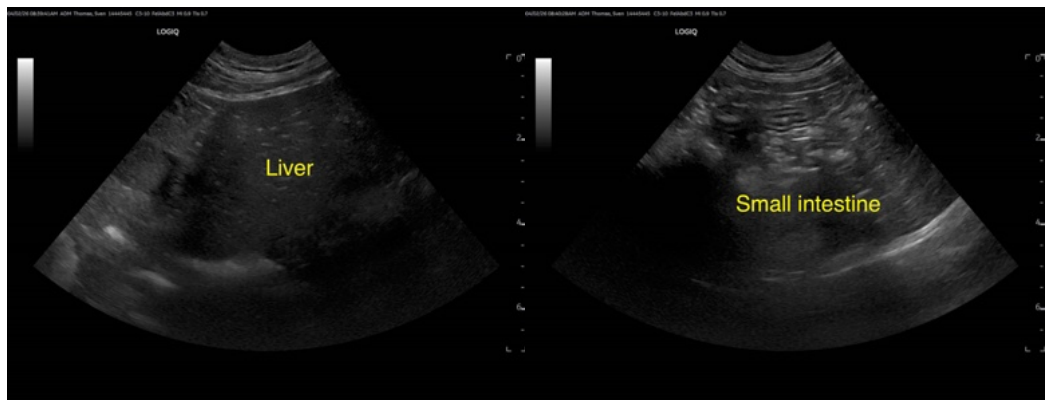
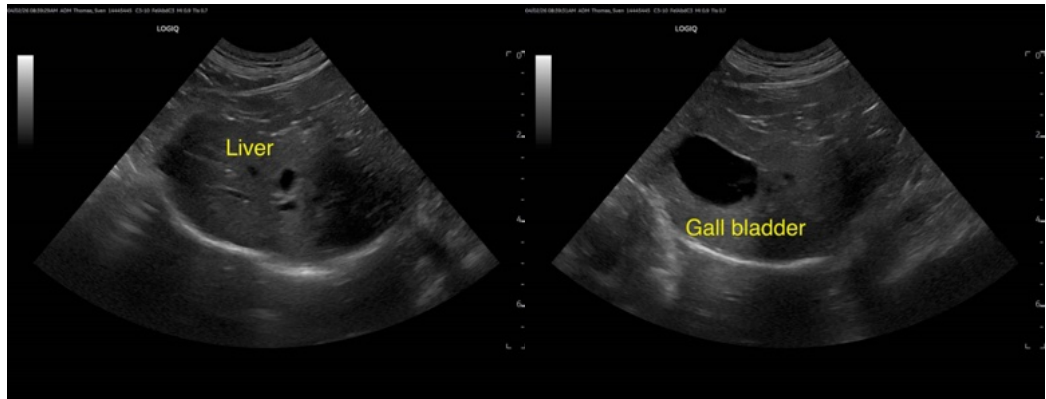Dr. Arms

INVOICE

74046

DATE

4/2/26



The information and recommendations provided are based on the images presented by the referring veterinarian/sonographer. No evaluation can be communicated regarding pathology that was not visible in the image/video clips provided.

Thank you for this referral. If the clinical or image interpretation does not parallel your findings or if I can be of any further assistance please contact me.

Remo Lobetti, BVSc, MMedVet (Med), PhD, Dipl. ECVIM (Internal Medicine)

info@sonopath.com