

PATIENT

Pumpkin DeJesus

SPECIES

Canine

BREED

French Bulldog

SEX

Spayed female

AGE

2018

WEIGHT

22 lbs

INTERPRETED BY

Remo Lobetti, BVSc,
MMedVet (Med), PhD,
Dipl. ECVIM (Internal
Medicine)

IMAGING PERFORMED BY

Denise Bruno, LVT,
RDMS

HOSPITAL NAME

Ideal Pet Vet Clinic

REFERRING VET

Dr. Kolta

INVOICE

74555

DATE

4/9/26

PRESENTING CLINICAL SIGNS

History: UTI's - Treated several times with antibiotics. UAs attached

ULTRASONOGRAPHIC EXAMINATION OF THE ABDOMEN

Urinary System

The urinary bladder is full with a normal thickness and smooth appearance of the wall. Normal anechoic urine with no sediment or uroliths evident.

Normal appearance of the trigone area, proximal urethra (0.3 cm), and iliac blood vessels.

Normal appearance and size of the iliac lymph nodes. Ureters not visualized, which can be considered a normal finding.

Normal renal size, architecture, echogenic appearance, cortico-medullary differentiation, which maintains a 1:3 cortex to medulla ratio, pelvis, and capsule. No infarcts, mineralization or renoliths evident. The left kidney measured 4.2 cm. The right kidney measured 4.4 cm. Normal color flow pattern is evident in both kidneys.

Adrenal Glands

Normal shape, echogenic appearance, size, position, and appearance of the visible peri-adrenal vasculature. The left adrenal gland measured 2.01 cm in length x 0.64 cm and 0.44 cm in width. The right adrenal gland measured 1.72 cm in length x 0.62 cm in width.

Spleen

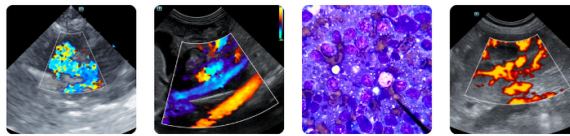
Normal size and echogenic appearance. Smooth homogenous parenchyma and regular curvilinear capsule. Normal volume of the splenic vasculature without any overt congestion or thrombosis evident. No inflammatory, neoplastic, infarction, or infiltrative changes evident. The spleen measured 1.3 cm in width.

Liver

Normal size, echogenic appearance, portal markings, and regular curvilinear capsule. No nodules or masses evident. Normal appearance of the hepatic and portal vasculature.

Gallbladder

The gallbladder is full containing a small amount of non-adhered, hyperechogenic sediment. Normal thickness and echogenic appearance of the wall. Normal size and appearance of the cystic and common bile duct.



PATIENT

Pumpkin DeJesus

SPECIES

Canine

BREED

French Bulldog

SEX

Spayed female

AGE

2018

WEIGHT

22 lbs

INTERPRETED BY

Remo Lobetti, BVSc,
MMedVet (Med), PhD,
Dipl. ECVIM (Internal
Medicine)

**IMAGING
PERFORMED BY**

Denise Bruno, LVT,
RDMS

HOSPITAL NAME

Ideal Pet Vet Clinic

REFERRING VET

Dr. Kolta

INVOICE

74555

DATE

4/9/26

Gastrointestinal

Normal appearance of the stomach, duodenum, small intestine, ileo-cecal junction, and colon with no loss of layering, 1:3 muscularis to mucosa ratio, normal wall thickness and peristaltic activity, and no distension of the lumen. Small intestine measured 0.42 cm.

Pancreas

The visible sections of the pancreas are of normal size and echogenic appearance with a regular capsule. Normal echogenic appearance of the mesentery and fat surrounding the pancreas.

Free Abdomen

Normal mesenteric lymph nodes.

No ascites evident.

ULTRASONOGRAPHIC FINDINGS

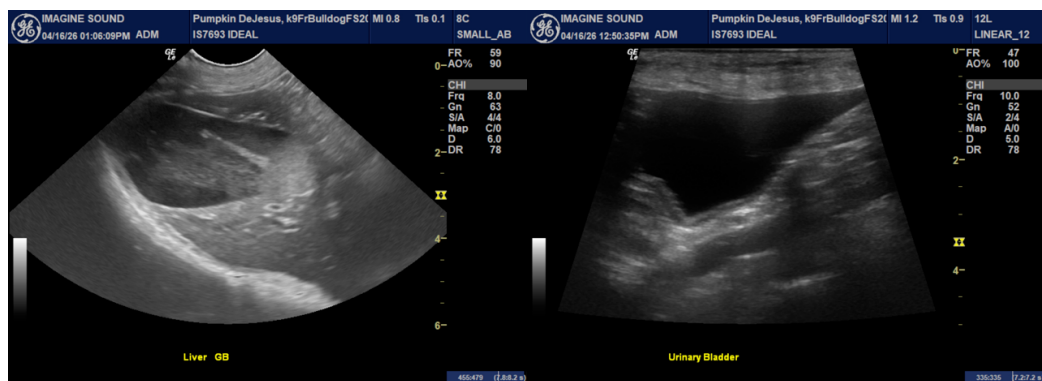
- Gallbladder sediment.

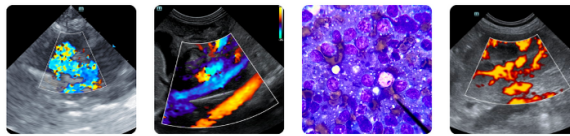
INTERPRETATION OF THE FINDINGS & FURTHER RECOMMENDATIONS

In essence this is a normal ultrasound examination of the abdomen as the gallbladder sediment can be considered an incidental finding.

On this ultrasound there is no obvious etiology for the recurrent urinary tract infections.

Management of the recurrent urinary tract infection would be an extended course of antibiotics (3-4 weeks) based on urine culture and sensitivity results with urinalysis repeated 24-hours after completion of the antibiotics as well as 7 days later to ensure eradication of the infection.





PATIENT

Pumpkin DeJesus

SPECIES

Canine

BREED

French Bulldog

SEX

Spayed female

AGE

2018

WEIGHT

22 lbs

INTERPRETED BY

Remo Lobetti, BVSc,
MMedVet (Med), PhD,
Dipl. ECVIM (Internal
Medicine)

IMAGING PERFORMED BY

Denise Bruno, LVT,
RDMS

HOSPITAL NAME

Ideal Pet Vet Clinic

REFERRING VET

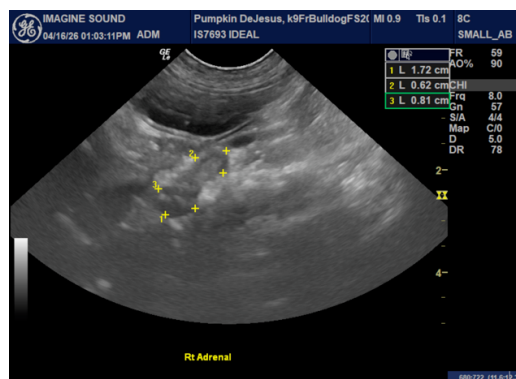
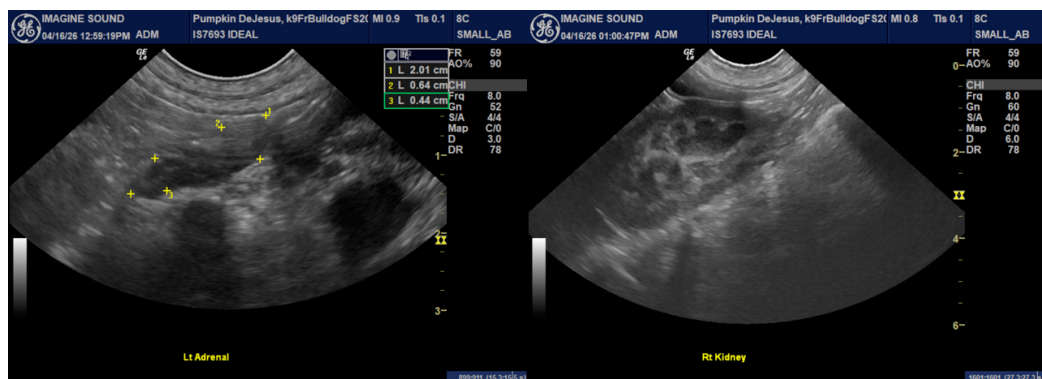
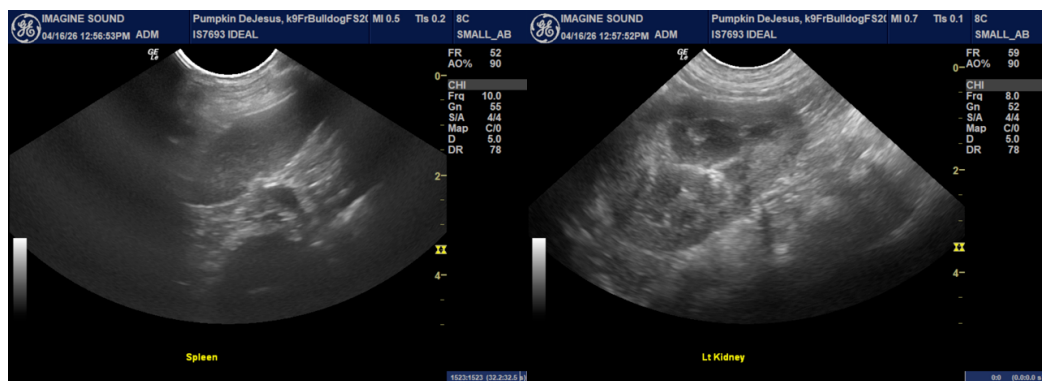
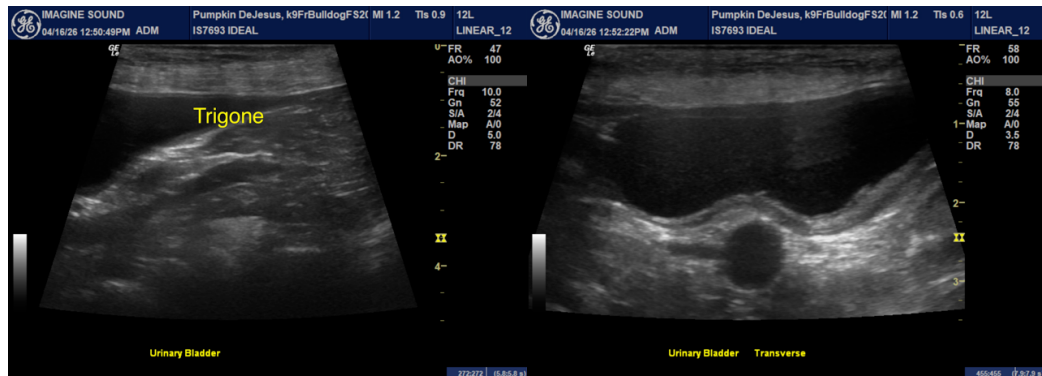
Dr. Kolta

INVOICE

74555

DATE

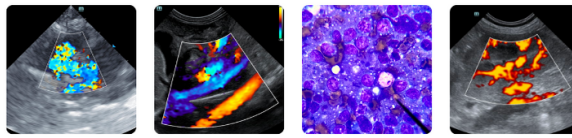
4/9/26



Imaging
performed by



dbimagesound@gmail.com
917-647-4318



Clinical Sonography & Telectytology
Educational Teleconsultation Services™

SonoPath

FOSTERING THE ART OF VETERINARY MEDICINE™

SonoPath.com info@sonopath.com 1.800.838.4268

PATIENT

Pumpkin DeJesus

SPECIES

Canine

BREED

French Bulldog

SEX

Spayed female

AGE

2018

WEIGHT

22 lbs

INTERPRETED BY

Remo Lobetti, BVSc,
MMedVet (Med), PhD,
Dipl. ECVIM (Internal
Medicine)

**IMAGING
PERFORMED BY**

Denise Bruno, LVT,
RDMS

HOSPITAL NAME

Ideal Pet Vet Clinic

REFERRING VET

Dr. Kolta

INVOICE

74555

DATE

4/9/26

The information and recommendations provided are based on the images presented by the referring veterinarian/sonographer. No evaluation can be communicated regarding pathology that was not visible in the image/video clips provided.

Thank you for this referral. If the clinical or image interpretation does not parallel your findings or if I can be of any further assistance please contact me.

Remo Lobetti, BVSc, MMedVet (Med), PhD, Dipl. ECVIM (Internal Medicine)

info@sonopath.com