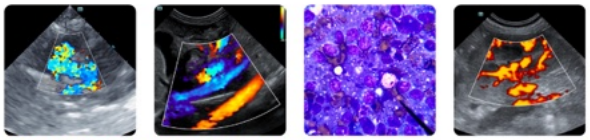

PATIENT
Dexter Carlile

SPECIES
Canine

BREED
Bloodhound Mix

SEX
Neutered male

AGE
12 years

WEIGHT
78.6 lbs

INTERPRETED BY
Remo Lobetti, BVSc, MMedVet (Med), PhD, Dipl. ECVIM

IMAGING PERFORMED BY
Dr. Bray

HOSPITAL NAME
Taylorsville VC

REFERRING VET
Dr. Bisset

INVOICE
74543

DATE
4/16/26

PRESENTING CLINICAL SIGNS

History: Dexter is a 12-year-old male neutered Bloodhound mix presenting for evaluation of gastrointestinal upset after consuming cooked rib bones. Dexter had one episode of vomiting after eating his meal too quickly and has diarrhea since Sunday morning. His appetite has been poor but energy levels normal.
Abnormal PE/Chem/CBC/UA Results: Incidental abdominal mass found on abdominal radiographs - suspect from tail of the spleen. Serosal detail is good so does not appear to be actively bleeding. BW: ALP 4,517 H, PSL 458 H, PLT 423 H, T4 <0.5 L. Urine USH 1.008, Pro 3+, UPC 4.9 See attached Sonopath report from 2023

ULTRASONOGRAPHIC EXAMINATION OF THE ABDOMEN

Urinary System

The urinary bladder is full with a normal thickness and smooth appearance of the wall. Normal anechoic urine with no sediment or uroliths evident.

Normal appearance of the trigone area, proximal urethra, and iliac blood vessels.

Normal appearance and size of the iliac lymph nodes. Ureters not visualized, which can be considered a normal finding.

Normal renal size (left measured 7.0 cm, right measured 7.4 cm), architecture, echogenic appearance, cortico-medullary differentiation, which maintains a 1:3 cortex to medulla ratio, pelvis, and capsule. No infarcts, mineralization or renoliths evident. Bilateral, incidental small cortical cysts are present. Normal color flow pattern is evident in both kidneys.

The prostate is small and hypoechogenic.

Adrenal Glands

Normal shape, echogenic appearance, size, position, and appearance of the visible peri-adrenal vasculature. Left adrenal gland measured 0.78 cm and 0.73 cm in width. The right adrenal gland measured 0.78 cm in width.

Spleen

Normal size and echogenic appearance. Smooth homogenous parenchyma and regular curvilinear capsule. Normal volume of the splenic vasculature without any overt congestion or thrombosis evident. No inflammatory, neoplastic, infarction, or infiltrative changes evident. The spleen measured 1.9 cm in width.

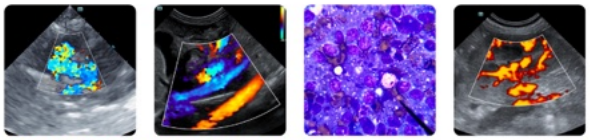

PATIENT

Dexter Carlile

SPECIES

Canine

BREED

Bloodhound Mix

SEX

Neutered male

AGE

12 years

WEIGHT

78.6 lbs

INTERPRETED BY

Remo Lobetti, BVSc, MMedVet (Med), PhD, Dipl. ECVIM

IMAGING PERFORMED BY

Dr. Bray

HOSPITAL NAME

Taylorsville VC

REFERRING VET

Dr. Bisset

INVOICE

74543

DATE

4/16/26

Liver

Normal size with a diffuse increased echogenic and coarse appearance, normal portal markings, and regular curvilinear capsule. No nodules are evident. Large, isoechogenic to mildly hyperechogenic appearance in the right lobe measuring 5 x 9 cm in size. No additional masses are evident. Normal appearance of the hepatic and portal vasculature.

Gallbladder

The gallbladder is full containing normal anechoic bile. Normal thickness and echogenic appearance of the wall. Normal size and appearance of the cystic and common bile duct.

Gastrointestinal

Normal appearance of the stomach, duodenum, small intestine, ileo-cecal junction, and colon with no loss of layering, 1:3 muscularis to mucosa ratio, normal wall thickness and peristaltic activity, and no distension of the lumen.

Pancreas

The visible sections of the pancreas are of normal size and echogenic appearance with a regular capsule. Normal echogenic appearance of the mesentery and fat surrounding the pancreas.

Free Abdomen

Normal mesenteric lymph nodes.

No ascites evident.

ULTRASONOGRAPHIC FINDINGS

- Hepatic mass.
- Hepatopathy.

INTERPRETATION OF THE FINDINGS & FURTHER RECOMMENDATIONS

Etiologies for the hepatic mass would be hepatoma, and possibly primary hepatocellular carcinoma.

Etiologies for the hepatopathy would be reactive hyperplasia, early nodular hyperplasia, vacuolar and metabolic.

Although the pancreas appears ultrasonographically normal, with the elevated PSL asctivity, pancreatitis should still be considered. However, an important differential diagnosis would be that the elevated PSL activity is secodanry to the gastroenteritis.

PATIENT

Dexter Carlile

SPECIES

Canine

BREED

Bloodhound Mix

SEX

Neutered male

AGE

12 years

WEIGHT

78.6 lbs

INTERPRETED BY

Remo Lobetti, BVSc, MMedVet (Med), PhD, Dipl. ECVIM

IMAGING PERFORMED BY

Dr. Bray

HOSPITAL NAME

Taylorsville VC

REFERRING VET

Dr. Bisset

INVOICE

74543

DATE

4/16/26

Further assessment would be FNA cytology of the liver and hepatic mass. However, a tru cut or wedge biopsy may be required for a final etiological diagnosis.

Specific therapy would be dependent on an etiological diagnosis.

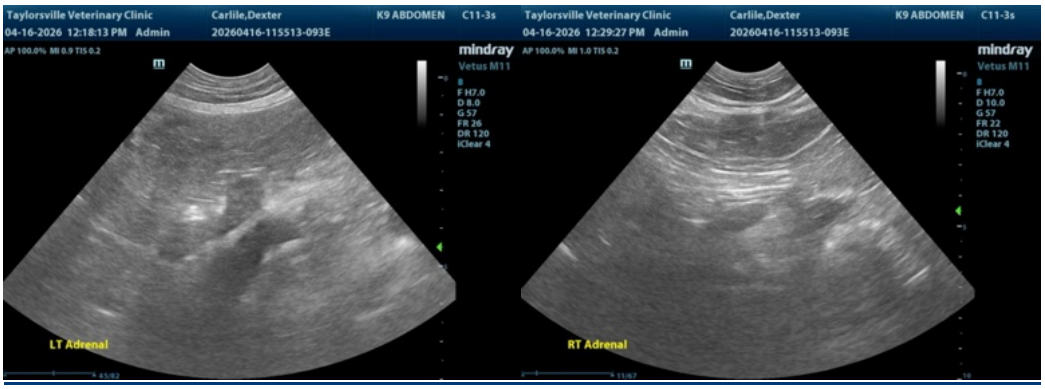

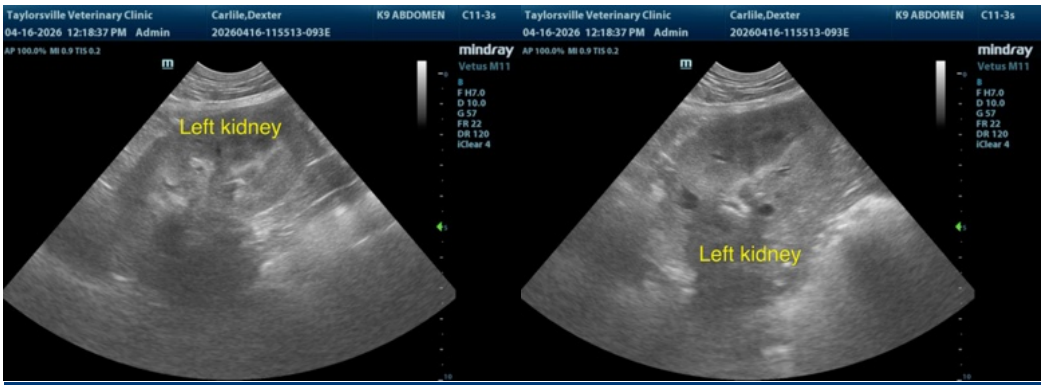

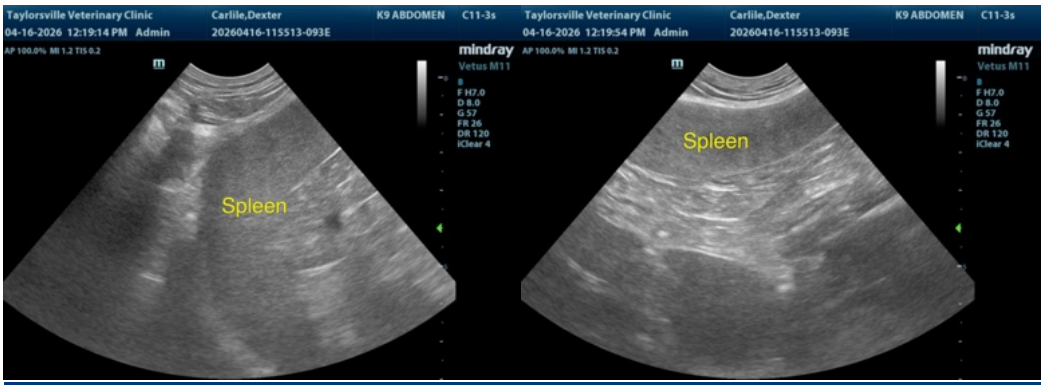

SonoPath
FOSTERING THE ART OF VETERINARY MEDICINE™

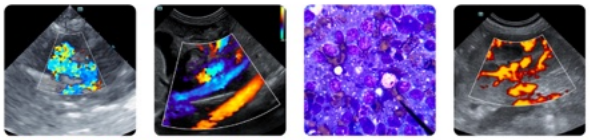

Clinical Sonography & Telecytology
Educational Teleconsultation Services™

SonoPath.com info@sonopath.com 1.800.838.4268

PATIENT

Dexter Carlile

SPECIES

Canine

BREED

Bloodhound Mix

SEX

Neutered male

AGE

12 years

WEIGHT

78.6 lbs

INTERPRETED BY

Remo Lobetti, BVSc, MMedVet (Med), PhD, Dipl. ECVIM

IMAGING PERFORMED BY

Dr. Bray

HOSPITAL NAME

Taylorsville VC

REFERRING VET

Dr. Bisset

INVOICE

74543

DATE

4/16/26

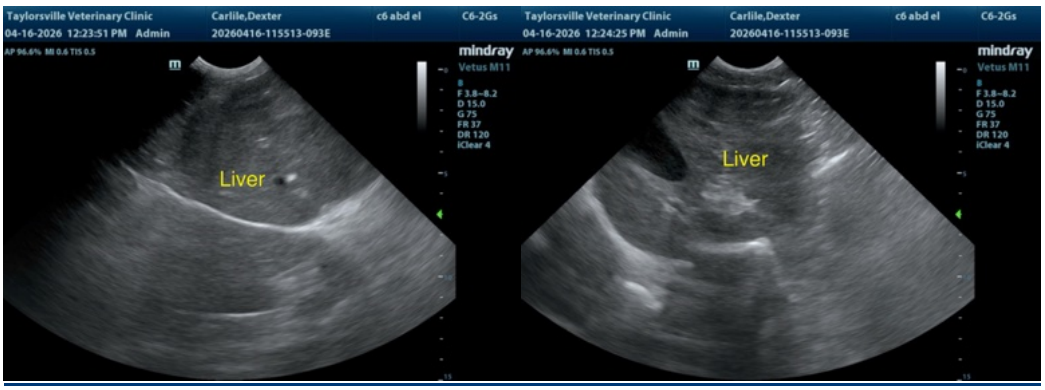

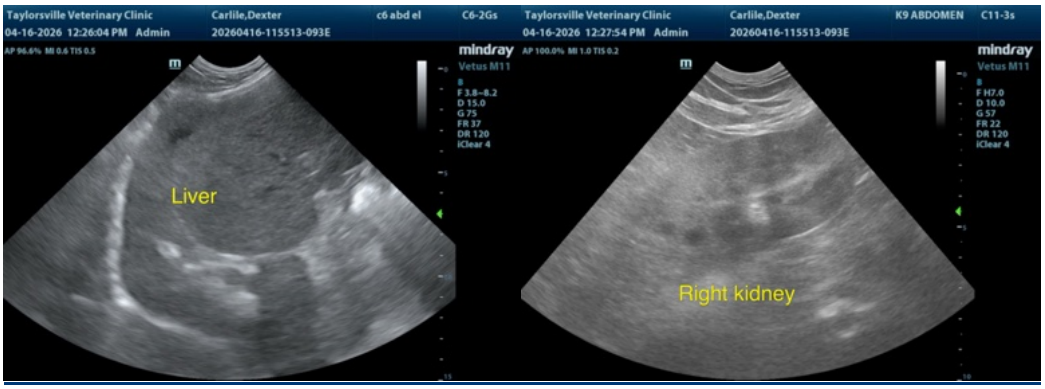

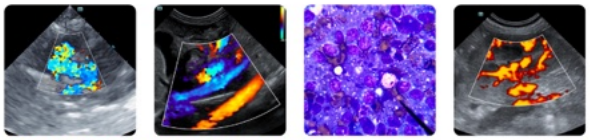

PATIENT

Dexter Carlile

SPECIES

Canine

BREED

Bloodhound Mix

SEX

Neutered male

AGE

12 years

WEIGHT

78.6 lbs

INTERPRETED BY

Remo Lobetti, BVSc, MMedVet (Med), PhD, Dipl. ECVIM

IMAGING PERFORMED BY

Dr. Bray

HOSPITAL NAME

Taylorsville VC

REFERRING VET

Dr. Bisset

INVOICE

74543

DATE

4/16/26

The information and recommendations provided are based on the images presented by the referring veterinarian/sonographer. No evaluation can be communicated regarding pathology that was not visible in the image/video clips provided.

Thank you for this referral. If the clinical or image interpretation does not parallel your findings or if I can be of any further assistance please contact me.

Remo Lobetti, BVSc, MMedVet (Med), PhD, Dipl. ECVIM (Internal Medicine)

info@sonopath.com