



PATIENT

Nellie Housley

SPECIES

Canine

BREED

Chesapeake Bay
Retriever

SEX

Spayed female

AGE

11 years

WEIGHT

67 lbs

INTERPRETED BY

Remo Lobetti, BVSc,
MMedVet (Med),
PhD, Dipl. ECVIM

IMAGING PERFORMED BY

Nikki Wright

HOSPITAL NAME

Bush AH

REFERRING VET

Dr. Wright

INVOICE

74493

DATE

4/15/26

PRESENTING CLINICAL SIGNS

History: Urinary incontinence and PU/PD. Vulvitis and perivulvar dermatitis – improved. Buccal mucosa black growth left upper lip. OS eyelid margin swellings.

Nuclear sclerosis. Dental grade 2/4

Abnormal PE/Chem/CBC/UA Results: - K 3.8, CREA 1.3, SDMA 14, USG 1.013 - BP eval today (on traz/gaba); avg 172 systolic

ULTRASONOGRAPHIC EXAMINATION OF THE ABDOMEN

Urinary System

The urinary bladder is full with a normal thickness and smooth appearance of the wall. Normal anechoic urine with no sediment or uroliths evident.

Normal appearance of the trigone area, proximal urethra, and iliac blood vessels.

Normal appearance and size of the iliac lymph nodes. Ureters not visualized, which can be considered a normal finding.

Normal renal size (left measured 6.1 cm, right measured 6.0 cm), architecture, echogenic appearance, cortico-medullary differentiation, which maintains a 1:3 cortex to medulla ratio, pelvis, and capsule. No infarcts, mineralization or renoliths evident. Normal color flow pattern is evident in both kidneys.

Adrenal Glands

Normal shape, echogenic appearance, size, position, and appearance of the visible peri-adrenal vasculature. Left adrenal gland measured 0.62 cm in width. The right adrenal gland measured 0.54 cm and 0.45 cm in width.

Spleen

Normal size and echogenic appearance. Smooth homogenous parenchyma and regular curvilinear capsule. Normal volume of the splenic vasculature without any overt congestion or thrombosis evident. No inflammatory, neoplastic, infarction, or infiltrative changes evident. The spleen measured 2.1 cm in width.

Liver

Normal size, echogenic appearance, portal markings, and regular curvilinear capsule. No nodules or masses evident. Normal appearance of the hepatic and portal vasculature.

Gallbladder

The gallbladder is full containing normal anechoic bile. Normal thickness and echogenic appearance of the wall. Normal size and appearance of the cystic and common bile duct.



PATIENT

Nellie Housley

SPECIES

Canine

BREED

Chesapeake Bay
Retriever

SEX

Spayed female

AGE

11 years

WEIGHT

67 lbs

INTERPRETED BY

Remo Lobetti, BVSc,
MMedVet (Med),
PhD, Dipl. ECVIM

IMAGING PERFORMED BY

Nikki Wright

HOSPITAL NAME

Bush AH

REFERRING VET

Dr. Wright

INVOICE

74493

DATE

4/15/26

Gastrointestinal

Normal appearance of the stomach, duodenum, small intestine, ileo-cecal junction, and colon with no loss of layering, 1:3 muscularis to mucosa ratio, normal wall thickness and peristaltic activity, and no distension of the lumen.

Pancreas

Normal size and echogenic appearance with a regular capsule. Normal echogenic appearance of the mesentery and fat surrounding the pancreas.

Free Abdomen

Normal mesenteric lymph nodes.

No ascites evident.

ULTRASONOGRAPHIC FINDINGS

- Normal ultrasound examination of the abdomen.

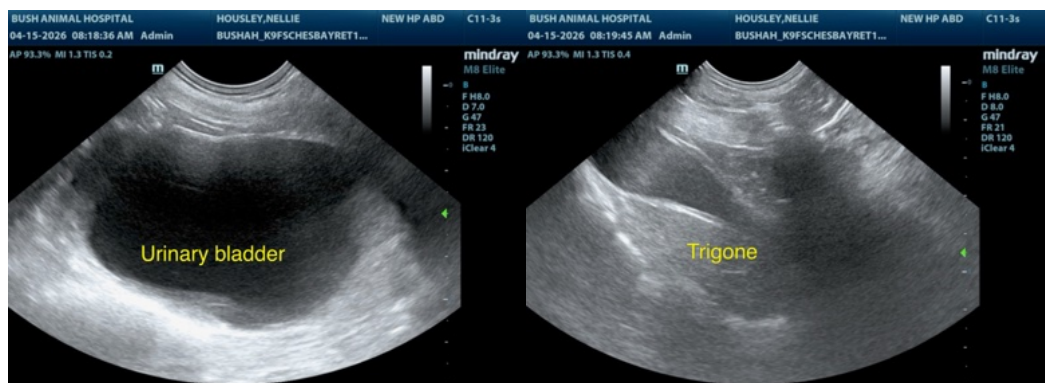
INTERPRETATION OF THE FINDINGS & FURTHER RECOMMENDATIONS

On this ultrasound there is no obvious etiology for the presenting clinical signs.

Possible etiologies for the presenting clinical signs would be low-grade bacterial cystitis, urethral pathology or owner misinterpretation of urinary incontinence with pollakiuria associated with perivulvar dermatitis.

Further assessment would be urine culture and possibly contrast urethrogram.

Specific therapy would be dependent on an etiological diagnosis.





PATIENT

Nellie Housley

SPECIES

Canine

BREED

Chesapeake Bay
Retriever

SEX

Spayed female

AGE

11 years

WEIGHT

67 lbs

INTERPRETED BY

Remo Lobetti, BVSc,
MMedVet (Med),
PhD, Dipl. ECVIM

**IMAGING
PERFORMED BY**

Nikki Wright

HOSPITAL NAME

Bush AH

REFERRING VET

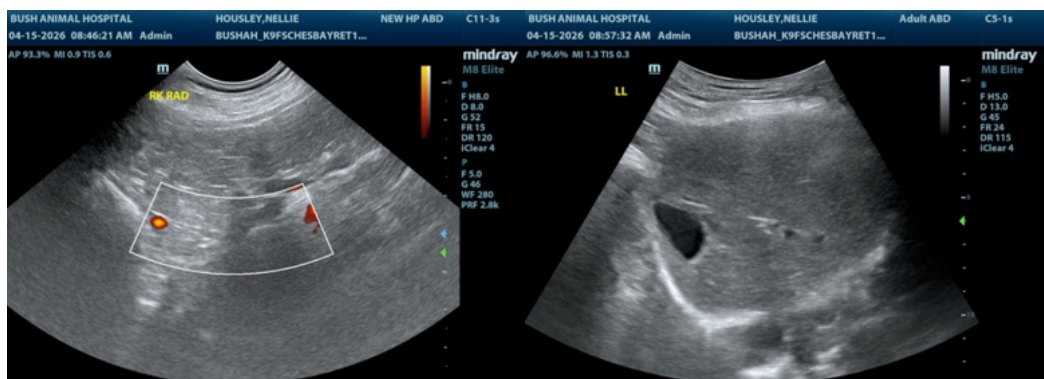
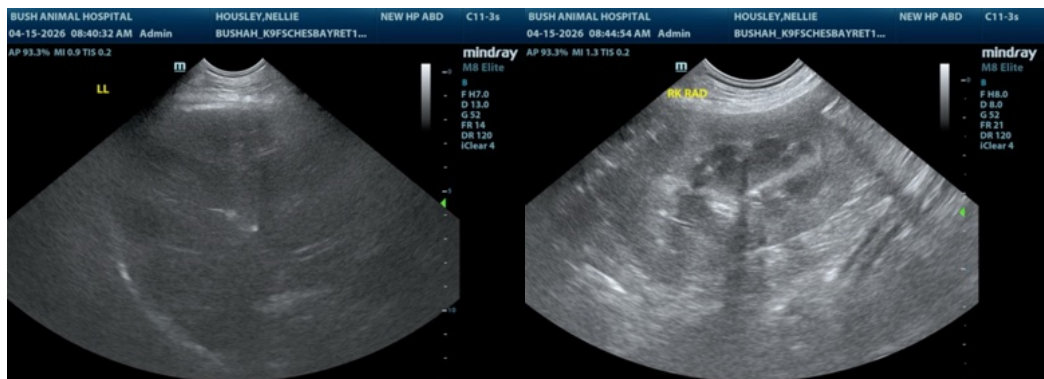
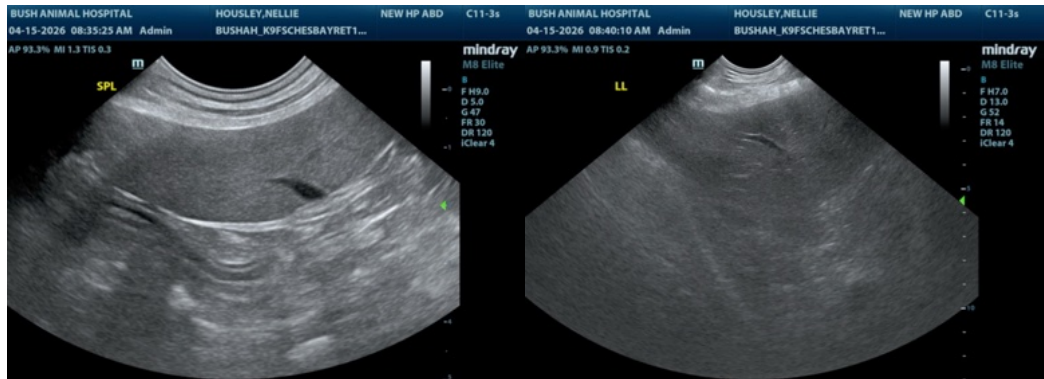
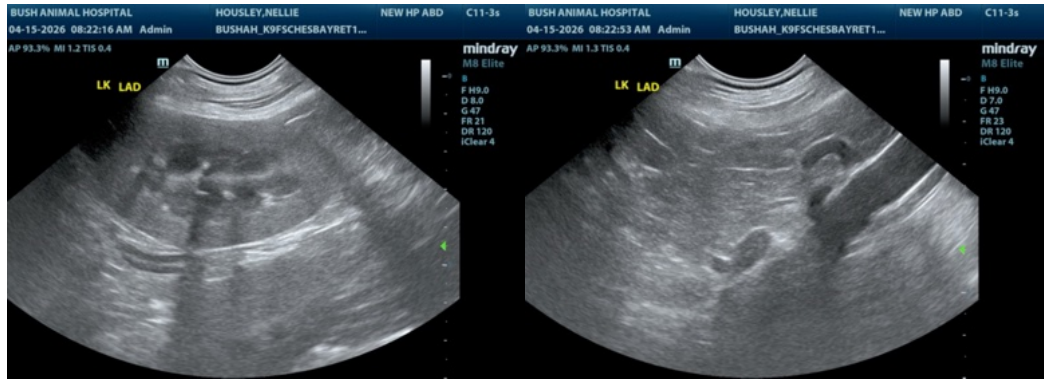
Dr. Wright

INVOICE

74493

DATE

4/15/26





PATIENT

Nellie Housley

SPECIES

Canine

BREED

Chesapeake Bay
Retriever

SEX

Spayed female

AGE

11 years

WEIGHT

67 lbs

INTERPRETED BY

Remo Lobetti, BVSc,
MMedVet (Med),
PhD, Dipl. ECVIM

IMAGING PERFORMED BY

Nikki Wright

HOSPITAL NAME

Bush AH

REFERRING VET

Dr. Wright

INVOICE

74493

DATE

4/15/26

The information and recommendations provided are based on the images presented by the referring veterinarian/sonographer. No evaluation can be communicated regarding pathology that was not visible in the image/video clips provided.

Thank you for this referral. If the clinical or image interpretation does not parallel your findings or if I can be of any further assistance please contact me.

Remo Lobetti, BVSc, MMedVet (Med), PhD, Dipl. ECVIM (Internal Medicine)

info@sonopath.com