



## PATIENT

Atticus Kuhns

## SPECIES

Canine

## BREED

German Shepherd

## SEX

Neutered male

## AGE

11 years

## WEIGHT

86.2 lbs

## INTERPRETED BY

Remo Lobetti, BVSc,  
MMedVet (Med),  
PhD, Dipl. ECVIM

## IMAGING PERFORMED BY

Amanda Hockenbrock

## HOSPITAL NAME

Lewisburg VH

## REFERRING VET

Dr. Vincent

## INVOICE

74399

## DATE

4/13/26

## PRESENTING CLINICAL SIGNS

History: P was diagnosed with oral Hemangiosarcoma in mid January 2026. Patient is currently undergoing Chemotherapy. Oncologist has requested abdominal scans between every other treatment for monitoring.

## ULTRASONOGRAPHIC EXAMINATION OF THE ABDOMEN

### *Urinary System*

The urinary bladder is small with a normal thickness and smooth appearance of the wall. Normal anechoic urine with no sediment or uroliths evident.

Normal appearance of the trigone area and iliac blood vessels. The proximal urethra was not visualized.

Normal appearance and size of the iliac lymph nodes. Ureters not visualized, which can be considered a normal finding.

Normal renal size (left measured 6.1 cm, right measured 7.1 cm), architecture, echogenic appearance, cortico-medullary differentiation, which maintains a 1:3 cortex to medulla ratio, pelvis, and capsule. No infarcts, mineralization or renoliths evident.

The prostate is not visualized.

### *Adrenal Glands*

The left adrenal gland is normal in shape, echogenic appearance, size, position, and appearance of the visible peri-adrenal vasculature. Left adrenal gland measured 2.1 cm in length x 0.45 cm and 0.43 cm in width. The right adrenal gland was not clearly visualized, but appears to be of normal shape, echogenic appearance and size.

### *Spleen*

Normal size and echogenic appearance. Smooth homogenous parenchyma and regular curvilinear capsule. Normal volume of the splenic vasculature without any overt congestion or thrombosis evident. No inflammatory, neoplastic, infarction, or infiltrative changes evident. The spleen measured 2.2 cm in width.

### *Liver*

Normal size, echogenic appearance, portal markings, and regular curvilinear capsule. No nodules or masses evident. Normal appearance of the hepatic and portal vasculature.



## PATIENT

Atticus Kuhns

## SPECIES

Canine

## BREED

German Shepherd

## SEX

Neutered male

## AGE

11 years

## WEIGHT

86.2 lbs

## INTERPRETED BY

Remo Lobetti, BVSc,  
MMedVet (Med),  
PhD, Dipl. ECVIM

## IMAGING PERFORMED BY

Amanda Hockenbrock

## HOSPITAL NAME

Lewisburg VH

## REFERRING VET

Dr. Vincent

## INVOICE

74399

## DATE

4/13/26

## Gallbladder

The gallbladder is full containing normal anechoic bile. Normal thickness and echogenic appearance of the wall. Normal size and appearance of the cystic and common bile duct.

## Gastrointestinal

Normal appearance of the stomach, duodenum, small intestine, ileo-cecal junction, and colon with no loss of layering, 1:3 muscularis to mucosa ratio, normal wall thickness and peristaltic activity, and no distension of the lumen.

## Pancreas

The visible sections of the pancreas are of normal size and echogenic appearance with a regular capsule. Normal echogenic appearance of the mesentery and fat surrounding the pancreas.

## Free Abdomen

Normal mesenteric lymph nodes.

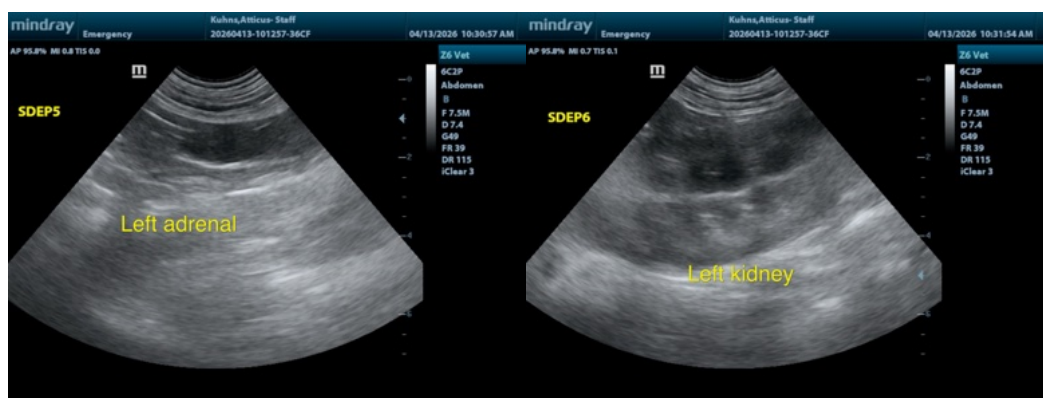
No ascites evident.

## ULTRASONOGRAPHIC FINDINGS

- Normal ultrasound examination of the abdomen.

## INTERPRETATION OF THE FINDINGS & FURTHER RECOMMENDATIONS

On this ultrasound there is no obvious evidence of metastatic neoplasia.





**PATIENT**

Atticus Kuhns

**SPECIES**

Canine

**BREED**

German Shepherd

**SEX**

Neutered male

**AGE**

11 years

**WEIGHT**

86.2 lbs

**INTERPRETED BY**

Remo Lobetti, BVSc,  
MMedVet (Med),  
PhD, Dipl. ECVIM

**IMAGING  
PERFORMED BY**

Amanda Hockenbrock

**HOSPITAL NAME**

Lewisburg VH

**REFERRING VET**

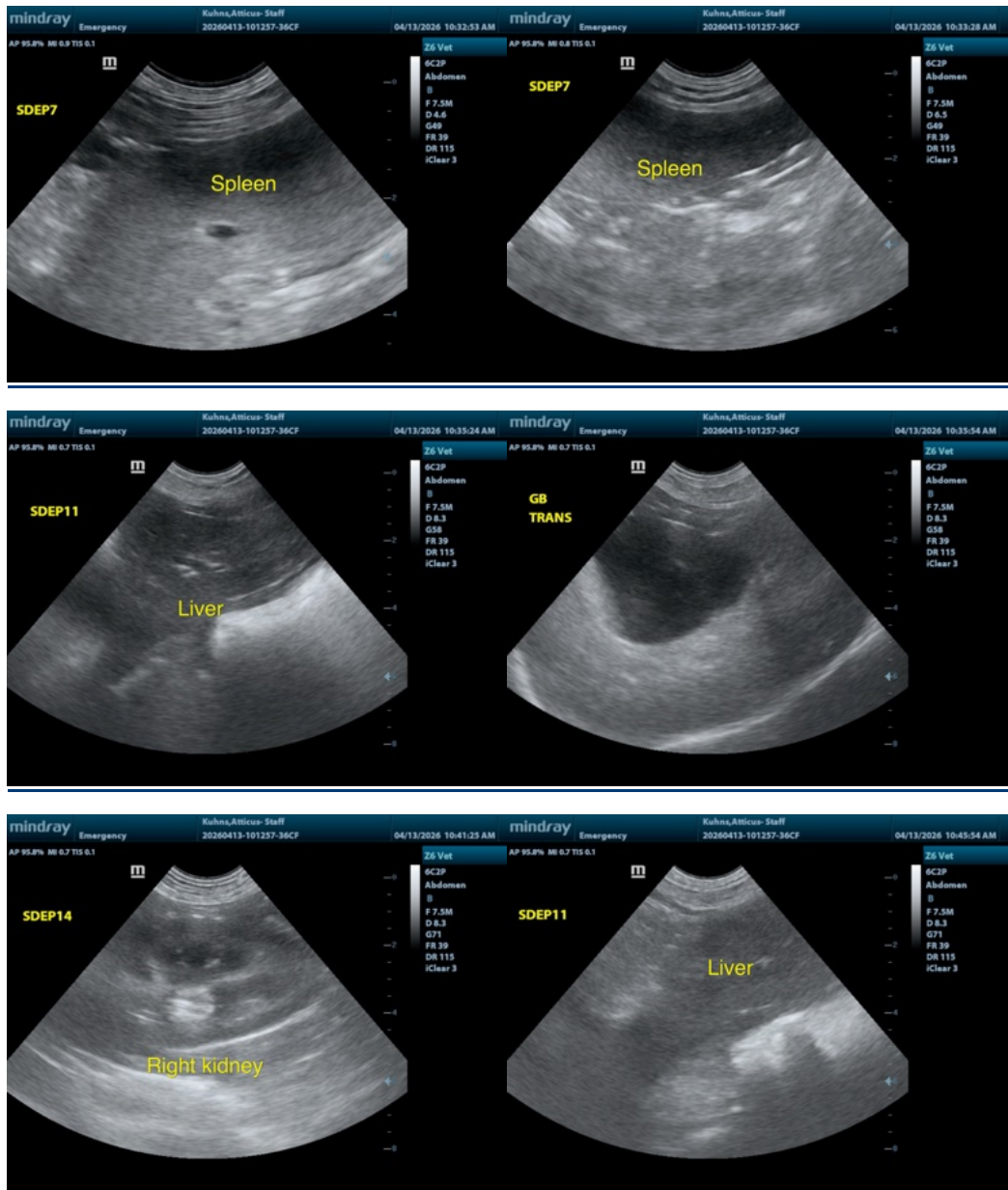
Dr. Vincent

**INVOICE**

74399

**DATE**

4/13/26



The information and recommendations provided are based on the images presented by the referring veterinarian/sonographer. No evaluation can be communicated regarding pathology that was not visible in the image/video clips provided.

Thank you for this referral. If the clinical or image interpretation does not parallel your findings or if I can be of any further assistance please contact me.

Remo Lobetti, BVSc, MMedVet (Med), PhD, Dipl. ECVIM (Internal Medicine)

[info@sonopath.com](mailto:info@sonopath.com)