



PATIENT

Bananas Armstrong

SPECIES

Canine

BREED

Pitbull mix

SEX

Spayed female

AGE

14 years

WEIGHT

42 lbs

INTERPRETED BY

Remo Lobetti, BVSc,
MMedVet (Med),
PhD, Dipl. ECVIM

IMAGING PERFORMED BY

Nikki Kollman RVT

HOSPITAL NAME

Airpark AH

REFERRING VET

Dr. Owens

INVOICE

74368

DATE

4/10/26

PRESENTING CLINICAL SIGNS

History soft tissues sarcoma grade 2 surgically removed in 2024. July of 2025 P started with occasional loss of appetite, V+, D+ August of 2025 treated for pancreatitis. Chronic weight loss over the last several months. Worsening appetite loss and vomiting episodes.

Abnormal PE/Chem/CBC/UA Results: March 2026 Amylase: 2299 Lipase: 5793 Panc Lipase: 1255 TAMU GI panel showed low normal cobalamin 363

ULTRASONOGRAPHIC EXAMINATION OF THE ABDOMEN

Urinary System

The urinary bladder is small with a normal thickness and smooth appearance of the wall. Normal anechoic urine with no sediment or uroliths evident.

Normal appearance of the trigone area, proximal urethra, and iliac blood vessels.

Normal appearance and size of the iliac lymph nodes. Ureters not visualized, which can be considered a normal finding.

Normal left renal size (5.0 cm), architecture, echogenic appearance, cortico-medullary differentiation, which maintains a 1:3 cortex to medulla ratio, pelvis, and capsule. No infarcts, mineralization or renoliths evident. Normal color flow pattern is evident.

The right kidney is not visualized.

Adrenal Glands

The adrenal glands are not visualized.

Spleen

Normal size and echogenic appearance. Smooth homogenous parenchyma and regular curvilinear capsule. Normal volume of the splenic vasculature without any overt congestion or thrombosis evident. No inflammatory, neoplastic, infarction, or infiltrative changes evident. The spleen measured 1.3 cm in width.

Liver

Normal size with a diffuse, increased echogenic, coarse and nodular appearance, normal portal markings, and regular curvilinear capsule. Nodules are multiple, hypoechoic, parenchymal and measure up to 1.0 x 1.5 cm in size. No masses are evident. Normal appearance of the hepatic and portal vasculature.

Gallbladder



PATIENT

Bananas Armstrong

SPECIES

Canine

BREED

Pitbull mix

SEX

Spayed female

AGE

14 years

WEIGHT

42 lbs

INTERPRETED BY

Remo Lobetti, BVSc,
MMedVet (Med),
PhD, Dipl. ECVIM

IMAGING PERFORMED BY

Nikki Kollman RVT

HOSPITAL NAME

Airpark AH

REFERRING VET

Dr. Owens

INVOICE

74368

DATE

4/10/26

The gallbladder is small containing normal anechoic bile. Normal thickness and echogenic appearance of the wall. Normal size and appearance of the cystic and common bile duct.

Gastrointestinal

Normal appearance of the stomach, duodenum, small intestine, ileo-cecal junction, and colon with no loss of layering, 1:3 muscularis to mucosa ratio, normal wall thickness and peristaltic activity, and no distension of the lumen. A moderate amount of ingesta is present in the stomach compatible with a recent meal.

Pancreas

The visible sections of the pancreas are of normal size and echogenic appearance with a regular capsule. Normal echogenic appearance of the mesentery and fat surrounding the pancreas.

Free Abdomen

Normal mesenteric lymph nodes.

No ascites evident.

ULTRASONOGRAPHIC FINDINGS

- Nodular hepatopathy.

INTERPRETATION OF THE FINDINGS & FURTHER RECOMMENDATIONS

Etiologies for the nodular hepatopathy would be nodular hyperplasia, granulomatous disease and infiltrative neoplasia. The latter an important differential diagnosis taking the patient's history into consideration.

Further assessment would be three view thoracic radiographs and FNA cytology of the liver. A tru cut or wedge biopsy of the liver may be required for a final etiological diagnosis.

Specific therapy would be dependent on an etiological diagnosis.



PATIENT

Bananas Armstrong

SPECIES

Canine

BREED

Pitbull mix

SEX

Spayed female

AGE

14 years

WEIGHT

42 lbs

INTERPRETED BY

Remo Lobetti, BVSc,
MMedVet (Med),
PhD, Dipl. ECVIM

IMAGING PERFORMED BY

Nikki Kollman RVT

HOSPITAL NAME

Airpark AH

REFERRING VET

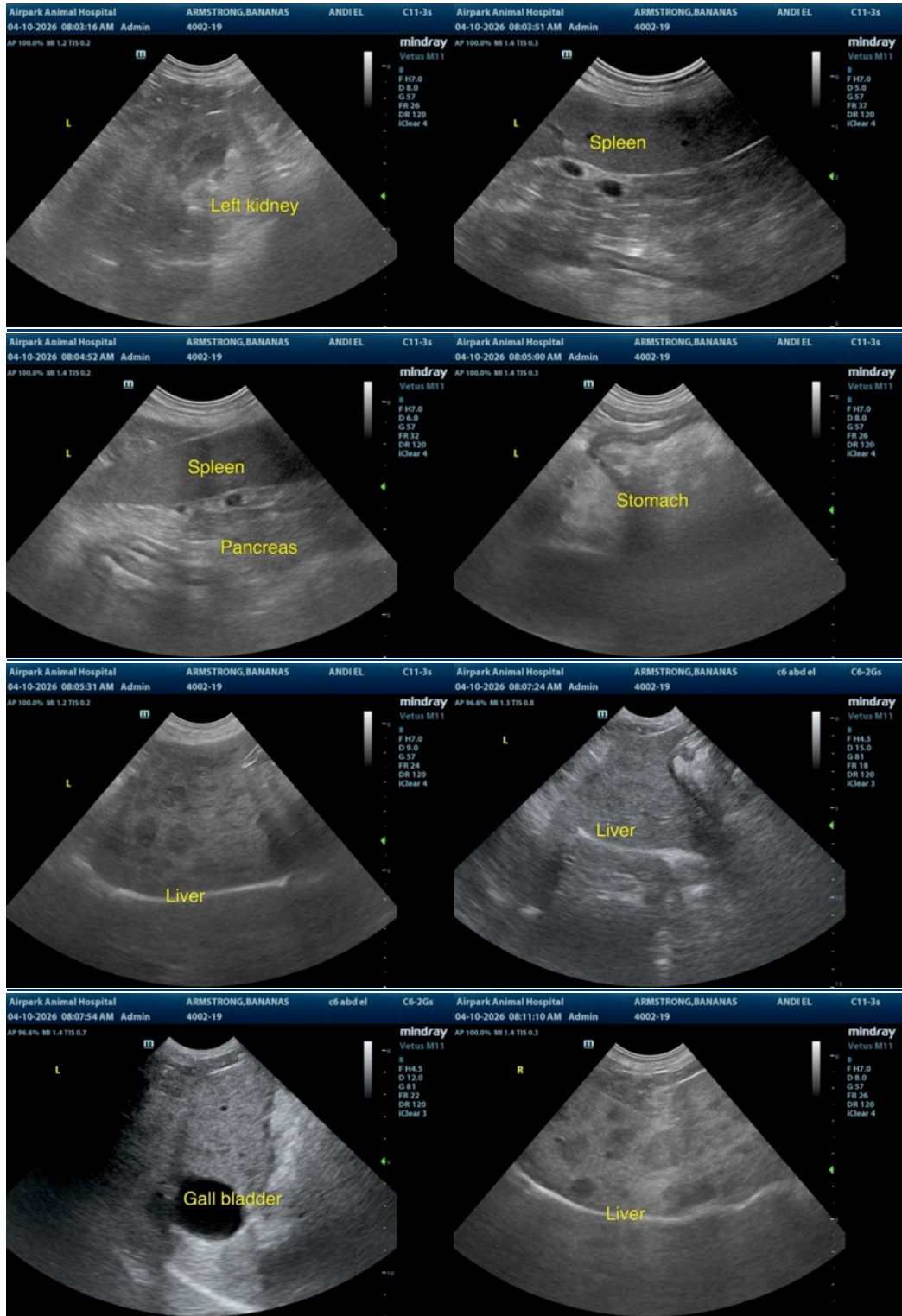
Dr. Owens

INVOICE

74368

DATE

4/10/26





PATIENT

Bananas Armstrong

SPECIES

Canine

BREED

Pitbull mix

SEX

Spayed female

AGE

14 years

WEIGHT

42 lbs

INTERPRETED BY

Remo Lobetti, BVSc,
MMedVet (Med),
PhD, Dipl. ECVIM

IMAGING PERFORMED BY

Nikki Kollman RVT

HOSPITAL NAME

Airpark AH

REFERRING VET

Dr. Owens

INVOICE

74368

DATE

4/10/26

The information and recommendations provided are based on the images presented by the referring veterinarian/sonographer. No evaluation can be communicated regarding pathology that was not visible in the image/video clips provided.

Thank you for this referral. If the clinical or image interpretation does not parallel your findings or if I can be of any further assistance please contact me.

Remo Lobetti, BVSc, MMedVet (Med), PhD, Dipl. ECVIM (Internal Medicine)

info@sonopath.com