



PATIENT

Leslie Knope Wright

SPECIES

Canine

BREED

GoldenRetriever

SEX

Spayed female

AGE

8 years

WEIGHT

56 lbs

INTERPRETED BY

Remo Lobetti, BVSc,
MMedVet (Med),
PhD, Dipl. ECVIM

IMAGING PERFORMED BY

Brian Klug

HOSPITAL NAME

Sondle Family VC

REFERRING VET

Dr. Frankenthal

INVOICE

74027

DATE

4/1/26

PRESENTING CLINICAL SIGNS

- Presented for a routine dental on 3/31. Pre-op BW showed Cr 2.3 (new, was normal in Oct 2025). Same day morning USG 1.008. No symptoms, P doing well at home. Working up for potential CKD/AKI or infectious.
- CHEM- creatinine 2.3 (elevated; normal in October), electrolytes normal, rest wnl Free catch urine - USG 1.008 (hyposthenuria) CBC - stress leukogram, remaining nsf UPC normal (0.1) Pending Lepto PCR and MAT titers Pending urine culture

ULTRASONOGRAPHIC EXAMINATION OF THE ABDOMEN

Urinary System

The urinary bladder is small with a normal thickness and smooth appearance of the wall. Normal anechoic urine with no sediment or uroliths evident.

Normal appearance of the trigone area, proximal urethra, and iliac blood vessels.

Normal appearance and size of the iliac lymph nodes. Ureters not visualized, which can be considered a normal finding.

Normal renal size (left measured 5.7 cm, right measured 5.8 cm), architecture, echogenic appearance, cortico-medullary differentiation, which maintains a 1:3 cortex to medulla ratio, pelvis, and capsule. No infarcts, mineralization or renoliths evident.

Adrenal Glands

Normal shape, echogenic appearance, size, position, and appearance of the visible peri-adrenal vasculature. Left adrenal gland measured 0.5 cm and 0.31 cm in width. The right adrenal gland measured 0.6 cm in width.

Spleen

Normal size and echogenic appearance. Smooth homogenous parenchyma and regular curvilinear capsule. Normal volume of the splenic vasculature without any overt congestion or thrombosis evident. No inflammatory, neoplastic, infarction, or infiltrative changes evident. The spleen measured 2.1 cm in width.

Liver

Normal size, echogenic appearance, portal markings, and regular curvilinear capsule. No nodules or masses evident. Normal appearance of the hepatic and portal vasculature.



PATIENT

Leslie Knope Wright

SPECIES

Canine

BREED

GoldenRetriever

SEX

Spayed female

AGE

8 years

WEIGHT

56 lbs

INTERPRETED BY

Remo Lobetti, BVSc,
MMedVet (Med),
PhD, Dipl. ECVIM

IMAGING PERFORMED BY

Brian Klug

HOSPITAL NAME

Sondle Family VC

REFERRING VET

Dr. Frankenthal

INVOICE

74027

DATE

4/1/26

Gallbladder

The gallbladder is full containing normal anechoic bile. Normal thickness and echogenic appearance of the wall. Normal size and appearance of the cystic and common bile duct.

Gastrointestinal

Normal appearance of the stomach, duodenum, small intestine, ileo-cecal junction, and colon with no loss of layering, 1:3 muscularis to mucosa ratio, normal wall thickness and peristaltic activity, and no distension of the lumen. A moderate amount of ingesta is present in the stomach, compatible with a recent meal.

Pancreas

The visible sections of the pancreas are of normal size and echogenic appearance with a regular capsule. Normal echogenic appearance of the mesentery and fat surrounding the pancreas.

Free Abdomen

Normal mesenteric lymph nodes.

No ascites evident.

ULTRASONOGRAPHIC FINDINGS

- Normal ultrasound examination of the abdomen.

INTERPRETATION OF THE FINDINGS & FURTHER RECOMMENDATIONS

Although the kidneys appear ultrasonographically normal, this does not exclude early, chronic kidney disease as the patient has elevated creatinine and isosthenuria.

Further assessment would be blood pressure determination.

Initial management of the renal disease would be feeding a renal diet.



PATIENT

Leslie Knope Wright

SPECIES

Canine

BREED

GoldenRetriever

SEX

Spayed female

AGE

8 years

WEIGHT

56 lbs

INTERPRETED BY

Remo Lobetti, BVSc,
MMedVet (Med),
PhD, Dipl. ECVIM

IMAGING PERFORMED BY

Brian Klug

HOSPITAL NAME

Sondle Family VC

REFERRING VET

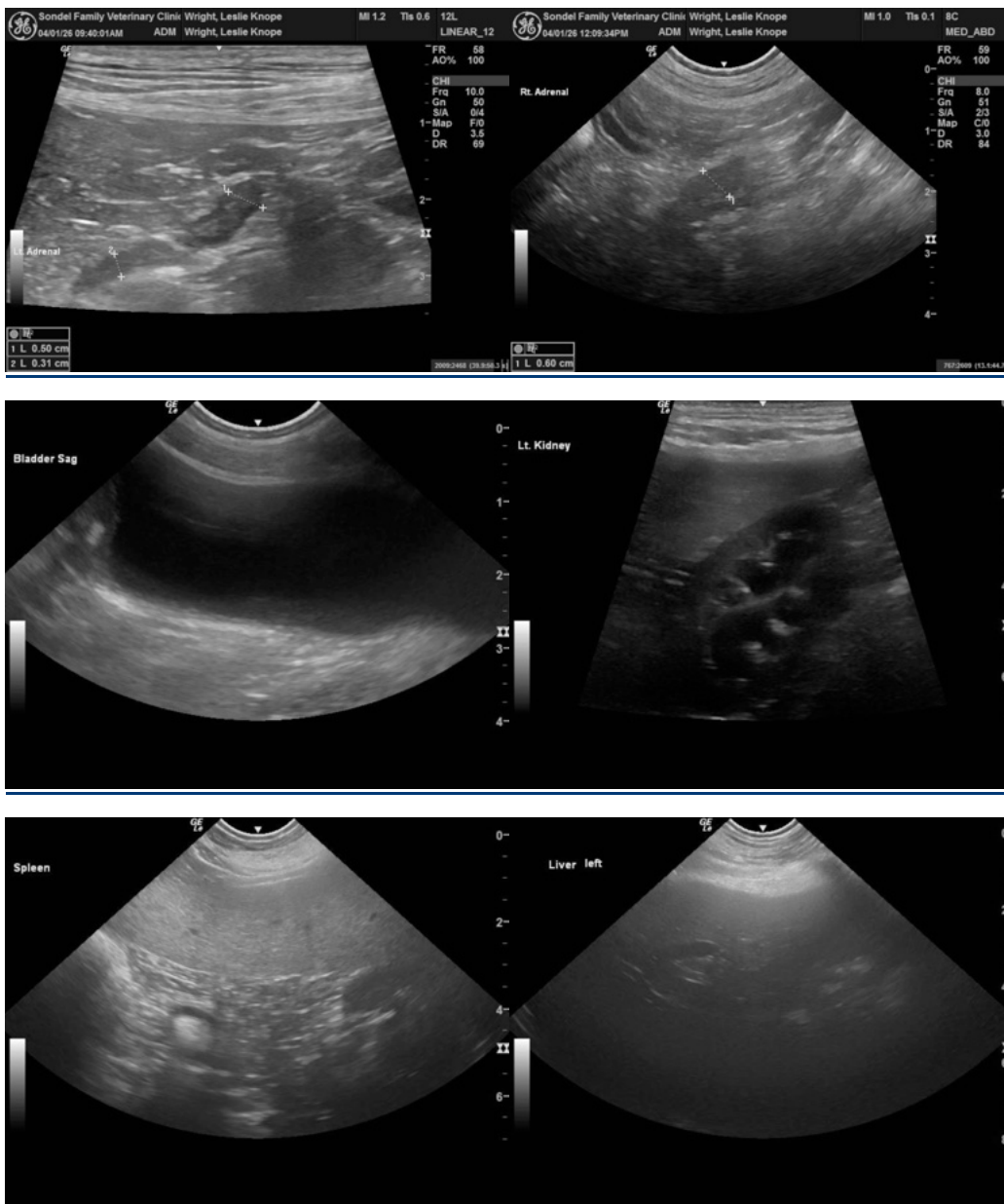
Dr. Frankenthal

INVOICE

74027

DATE

4/1/26





PATIENT

Leslie Knope Wright

SPECIES

Canine

BREED

GoldenRetriever

SEX

Spayed female

AGE

8 years

WEIGHT

56 lbs

INTERPRETED BY

Remo Lobetti, BVSc,
MMedVet (Med),
PhD, Dipl. ECVIM

IMAGING PERFORMED BY

Brian Klug

HOSPITAL NAME

Sondle Family VC

REFERRING VET

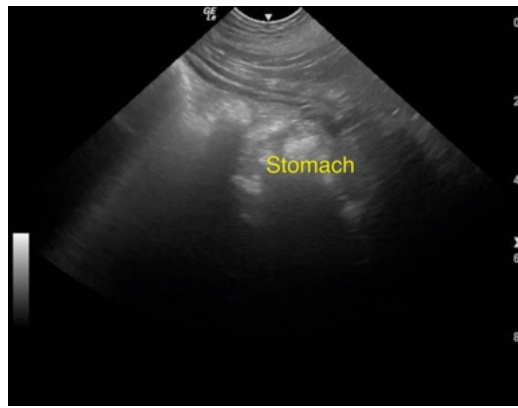
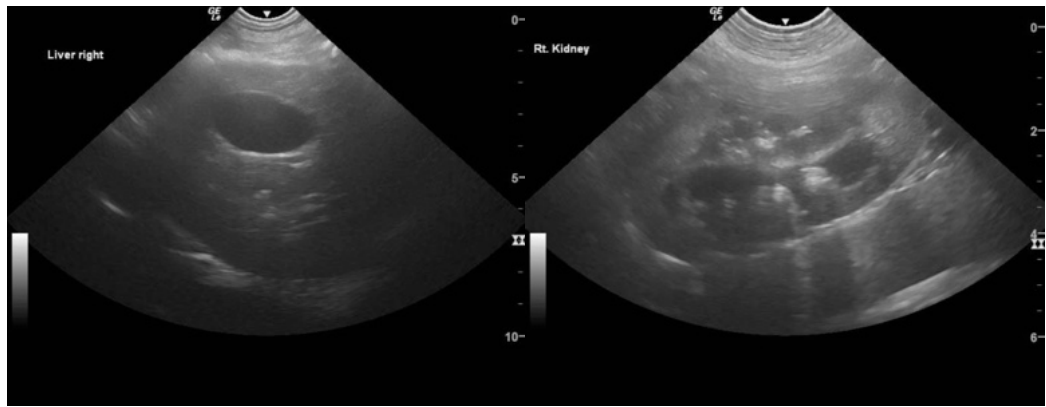
Dr. Frankenthal

INVOICE

74027

DATE

4/1/26



The information and recommendations provided are based on the images presented by the referring veterinarian/sonographer. No evaluation can be communicated regarding pathology that was not visible in the image/video clips provided.

Thank you for this referral. If the clinical or image interpretation does not parallel your findings or if I can be of any further assistance please contact me.

Remo Lobetti, BVSc, MMedVet (Med), PhD, Dipl. ECVIM (Internal Medicine)

info@sonopath.com