



PATIENT

Guinness Hubbard

SPECIES

Canine

BREED

Poodle Mix

SEX

Neutered male

AGE

8 years

WEIGHT

80 lbs

INTERPRETED BY

Remo Lobetti, BVSc,
MMedVet (Med),
PhD, Dipl. ECVIM

IMAGING PERFORMED BY

Jessica Milligan

HOSPITAL NAME

Dockside VI

REFERRING VET

Dr. Bell

INVOICE

72348

DATE

3/9/26

PRESENTING CLINICAL SIGNS

- Elevated ALT

ULTRASONOGRAPHIC EXAMINATION OF THE ABDOMEN

Urinary System

The urinary bladder is full with a normal thickness and smooth appearance of the wall. A scant amount of floating hyperechogenic sediment.

Normal appearance of the trigone area, proximal urethra, and iliac blood vessels.

Normal appearance and size of the iliac lymph nodes. Ureters not visualized, which can be considered a normal finding.

Normal renal size (left measured 7.1 cm, right measured 5.7 cm), architecture, echogenic appearance, cortico-medullary differentiation, which maintains a 1:3 cortex to medulla ratio, pelvis, and capsule. No infarcts, mineralization or renoliths evident. Normal color flow pattern is evident in both kidneys.

The prostate was small and hypogenic measuring 0.7 cm in width.

Adrenal Glands

Normal shape, echogenic appearance, size, position, and appearance of the visible peri-adrenal vasculature. Left adrenal gland measured 0.51 cm in width. The right adrenal gland measured 0.51 cm and 0.42 cm in width.

Spleen

Normal size and echogenic appearance. Smooth homogenous parenchyma and regular curvilinear capsule. Normal volume of the splenic vasculature without any overt congestion or thrombosis evident. No inflammatory, neoplastic, infarction, or infiltrative changes evident. The spleen measured 3.1 cm in width.

Liver

Normal size, echogenic appearance, portal markings, and regular curvilinear capsule. No nodules are evident. Hypoechoic, well circumscribed mass is present in the right lobe measuring 1.8 x 2.3 cm in size. No additional masses evident. Normal appearance of the hepatic and portal vasculature.

Gallbladder

The gallbladder is small containing normal anechoic bile. Normal thickness and echogenic appearance of the wall. Normal size and appearance of the cystic and common bile duct.



PATIENT

Guinness Hubbard

SPECIES

Canine

BREED

Poodle Mix

SEX

Neutered male

AGE

8 years

WEIGHT

80 lbs

INTERPRETED BY

Remo Lobetti, BVSc,
MMedVet (Med),
PhD, Dipl. ECVIM

IMAGING PERFORMED BY

Jessica Milligan

HOSPITAL NAME

Dockside VI

REFERRING VET

Dr. Bell

INVOICE

72348

DATE

3/9/26

Gastrointestinal

Normal appearance of the stomach, duodenum, small intestine, ileo-cecal junction, and colon with no loss of layering, 1:3 muscularis to mucosa ratio, normal wall thickness and peristaltic activity, and no distension of the lumen. A moderate amount of ingesta is present within the stomach compatible with a recent meal. Fecal material is present within the colon.

Pancreas

The visible sections of the pancreas are of normal size and echogenic appearance with a regular capsule. Normal echogenic appearance of the mesentery and fat surrounding the pancreas.

Free Abdomen

Normal mesenteric lymph nodes.

No ascites evident.

ULTRASONOGRAPHIC FINDINGS

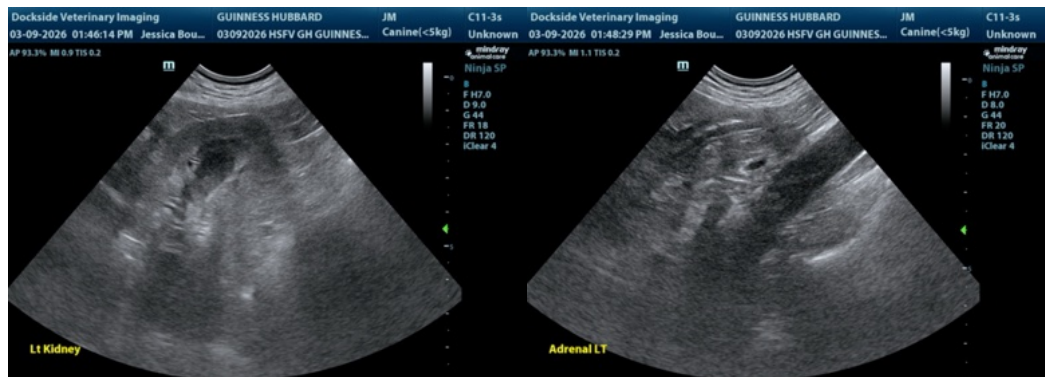
- Hepatic mass.

INTERPRETATION OF THE FINDINGS & FURTHER RECOMMENDATIONS

Etiologies for the hepatic mass would be hepatoma, granuloma, extensive nodular hyperplasia and possibly emerging primary hepatocellular carcinoma.

Further assessment would be FNA cytology of the hepatic mass; however, a tru cut or wedge biopsy may be required for a final etiological diagnosis.

Specific therapy would be dependent on an etiological diagnosis. If surgery is being contemplated for the mass then a CT scan would be recommended.





PATIENT

Guinness Hubbard

SPECIES

Canine

BREED

Poodle Mix

SEX

Neutered male

AGE

8 years

WEIGHT

80 lbs

INTERPRETED BY

Remo Lobetti, BVSc,
MMedVet (Med),
PhD, Dipl. ECVIM

IMAGING PERFORMED BY

Jessica Milligan

HOSPITAL NAME

Dockside VI

REFERRING VET

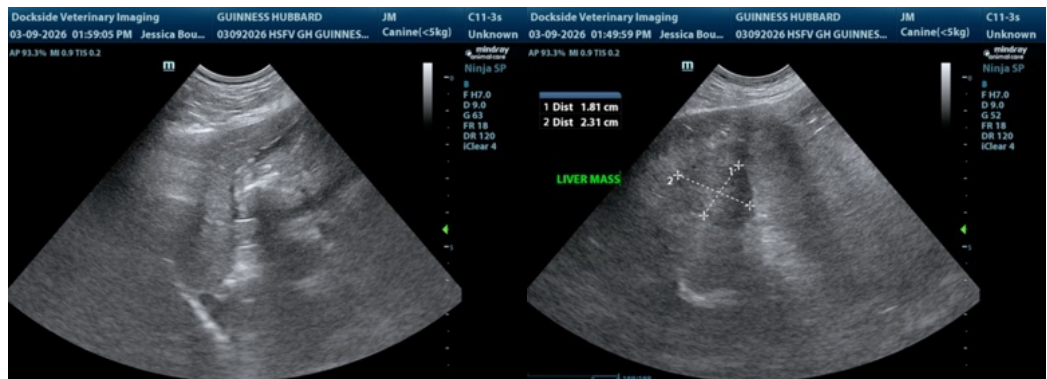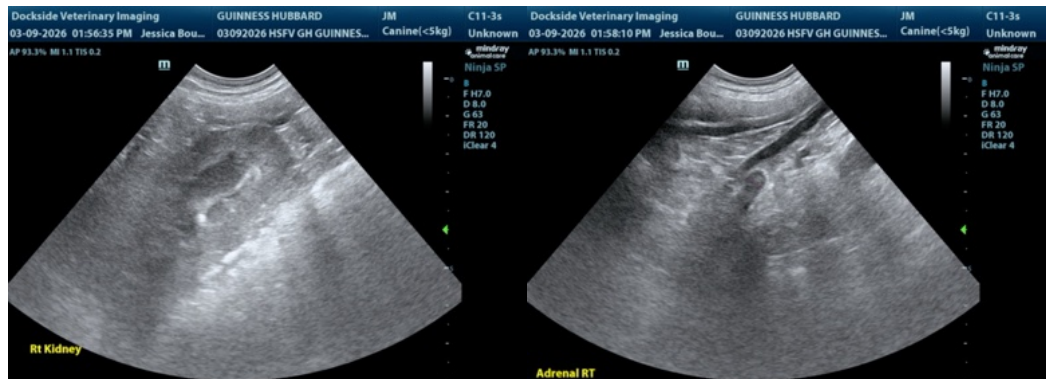
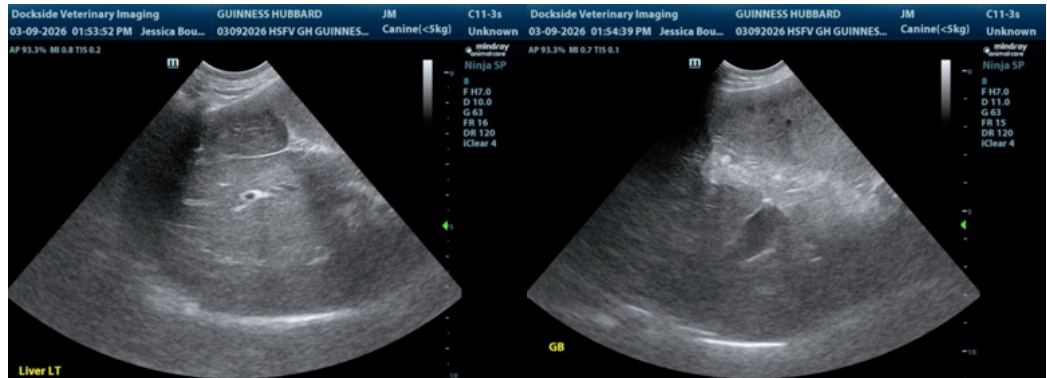
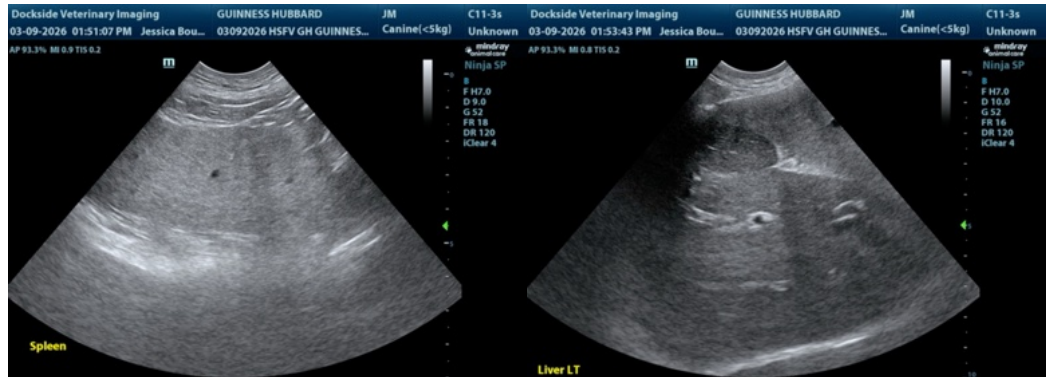
Dr. Bell

INVOICE

72348

DATE

3/9/26





PATIENT

Guinness Hubbard

SPECIES

Canine

BREED

Poodle Mix

SEX

Neutered male

AGE

8 years

WEIGHT

80 lbs

INTERPRETED BY

Remo Lobetti, BVSc,
MMedVet (Med),
PhD, Dipl. ECVIM

IMAGING PERFORMED BY

Jessica Milligan

HOSPITAL NAME

Dockside VI

REFERRING VET

Dr. Bell

INVOICE

72348

DATE

3/9/26

The information and recommendations provided are based on the images presented by the referring veterinarian/sonographer. No evaluation can be communicated regarding pathology that was not visible in the image/video clips provided.

Thank you for this referral. If the clinical or image interpretation does not parallel your findings or if I can be of any further assistance please contact me.

Remo Lobetti, BVSc, MMedVet (Med), PhD, Dipl. ECVIM (Internal Medicine)

info@sonopath.com