



PATIENT

Ginger Miller

SPECIES

Feline

BREED

Domestic Shorthair

SEX

Spayed female

AGE

7 years

WEIGHT

8.1 kgs

INTERPRETED BY

Remo Lobetti, BVSc,
MMedVet (Med),
PhD, Dipl. ECVIM

IMAGING PERFORMED BY

Renee Trionfetti, VMD

HOSPITAL NAME

4 Paws VU

REFERRING VET

Dr. Wanner

INVOICE

72342

DATE

3/9/26

PRESENTING CLINICAL SIGNS

- AUS to further evaluate anorexia. Decrease appetite since Monday 3/2/26. Vomiting white foam and seems lethargic. Day hospitalized 2 days for supportive care, IVF, GI support. ER visit suspected pancreatitis.
- BW- WNL Rads- WNL Focus Ultrasound - subj small kidney

ULTRASONOGRAPHIC EXAMINATION OF THE ABDOMEN

Urinary System

The urinary bladder is full with a normal thickness and smooth appearance of the wall. Normal anechoic urine with no sediment or uroliths evident.

Normal appearance of the trigone area, proximal urethra, and iliac blood vessels.

Normal appearance and size of the iliac lymph nodes. Ureters not visualized, which can be considered a normal finding.

Normal renal size (left measured 4.1 cm, right measured 4.1 cm), architecture, echogenic appearance, cortico-medullary differentiation, which maintains a 1:3 cortex to medulla ratio, pelvis, and capsule. No infarcts, mineralization or renoliths evident. Normal color flow pattern is evident in both kidneys.

Adrenal Glands

Normal shape, echogenic appearance, size, position, and appearance of the visible peri-adrenal vasculature. Left adrenal gland measured 0.74 cm in length x 0.3 cm and 0.26 cm in width. The right adrenal gland measured 1.53 cm in length x 0.35 cm and 0.5 cm in width.

Spleen

The spleen was enlarged and measured 1.2 cm in width, but maintained a normal echogenic appearance, smooth homogenous parenchyma and regular curvilinear capsule. Normal volume of the splenic vasculature without any overt congestion or thrombosis evident. No inflammatory, neoplastic, infarction, or infiltrative changes evident.

Liver

Normal size, echogenic appearance, portal markings, and regular curvilinear capsule. No nodules or masses evident. Normal appearance of the hepatic and portal vasculature.

Gallbladder

The gallbladder is small containing normal anechoic bile. Normal thickness and echogenic appearance of the wall. Normal size and appearance of the cystic and common bile duct.



PATIENT

Ginger Miller

SPECIES

Feline

BREED

Domestic Shorthair

SEX

Spayed female

AGE

7 years

WEIGHT

8.1 kgs

INTERPRETED BY

Remo Lobetti, BVSc,
MMedVet (Med),
PhD, Dipl. ECVIM

IMAGING PERFORMED BY

Renee Trionfetti, VMD

HOSPITAL NAME

4 Paws VU

REFERRING VET

Dr. Wanner

INVOICE

72342

DATE

3/9/26

Gastrointestinal

Normal appearance of the stomach, duodenum, small intestine, ileo-cecal junction, and colon with no loss of layering, 1:3 muscularis to mucosa ratio, normal wall thickness and peristaltic activity, and no distension of the lumen.

Pancreas

The visible sections of the pancreas are of normal size and echogenic appearance with a regular capsule. Normal echogenic appearance of the mesentery and fat surrounding the pancreas.

Free Abdomen

Normal mesenteric lymph nodes.

No ascites evident.

ULTRASONOGRAPHIC FINDINGS

- Splenomegaly.

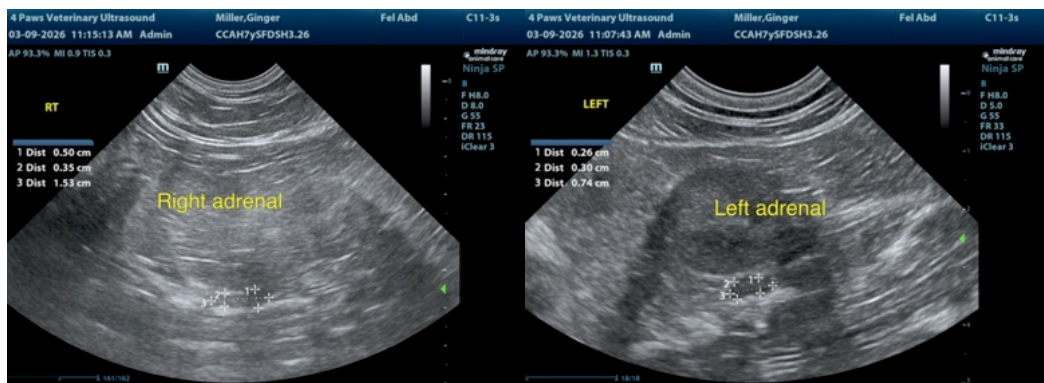
INTERPRETATION OF THE FINDINGS & FURTHER RECOMMENDATIONS

The most likely etiology for the splenomegaly would be reactive hyperplasia with splenitis and infiltrative neoplasia a less likely differential diagnosis.

Although the visible section of the pancreas appears ultrasonographically normal, with the presenting clinical signs, an underlying low-grade pancreatitis should still be considered.

Further assessment would be CPL/PSL and FNA cytology of the spleen.

Further specific therapy would be dependent on an etiological diagnosis.





PATIENT

Ginger Miller

SPECIES

Feline

BREED

Domestic Shorthair

SEX

Spayed female

AGE

7 years

WEIGHT

8.1 kgs

INTERPRETED BY

Remo Lobetti, BVSc,
MMedVet (Med),
PhD, Dipl. ECVIM

IMAGING PERFORMED BY

Renee Trionfetti, VMD

HOSPITAL NAME

4 Paws VU

REFERRING VET

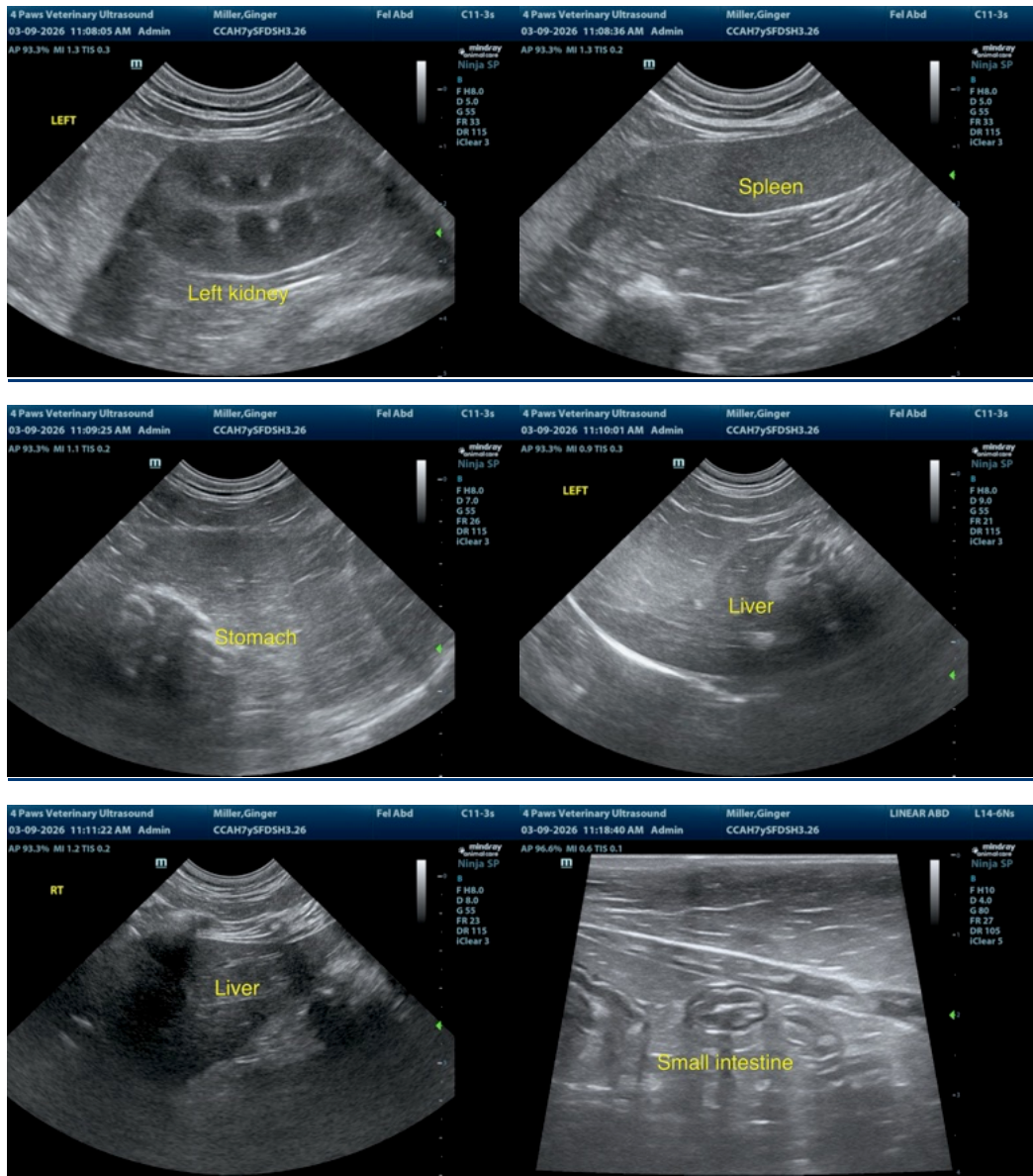
Dr. Wanner

INVOICE

72342

DATE

3/9/26



The information and recommendations provided are based on the images presented by the referring veterinarian/sonographer. No evaluation can be communicated regarding pathology that was not visible in the image/video clips provided.

Thank you for this referral. If the clinical or image interpretation does not parallel your findings or if I can be of any further assistance please contact me.

Remo Lobetti, BVSc, MMedVet (Med), PhD, Dipl. ECVIM (Internal Medicine)

info@sonopath.com