



PATIENT

Sammy Mendenhall

SPECIES

Canine

BREED

Miniature Dachshund

SEX

Neutered male

AGE

8 years

WEIGHT

9.5 lbs

INTERPRETED BY

Remo Lobetti, BVSc,
MMedVet (Med),
PhD, Dipl. ECVIM

IMAGING PERFORMED BY

Dr. Valerie White

HOSPITAL NAME

Great Miami VC

REFERRING VET

Dr. White

INVOICE

72303

DATE

3/6/26

PRESENTING CLINICAL SIGNS

- Dental procedure with mild anemia (had onf) in Oct 2025.
- Lethargic at home recently with 1 lb weight loss, decr appetite at home.
- pcv 21%, retic low normal, plt >250
- PCV 21%, retic low normal, chem: globulins 4.7 (2.5-4.7)

ULTRASONOGRAPHIC EXAMINATION OF THE ABDOMEN

Urinary System

The urinary bladder is small with a normal thickness and smooth appearance of the wall. Normal anechoic urine with no sediment or uroliths evident.

Normal appearance of the trigone area, proximal urethra, and iliac blood vessels.

Normal appearance and size of the iliac lymph nodes. Ureters not visualized, which can be considered a normal finding.

Normal renal size (left measured 3.7 cm, right measured 3.4 cm), architecture, echogenic appearance, cortico-medullary differentiation, which maintains a 1:3 cortex to medulla ratio, pelvis, and capsule. No infarcts, mineralization or renoliths evident.

The prostate is small and hypoechogenic.

Adrenal Glands

The left adrenal gland is normal in shape, echogenic appearance, size, position, and appearance of the visible peri-adrenal vasculature. Left adrenal gland measured 0.43 cm and 0.36 cm. The right adrenal gland was not visualized.

Spleen

Normal size and echogenic appearance. Smooth homogenous parenchyma and regular curvilinear capsule. Normal volume of the splenic vasculature without any overt congestion or thrombosis evident. No inflammatory, neoplastic, infarction, or infiltrative changes evident. The spleen measured 0.9 cm in width.

Liver

Normal size, echogenic appearance, portal markings, and regular curvilinear capsule. No nodules or masses evident. Normal appearance of the hepatic and portal vasculature.



PATIENT

Sammy Mendenhall

SPECIES

Canine

BREED

Miniature Dachshund

SEX

Neutered male

AGE

8 years

WEIGHT

9.5 lbs

INTERPRETED BY

Remo Lobetti, BVSc,
MMedVet (Med),
PhD, Dipl. ECVIM

IMAGING PERFORMED BY

Dr. Valerie White

HOSPITAL NAME

Great Miami VC

REFERRING VET

Dr. White

INVOICE

72303

DATE

3/6/26

Gallbladder

The gallbladder is full containing normal anechoic bile. Normal thickness and echogenic appearance of the wall. Normal size and appearance of the cystic and common bile duct.

Gastrointestinal

Normal appearance of the stomach, duodenum, small intestine, ileo-cecal junction, and colon with no loss of layering, 1:3 muscularis to mucosa ratio, normal wall thickness and peristaltic activity, and no distension of the lumen.

Pancreas

The visible sections of the pancreas are of normal size and echogenic appearance with a regular capsule. Normal echogenic appearance of the mesentery and fat surrounding the pancreas.

Free Abdomen

Normal mesenteric lymph nodes.

No ascites evident.

ULTRASONOGRAPHIC FINDINGS

- Normal ultrasound examination of the abdomen.

INTERPRETATION OF THE FINDINGS & FURTHER RECOMMENDATIONS

On this ultrasound there is no obvious etiology for either the weight loss or progressive anemia.

Etiologies to consider would be low grade gastrointestinal hemorrhage, immune mediated hemolytic anemia and bone marrow pathology.

Further assessment would be NSAID agglutination/Coombs test, endoscopy of the upper GI tract with biopsies and bone marrow cytology/biopsy.

Specific therapy would be dependent on an etiological diagnosis.



PATIENT

Sammy Mendenhall

SPECIES

Canine

BREED

Miniature Dachshund

SEX

Neutered male

AGE

8 years

WEIGHT

9.5 lbs

INTERPRETED BY

Remo Lobetti, BVSc,
MMedVet (Med),
PhD, Dipl. ECVIM

IMAGING PERFORMED BY

Dr. Valerie White

HOSPITAL NAME

Great Miami VC

REFERRING VET

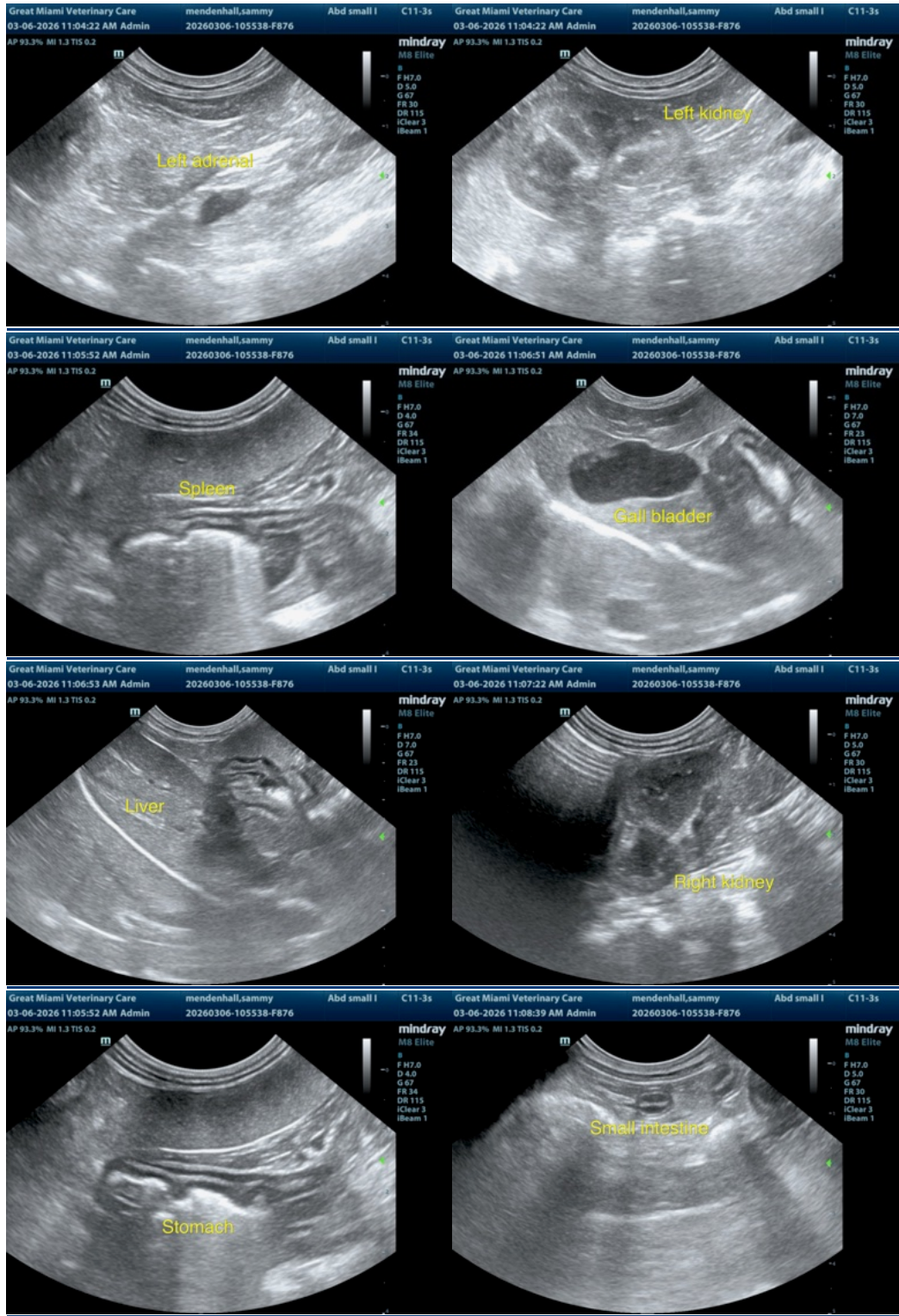
Dr. White

INVOICE

72303

DATE

3/6/26





PATIENT

Sammy Mendenhall

SPECIES

Canine

BREED

Miniature Dachshund

SEX

Neutered male

AGE

8 years

WEIGHT

9.5 lbs

INTERPRETED BY

Remo Lobetti, BVSc,
MMedVet (Med),
PhD, Dipl. ECVIM

IMAGING PERFORMED BY

Dr. Valerie White

HOSPITAL NAME

Great Miami VC

REFERRING VET

Dr. White

INVOICE

72303

DATE

3/6/26

The information and recommendations provided are based on the images presented by the referring veterinarian/sonographer. No evaluation can be communicated regarding pathology that was not visible in the image/video clips provided.

Thank you for this referral. If the clinical or image interpretation does not parallel your findings or if I can be of any further assistance please contact me.

Remo Lobetti, BVSc, MMedVet (Med), PhD, Dipl. ECVIM (Internal Medicine)

info@sonopath.com