



PATIENT

Reagan Heer

SPECIES

Canine

BREED

Lab Mix

SEX

Neutered male

AGE

11 years

WEIGHT

79.5 lbs

INTERPRETED BY

Remo Lobetti, BVSc,
MMedVet (Med),
PhD, Dipl. ECVIM

IMAGING PERFORMED BY

Brandon

HOSPITAL NAME

Dillsburg VC

REFERRING VET

Dr. Amber

INVOICE

72286

DATE

3/6/26

PRESENTING CLINICAL SIGNS

History of not eating well and being gassy and uncomfortable in his abdomen. nothing abnormal felt on abdominal palpation. all of Reagan's littermates have been diagnosed with cancer so owner wanted to do abdominal ultrasound to assess organs. chest radiographs were also performed and are being reviewed. Reagan is on Carprofen, Gabapentin, Trazodone, Maropitant, Ursolyx, and was given Dexdomitor for ultrasound due to demeanor and not wanting him to aggravate his IVDD. Abnormal PE/Chem/CBC/UA Results: CBC/chem WNL, T4/freeT4 WNL, Accuplex negx4, UA showed inactive sediment, dilute urine, fecal NPF

ULTRASONOGRAPHIC EXAMINATION OF THE ABDOMEN

Urinary System

The urinary bladder is small with a normal thickness and smooth appearance of the wall. Normal anechoic urine with no sediment or uroliths evident.

Normal appearance of the trigone area, proximal urethra, and iliac blood vessels.

Normal appearance and size of the iliac lymph nodes. Ureters not visualized, which can be considered a normal finding.

Normal renal size (left measured 7.5 cm, right measured 8.0 cm), architecture, echogenic appearance, cortico-medullary differentiation, which maintains a 1:3 cortex to medulla ratio, pelvis, and capsule. No infarcts, mineralization or renoliths evident. A large cortical cyst was present in the caudal pole of the left kidney measuring 1.9 x 2.7 cm in size.

The prostate is small and hypoechogenic.

Adrenal Glands

Normal shape, echogenic appearance, size, position, and appearance of the visible peri-adrenal vasculature. Left adrenal gland measured 2.44 cm in length x 0.53 cm and 0.57 cm in width. The right adrenal gland measured 1.61 cm in length x 0.5 cm and 0.55 cm in width.

Spleen

Normal size and echogenic appearance. Smooth homogenous parenchyma and regular curvilinear capsule. Normal volume of the splenic vasculature without any overt congestion or thrombosis evident. No inflammatory, neoplastic, infarction, or infiltrative changes evident. The spleen measured 2.1 cm in width.

Liver

Normal size, echogenic appearance, portal markings, and regular curvilinear capsule. No nodules or masses evident. Normal appearance of the hepatic and portal vasculature.



PATIENT

Reagan Heer

SPECIES

Canine

BREED

Lab Mix

SEX

Neutered male

AGE

11 years

WEIGHT

79.5 lbs

INTERPRETED BY

Remo Lobetti, BVSc,
MMedVet (Med),
PhD, Dipl. ECVIM

IMAGING PERFORMED BY

Brandon

HOSPITAL NAME

Dillsburg VC

REFERRING VET

Dr. Amber

INVOICE

72286

DATE

3/6/26

Gallbladder

The gallbladder is full containing normal anechoic bile. Normal thickness and echogenic appearance of the wall. Normal size and appearance of the cystic and common bile duct.

Gastrointestinal

Normal appearance of the stomach, duodenum, small intestine, ileo-cecal junction, and colon with no loss of layering, 1:3 muscularis to mucosa ratio, normal wall thickness and peristaltic activity, and no distension of the lumen.

Pancreas

The visible sections of the pancreas are of normal size and echogenic appearance with a regular capsule. Normal echogenic appearance of the mesentery and fat surrounding the pancreas.

Free Abdomen

Normal mesenteric lymph nodes.

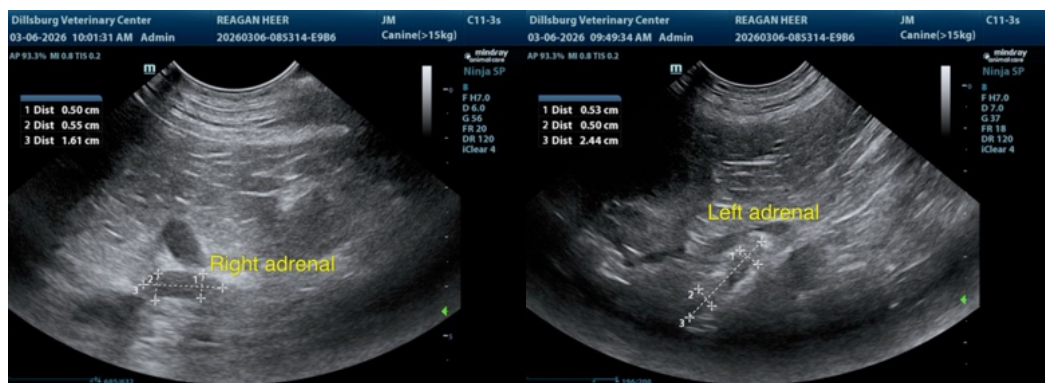
No ascites evident.

ULTRASONOGRAPHIC FINDINGS

- Renal cyst.

INTERPRETATION OF THE FINDINGS & FURTHER RECOMMENDATIONS

In essence a normal ultrasound examination of the abdomen as the renal cyst can be considered an incidental finding. However, it can be associated with abdominal pain as stretching of the renal capsule can occur.





PATIENT

Reagan Heer

SPECIES

Canine

BREED

Lab Mix

SEX

Neutered male

AGE

11 years

WEIGHT

79.5 lbs

INTERPRETED BY

Remo Lobetti, BVSc,
MMedVet (Med),
PhD, Dipl. ECVIM

IMAGING PERFORMED BY

Brandon

HOSPITAL NAME

Dillsburg VC

REFERRING VET

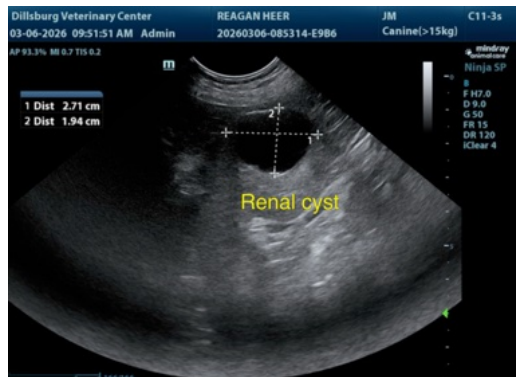
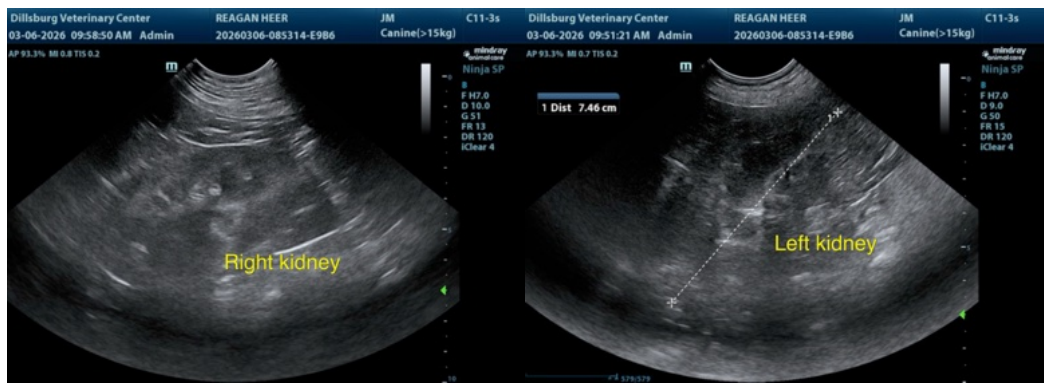
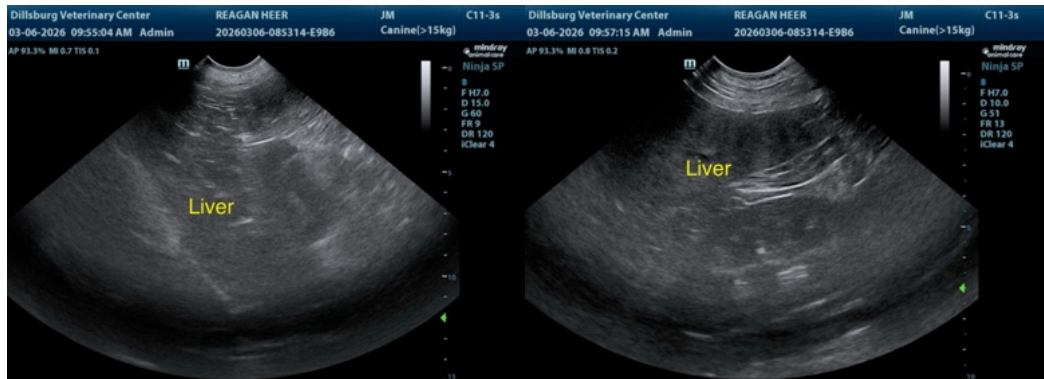
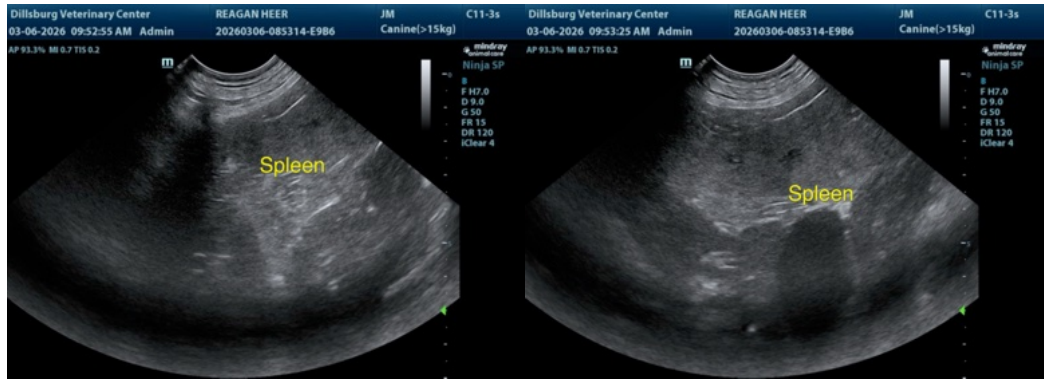
Dr. Amber

INVOICE

72286

DATE

3/6/26





PATIENT

Reagan Heer

SPECIES

Canine

BREED

Lab Mix

SEX

Neutered male

AGE

11 years

WEIGHT

79.5 lbs

INTERPRETED BY

Remo Lobetti, BVSc,
MMedVet (Med),
PhD, Dipl. ECVIM

IMAGING PERFORMED BY

Brandon

HOSPITAL NAME

Dillsburg VC

REFERRING VET

Dr. Amber

INVOICE

72286

DATE

3/6/26

The information and recommendations provided are based on the images presented by the referring veterinarian/sonographer. No evaluation can be communicated regarding pathology that was not visible in the image/video clips provided.

Thank you for this referral. If the clinical or image interpretation does not parallel your findings or if I can be of any further assistance please contact me.

Remo Lobetti, BVSc, MMedVet (Med), PhD, Dipl. ECVIM (Internal Medicine)

info@sonopath.com