



PATIENT

Winnie C2799 Animals
In Distress

SPECIES

Feline

BREED

Domestic Shorthair

SEX

Spayed female

AGE

1 year

WEIGHT

5.12 lbs

INTERPRETED BY

Remo Lobetti, BVSc,
MMedVet (Med),
PhD, Dipl. ECVIM

IMAGING PERFORMED BY

Dr. Renee Ziegler Post

HOSPITAL NAME

For Cats Only VC

REFERRING VET

Dr. Ziegler Post

INVOICE

72254

DATE

3/5/26

PRESENTING CLINICAL SIGNS

- I saw Winnie in Dec. 2025 for vomiting. I did a brief ultrasound at the time and saw a fluid filled structure in her cranial abdomen. I biopsied the wall of the structure and cultured the fluid. Histopath result = Pancreas: Atypical cystic proliferation of pancreatic duct epithelium Culture showed enterococcus faecalis. I treated with antibiotic based on culture. I drained the cyst completely when I collected the biopsy sample. At recheck, the cyst is again filled with fluid. This cyst is sitting mid body of the pancreas. Winnie was referred for surgical consult. Omentalization of the pancreatic cyst was performed 2/20/25. I am seeing her post-op for recheck and I am still seeing a fluid filled structure. Is this appropriate?
- Chem/cbc Globulin 5.5 in December 2025

ULTRASONOGRAPHIC EXAMINATION OF THE ABDOMEN

Urinary System

The urinary bladder is full with a normal thickness and smooth appearance of the wall. Normal anechoic urine with no sediment or uroliths evident.

Normal appearance of the trigone area, proximal urethra, and iliac blood vessels.

Normal appearance and size of the iliac lymph nodes. Ureters not visualized, which can be considered a normal finding.

Normal renal size (left measured 3.4 cm, right measured 3.5 cm), architecture, echogenic appearance, cortico-medullary differentiation, which maintains a 1:3 cortex to medulla ratio, pelvis, and capsule. No infarcts, mineralization or renoliths evident.

Adrenal Glands

The right adrenal gland is normal in shape, echogenic appearance, size, position, and appearance of the visible peri-adrenal vasculature. Right adrenal gland measured 0.29 cm in width. The left adrenal gland was not visualized.

Spleen

The spleen was not visualized.

Liver

Normal size, echogenic appearance, portal markings, and regular curvilinear capsule. No nodules or masses evident. Normal appearance of the hepatic and portal vasculature.



PATIENT

Winnie C2799 Animals
In Distress

SPECIES

Feline

BREED

Domestic Shorthair

SEX

Spayed female

AGE

1 year

WEIGHT

5.12 lbs

INTERPRETED BY

Remo Lobetti, BVSc,
MMedVet (Med),
PhD, Dipl. ECVIM

IMAGING PERFORMED BY

Dr. Renee Ziegler Post

HOSPITAL NAME

For Cats Only VC

REFERRING VET

Dr. Ziegler Post

INVOICE

72254

DATE

3/5/26

Gallbladder

The gallbladder is small containing normal anechoic bile. Severely dilated and cystic appearance of the cystic bile duct with no obstructive evident. On the post surgery images, cystic structure is still evident.

Gastrointestinal

Normal appearance of the stomach, duodenum, small intestine, ileo-cecal junction, and colon with no loss of layering, 1:3 muscularis to mucosa ratio, normal wall thickness and peristaltic activity, and no distension of the lumen. The small intestine measured up to 0.36 cm.

Pancreas

The visible sections of the pancreas are of normal size and echogenic appearance with a regular capsule. Normal echogenic appearance of the mesentery and fat surrounding the pancreas.

Free Abdomen

Normal mesenteric lymph nodes.

No ascites evident.

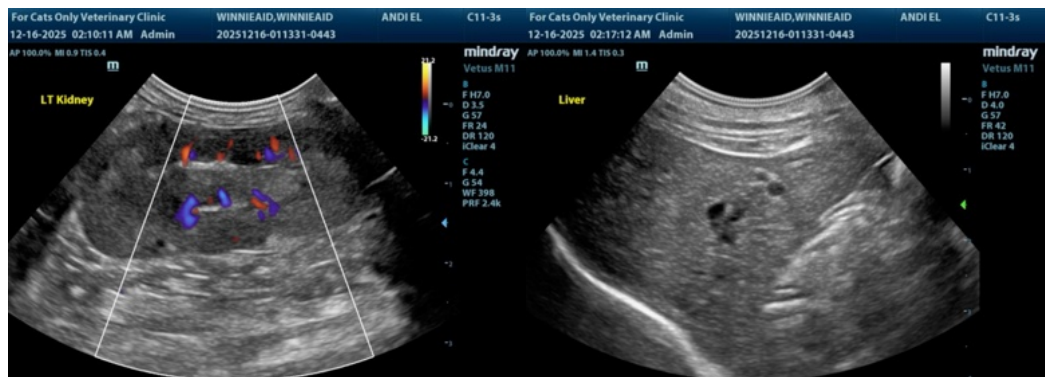
ULTRASONOGRAPHIC FINDINGS

- Ongoing and static appearance of the cystic structure.

INTERPRETATION OF THE FINDINGS & FURTHER RECOMMENDATIONS

As the original diagnosis was cystic proliferation of the pancreatic duct epithelium, as the cystic area was omentalized and not excised, it can be expected to reoccur. The cystic structure most likely represents a congenital anomaly and may result in no long term consequence for the patient.

Additional surgery that can be considered would be marsupilization of the cystic structure.





PATIENT

Winnie C2799 Animals
In Distress

SPECIES

Feline

BREED

Domestic Shorthair

SEX

Spayed female

AGE

1 year

WEIGHT

5.12 lbs

INTERPRETED BY

Remo Lobetti, BVSc,
MMedVet (Med),
PhD, Dipl. ECVIM

IMAGING PERFORMED BY

Dr. Renee Ziegler Post

HOSPITAL NAME

For Cats Only VC

REFERRING VET

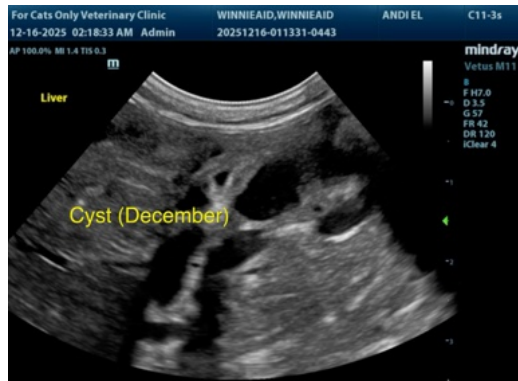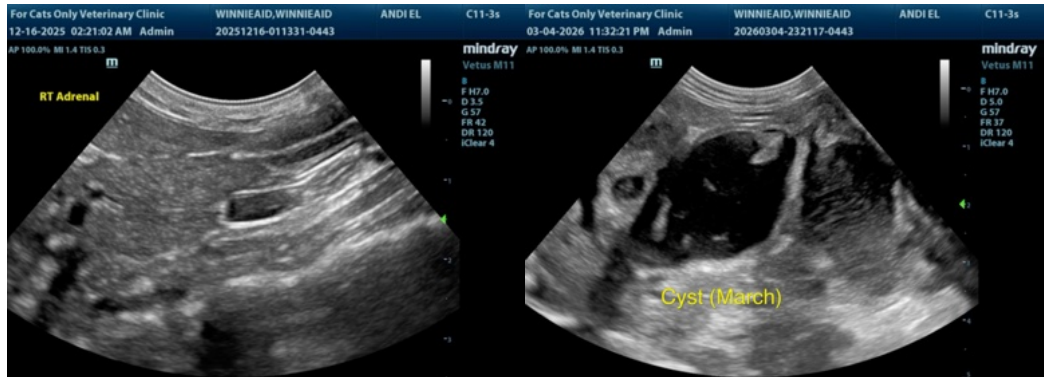
Dr. Ziegler Post

INVOICE

72254

DATE

3/5/26



The information and recommendations provided are based on the images presented by the referring veterinarian/sonographer. No evaluation can be communicated regarding pathology that was not visible in the image/video clips provided.

Thank you for this referral. If the clinical or image interpretation does not parallel your findings or if I can be of any further assistance please contact me.

Remo Lobetti, BVSc, MMedVet (Med), PhD, Dipl. ECVIM (Internal Medicine)

info@sonopath.com