



PATIENT

Jolie Quick

SPECIES

Feline

BREED

Domestic Medium Hair

SEX

Spayed female

AGE

14 years

WEIGHT

6.4 lbs

INTERPRETED BY

Remo Lobetti, BVSc,
MMedVet (Med),
PhD, Dipl. ECVIM

IMAGING PERFORMED BY

Dana Kraeutler, CVT

HOSPITAL NAME

Pocono Peak VC

REFERRING VET

Dr. Mattson

INVOICE

72228

DATE

3/5/26

PRESENTING CLINICAL SIGNS

- 2/24/26: PE: Large abdominal mass-radiographs confirm abdominal hernia. Historically elevated liver enzymes. Appetite WNLs, no issues U/D. Dental disease noted.
- 1/24/26: SDMA: 15, ALT:291, AST: 196, ALP:10, CBC WNLs

ULTRASONOGRAPHIC EXAMINATION OF THE ABDOMEN

Urinary System

The urinary bladder is small with a normal thickness and smooth appearance of the wall. Normal anechoic urine with no sediment or uroliths evident.

Normal appearance of the trigone area, proximal urethra, and iliac blood vessels.

Normal appearance and size of the iliac lymph nodes. Ureters not visualized, which can be considered a normal finding.

The kidneys are bilaterally enlarged (left measured 4.9 cm, right measured 4.3 cm), with a mottled echogenic appearance, loss of cortico-medullary differentiation and multiple cysts of varying sizes with the left kidney containing more cysts than the right kidney. One cyst in the right kidney contains floating, hyperechogenic sediment. The renal pelvises are not evident. Both kidneys have an irregular capsule. No obvious infarcts, mineralization or renoliths evident.

Adrenal Glands

The adrenal glands are normal in shape, echogenic appearance, size, position, and appearance of the visible peri-adrenal vasculature. Left adrenal gland measured 1.54 cm in length x 0.38 cm and 0.36 cm in width. The right adrenal gland measured 0.92 cm in length x 0.27 x 0.21 cm in width.

Spleen

Normal size and echogenic appearance. Smooth homogenous parenchyma and regular curvilinear capsule. Normal volume of the splenic vasculature without any overt congestion or thrombosis evident. No inflammatory, neoplastic, infarction, or infiltrative changes evident. The spleen measured 0.9 cm in width.

Liver

Normal size, echogenic appearance, portal markings, and regular curvilinear capsule. No nodules or masses evident. Normal appearance of the hepatic and portal vasculature.



PATIENT

Jolie Quick

SPECIES

Feline

BREED

Domestic Medium Hair

SEX

Spayed female

AGE

14 years

WEIGHT

6.4 lbs

INTERPRETED BY

Remo Lobetti, BVSc,
MMedVet (Med),
PhD, Dipl. ECVIM

IMAGING PERFORMED BY

Dana Kraeutler, CVT

HOSPITAL NAME

Pocono Peak VC

REFERRING VET

Dr. Mattson

INVOICE

72228

DATE

3/5/26

Gallbladder

The gallbladder is full containing normal anechoic bile. Normal thickness and echogenic appearance of the wall. Normal size and appearance of the cystic and common bile duct.

Gastrointestinal

Normal appearance of the stomach, duodenum, small intestine, ileo-cecal junction, and colon with no loss of layering, 1:3 muscularis to mucosa ratio, normal wall thickness and peristaltic activity, and no distension of the lumen.

Pancreas

The visible sections of the pancreas are of normal size and echogenic appearance with a regular capsule. Normal echogenic appearance of the mesentery and fat surrounding the pancreas.

Free Abdomen

Normal mesenteric lymph nodes.

No ascites evident.

A large abdominal hernia is present containing intestinal loops, but no obvious evidence of strangulation of the loops.

ULTRASONOGRAPHIC FINDINGS

- Polycystic renal disease.
- Abdominal hernia.

INTERPRETATION OF THE FINDINGS & FURTHER RECOMMENDATIONS

Further assessment and therapy needs to be based on the pending results. Surgical correction of the abdominal hernia would be recommended.



PATIENT

Jolie Quick

SPECIES

Feline

BREED

Domestic Medium Hair

SEX

Spayed female

AGE

14 years

WEIGHT

6.4 lbs

INTERPRETED BY

Remo Lobetti, BVSc,
MMedVet (Med),
PhD, Dipl. ECVIM

IMAGING PERFORMED BY

Dana Kraeutler, CVT

HOSPITAL NAME

Pocono Peak VC

REFERRING VET

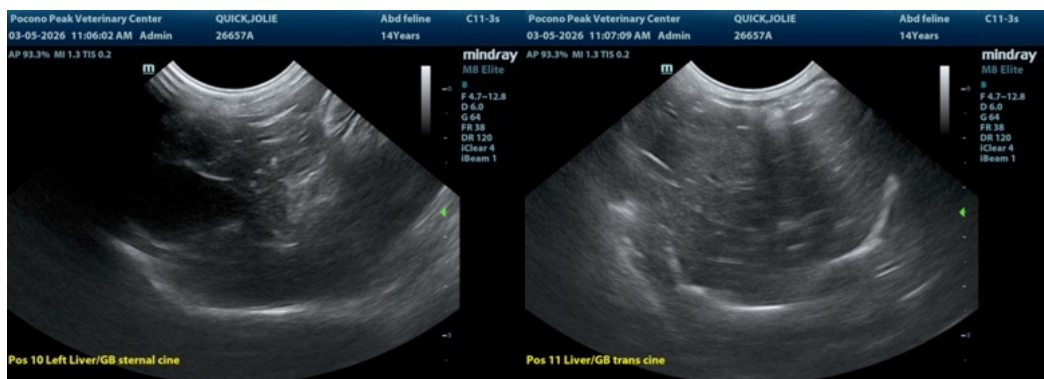
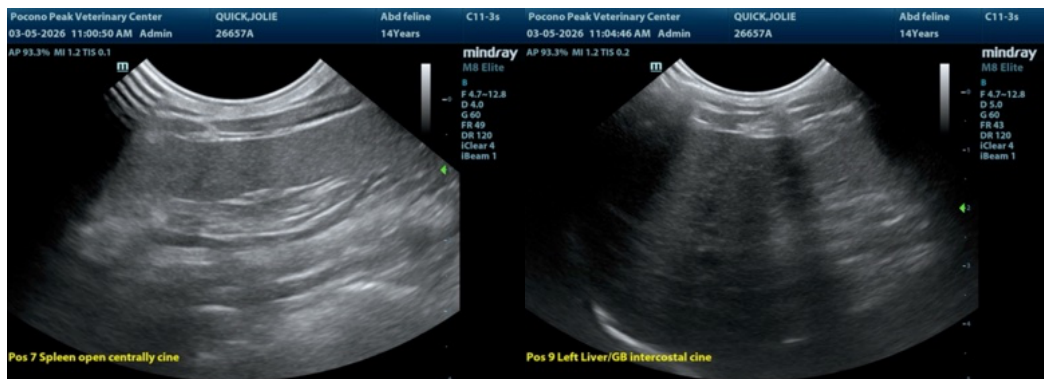
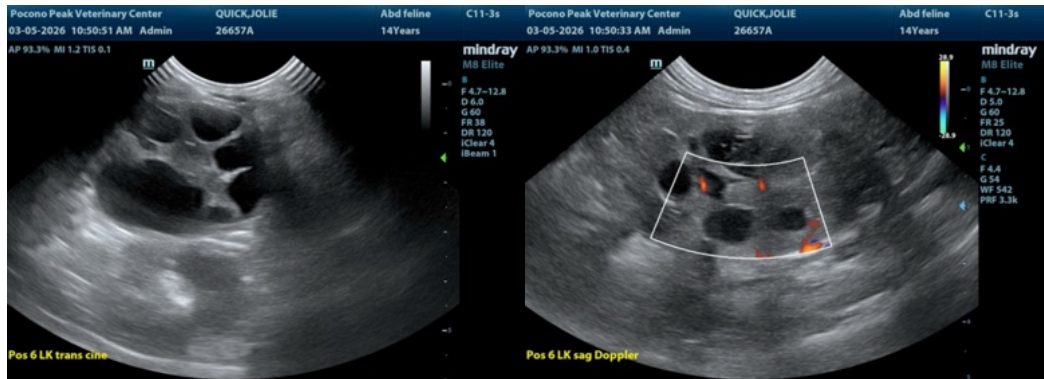
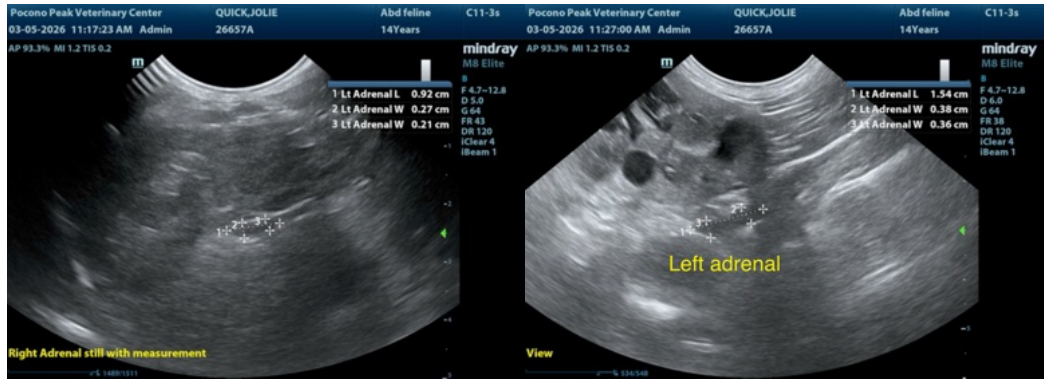
Dr. Mattson

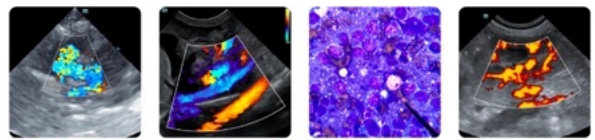
INVOICE

72228

DATE

3/5/26





PATIENT

Jolie Quick

SPECIES

Feline

BREED

Domestic Medium Hair

SEX

Spayed female

AGE

14 years

WEIGHT

6.4 lbs

INTERPRETED BY

Remo Lobetti, BVSc,
MMedVet (Med),
PhD, Dipl. ECVIM

IMAGING PERFORMED BY

Dana Kraeutler, CVT

HOSPITAL NAME

Pocono Peak VC

REFERRING VET

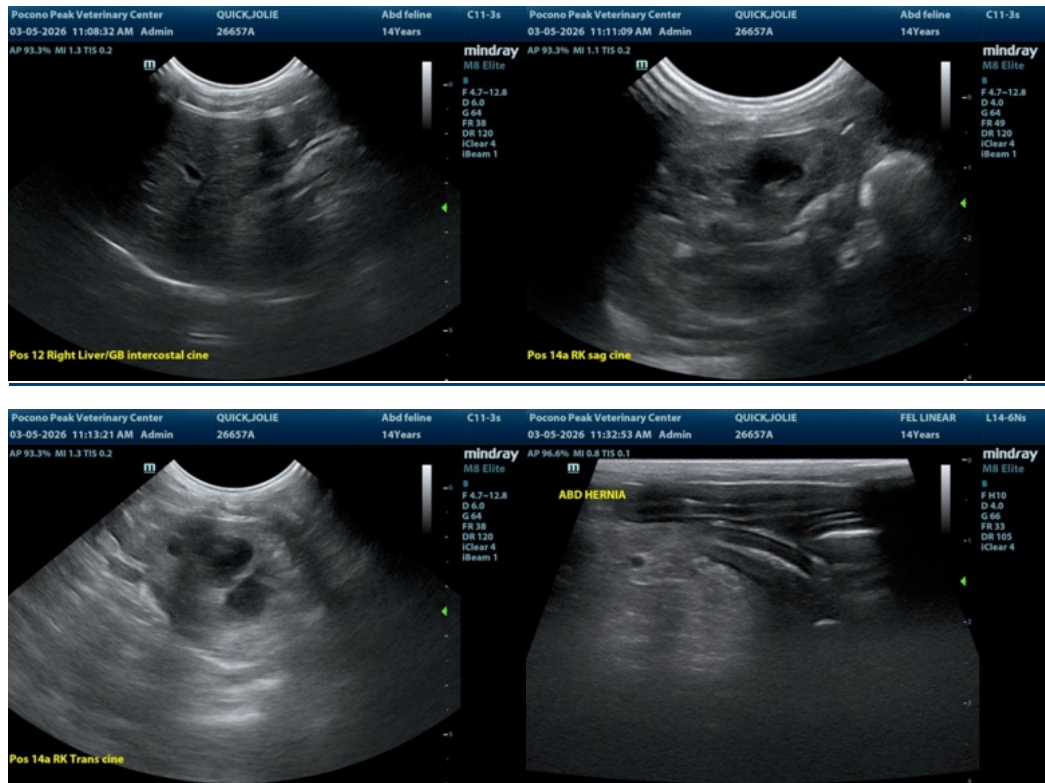
Dr. Mattson

INVOICE

72228

DATE

3/5/26



The information and recommendations provided are based on the images presented by the referring veterinarian/sonographer. No evaluation can be communicated regarding pathology that was not visible in the image/video clips provided.

Thank you for this referral. If the clinical or image interpretation does not parallel your findings or if I can be of any further assistance please contact me.

Remo Lobetti, BVSc, MMedVet (Med), PhD, Dipl. ECVIM (Internal Medicine)

info@sonopath.com