



## PATIENT

Tango Hess

## SPECIES

Feline

## BREED

Domestic Shorthair

## SEX

Neutered male

## AGE

14 years

## WEIGHT

9.04 lbs

## INTERPRETED BY

Remo Lobetti, BVSc,  
MMedVet (Med),  
PhD, Dipl. ECVIM

## IMAGING PERFORMED BY

Jack Reese

## HOSPITAL NAME

Willow Run VC

## REFERRING VET

Dr. Arnold

## INVOICE

72192

## DATE

3/4/26

## PRESENTING CLINICAL SIGNS

- CRF - stable with SQ fluid therapy
- Heart murmur - chronic
- Dental disease
- Continued weight loss
- Progressive anemia
- Noted hyperglobulinemia on labwork
- HCT 33% SDMA 19 Creat 3.1 BUN 71 TP 10.9 Globulins 6.9

## ULTRASONOGRAPHIC EXAMINATION OF THE ABDOMEN

### Urinary System

The urinary bladder is full with a normal thickness and smooth appearance of the wall. Normal anechoic urine with no sediment or uroliths evident.

Normal appearance of the trigone area, proximal urethra, and iliac blood vessels.

Normal appearance and size of the iliac lymph nodes. Ureters not visualized, which can be considered a normal finding.

Normal renal size (left measured 3.6 cm, right measured 3.7 cm), increased echogenic appearance, cortico-medullary differentiation, and normal pelvis and capsule. No infarcts, mineralization or renoliths evident. Reduced color flow pattern is evident in both kidneys.

### Adrenal Glands

The left adrenal gland is not visualized. The right adrenal gland is rounded, mottled echogenic mass that measured 2.1 x 2.3 cm in size, maintaining normal position with no obvious invasion into the surrounding periadrenal vasculature.

### Spleen

Normal size and echogenic appearance. Smooth homogenous parenchyma and regular curvilinear capsule. Normal volume of the splenic vasculature without any overt congestion or thrombosis evident. No inflammatory, neoplastic, infarction, or infiltrative changes evident. The spleen measured 0.8 cm in size.

### Liver

Normal size, echogenic appearance, portal markings, and regular curvilinear capsule. No nodules or masses evident. Normal appearance of the hepatic and portal vasculature.



## PATIENT

Tango Hess

## SPECIES

Feline

## BREED

Domestic Shorthair

## SEX

Neutered male

## AGE

14 years

## WEIGHT

9.04 lbs

## INTERPRETED BY

Remo Lobetti, BVSc,  
MMedVet (Med),  
PhD, Dipl. ECVIM

## IMAGING PERFORMED BY

Jack Reese

## HOSPITAL NAME

Willow Run VC

## REFERRING VET

Dr. Arnold

## INVOICE

72192

## DATE

3/4/26

## ***Gallbladder***

The gallbladder is small containing normal anechoic bile. Normal thickness and echogenic appearance of the wall. Normal size and appearance of the cystic and common bile duct.

## ***Gastrointestinal***

Normal appearance of the stomach, duodenum, small intestine, ileo-cecal junction, and colon with no loss of layering, 1:3 muscularis to mucosa ratio, normal wall thickness and peristaltic activity, and no distension of the lumen.

## ***Pancreas***

The visible sections of the pancreas are of normal size and echogenic appearance with a regular capsule. Normal echogenic appearance of the mesentery and fat surrounding the pancreas.

## ***Free Abdomen***

Normal mesenteric lymph nodes.

No ascites evident.

## **ULTRASONOGRAPHIC FINDINGS**

- Right adrenal mass.
- Renal disease.

## **INTERPRETATION OF THE FINDINGS & FURTHER RECOMMENDATIONS**

The most likely etiology for the right adrenal mass would be a non-functional carcinoma.

The appearance of the kidneys is consistent with chronic kidney disease an in line with the patient's history.

Further assessment would be three view thoracic radiographs and FNA cytology of the adrenal mass.

Serum protein electrophoresis could also be considered.

If surgery is being contemplated for the right adrenal mass, then a CT scan would be recommended.



## PATIENT

Tango Hess

## SPECIES

Feline

## BREED

Domestic Shorthair

## SEX

Neutered male

## AGE

14 years

## WEIGHT

9.04 lbs

## INTERPRETED BY

Remo Lobetti, BVSc,  
MMedVet (Med),  
PhD, Dipl. ECVIM

## IMAGING PERFORMED BY

Jack Reese

## HOSPITAL NAME

Willow Run VC

## REFERRING VET

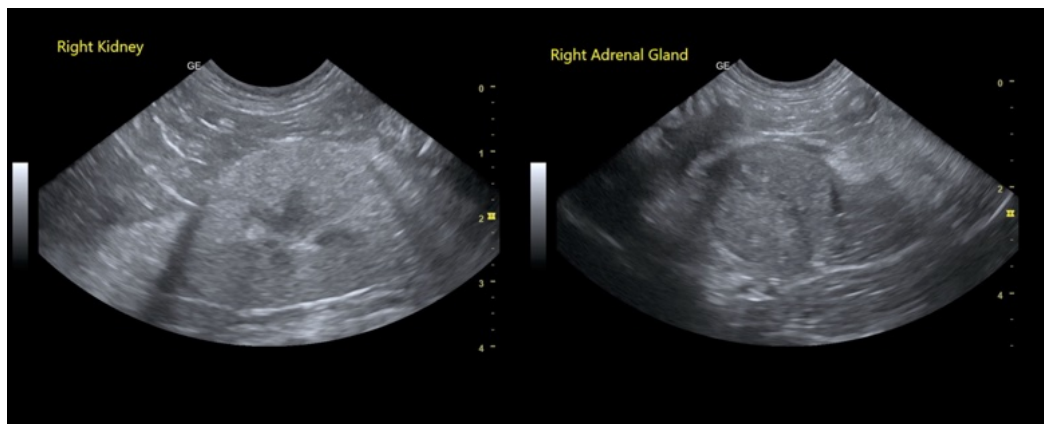
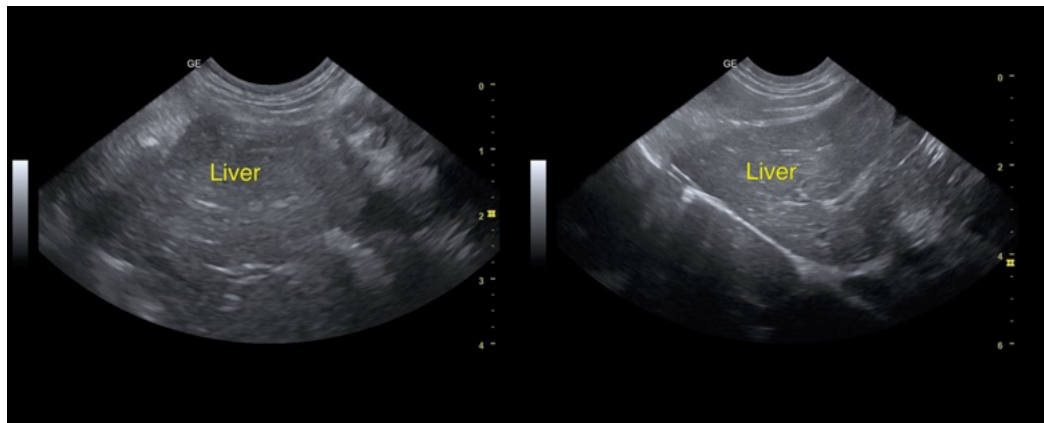
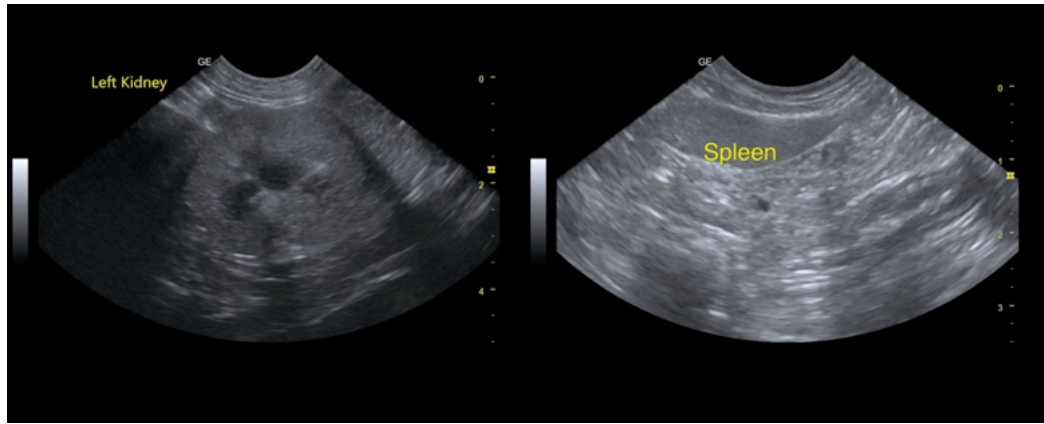
Dr. Arnold

## INVOICE

72192

## DATE

3/4/26





## PATIENT

Tango Hess

## SPECIES

Feline

## BREED

Domestic Shorthair

## SEX

Neutered male

## AGE

14 years

## WEIGHT

9.04 lbs

## INTERPRETED BY

Remo Lobetti, BVSc,  
MMedVet (Med),  
PhD, Dipl. ECVIM

## IMAGING PERFORMED BY

Jack Reese

## HOSPITAL NAME

Willow Run VC

## REFERRING VET

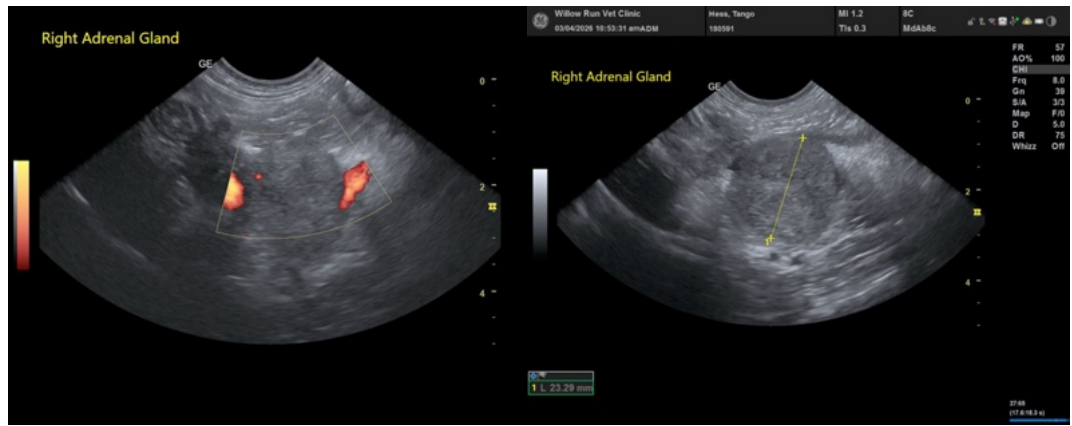
Dr. Arnold

## INVOICE

72192

## DATE

3/4/26



The information and recommendations provided are based on the images presented by the referring veterinarian/sonographer. No evaluation can be communicated regarding pathology that was not visible in the image/video clips provided.

Thank you for this referral. If the clinical or image interpretation does not parallel your findings or if I can be of any further assistance please contact me.

Remo Lobetti, BVSc, MMedVet (Med), PhD, Dipl. ECVIM (Internal Medicine)

[info@sonopath.com](mailto:info@sonopath.com)