



PATIENT

Chance Neitzel

SPECIES

Canine

BREED

Golden Retriever

SEX

Neutered male

AGE

12 years

WEIGHT

58 lbs

INTERPRETED BY

Remo Lobetti, BVSc,
MMedVet (Med),
PhD, Dipl. ECVIM

IMAGING PERFORMED BY

Dr. Lundemulder

HOSPITAL NAME

Southkent VH

REFERRING VET

Dr. Lundemulder

INVOICE

72222

DATE

3/4/26

PRESENTING CLINICAL SIGNS

- Slow but significant unintentional weight loss
- UA - hematuria, pyuria Urine cytology - transitional cells present

ULTRASONOGRAPHIC EXAMINATION OF THE ABDOMEN

Urinary System

The urinary bladder is full with a normal thickness and smooth appearance of the wall. Normal anechoic urine with no sediment or uroliths evident.

Normal appearance of the trigone area, proximal urethra, and iliac blood vessels.

Normal appearance and size of the iliac lymph nodes. Ureters not visualized, which can be considered a normal finding.

The left kidney is normal in size (left measured 4.8 cm), architecture, echogenic appearance, cortico-medullary differentiation, which maintains a 1:3 cortex to medulla ratio, pelvis, and capsule. No infarcts, mineralization or renoliths evident.

The right kidney was not clearly visualized, but appears to be of normal shape, echogenic appearance and size.

The prostate is small and hypoechogenic measuring 0.8 cm in width.

Adrenal Glands

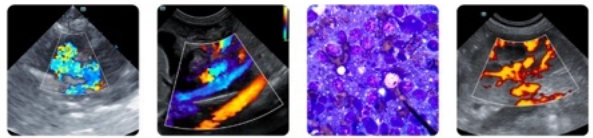
The left adrenal gland is normal in shape, echogenic appearance, size, position, and appearance of the visible peri-adrenal vasculature. Left adrenal gland measured 1.6 cm in length x 0.46 cm in width. The right adrenal gland was not visualized.

Spleen

Normal size and echogenic appearance. Smooth homogenous parenchyma and regular curvilinear capsule. Normal volume of the splenic vasculature without any overt congestion or thrombosis evident. No inflammatory, neoplastic, infarction, or infiltrative changes evident. The spleen measured 2.7 cm in width.

Liver

Normal size, echogenic appearance, portal markings, and regular curvilinear capsule. No nodules or masses evident. Normal appearance of the hepatic and portal vasculature.



PATIENT

Chance Neitzel

SPECIES

Canine

BREED

Golden Retriever

SEX

Neutered male

AGE

12 years

WEIGHT

58 lbs

INTERPRETED BY

Remo Lobetti, BVSc,
MMedVet (Med),
PhD, Dipl. ECVIM

IMAGING PERFORMED BY

Dr. Lundemulder

HOSPITAL NAME

Southkent VH

REFERRING VET

Dr. Lundemulder

INVOICE

72222

DATE

3/4/26

Gallbladder

The gallbladder is small containing normal anechoic bile. Normal thickness and echogenic appearance of the wall. Normal size and appearance of the cystic and common bile duct.

Gastrointestinal

Normal appearance of the stomach, duodenum, small intestine, ileo-cecal junction, and colon with no loss of layering, 1:3 muscularis to mucosa ratio, normal wall thickness and peristaltic activity, and no distension of the lumen.

Pancreas

The visible sections of the pancreas are of normal size and echogenic appearance with a regular capsule. Normal echogenic appearance of the mesentery and fat surrounding the pancreas.

Free Abdomen

Normal mesenteric lymph nodes.

No ascites evident.

ULTRASONOGRAPHIC FINDINGS

- Normal ultrasound examination of the abdomen.

INTERPRETATION OF THE FINDINGS & FURTHER RECOMMENDATIONS

On this ultrasound there is no obvious etiology for the presenting clinical signs.

Further assessment (if not already done would be CBC and serum biochemistry), urine culture and survey thoracic radiographs.

Specific therapy would be dependent on an etiological diagnosis.



PATIENT

Chance Neitzel

SPECIES

Canine

BREED

Golden Retriever

SEX

Neutered male

AGE

12 years

WEIGHT

58 lbs

INTERPRETED BY

Remo Lobetti, BVSc,
MMedVet (Med),
PhD, Dipl. ECVIM

IMAGING PERFORMED BY

Dr. Lundemulder

HOSPITAL NAME

Southkent VH

REFERRING VET

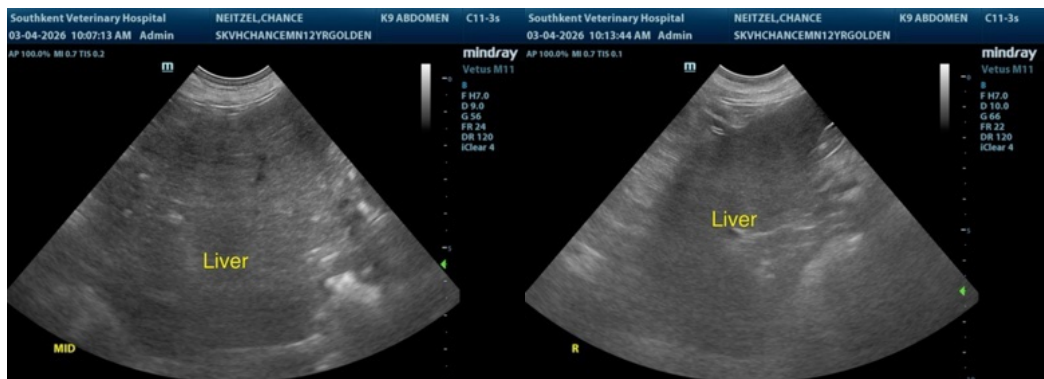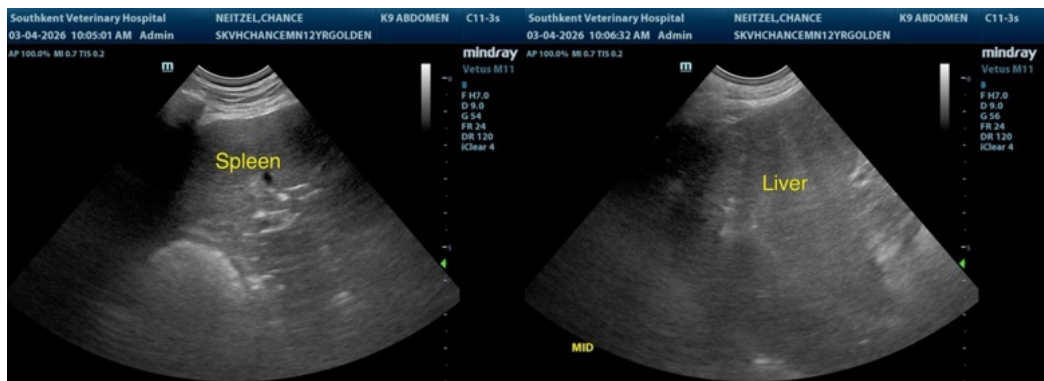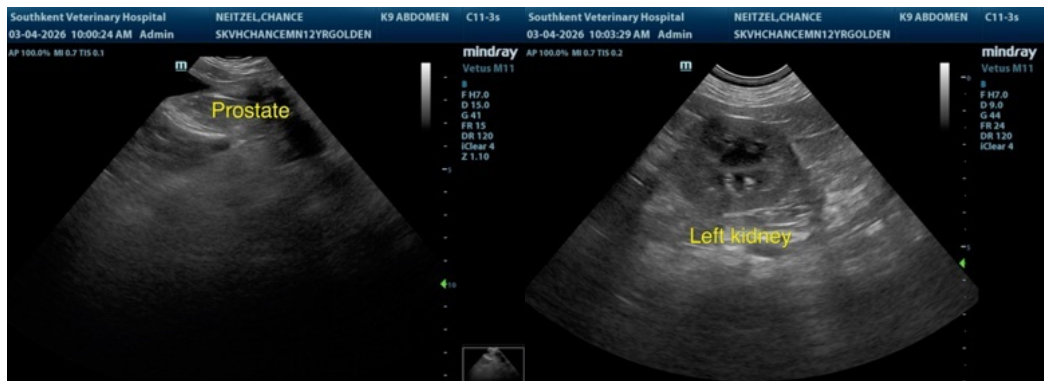
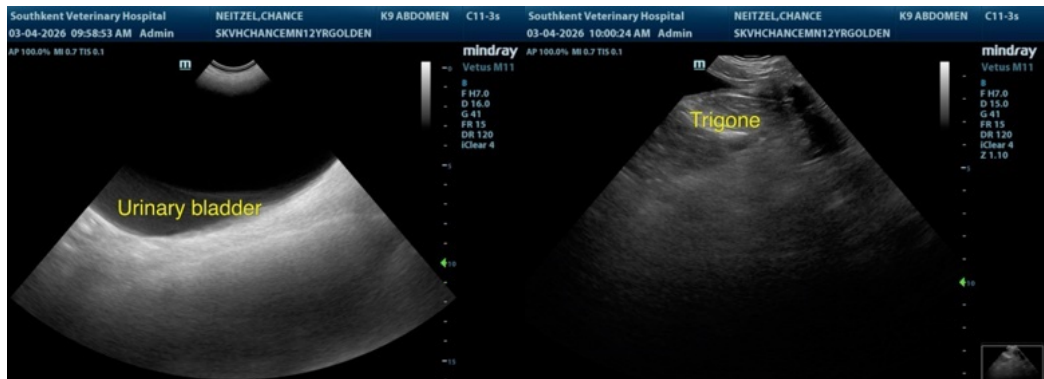
Dr. Lundemulder

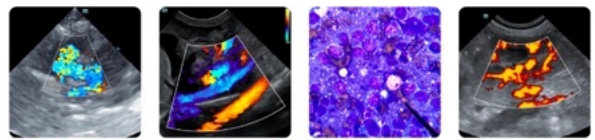
INVOICE

72222

DATE

3/4/26





PATIENT

Chance Neitzel

SPECIES

Canine

BREED

Golden Retriever

SEX

Neutered male

AGE

12 years

WEIGHT

58 lbs

INTERPRETED BY

Remo Lobetti, BVSc,
MMedVet (Med),
PhD, Dipl. ECVIM

IMAGING PERFORMED BY

Dr. Lundemulder

HOSPITAL NAME

Southkent VH

REFERRING VET

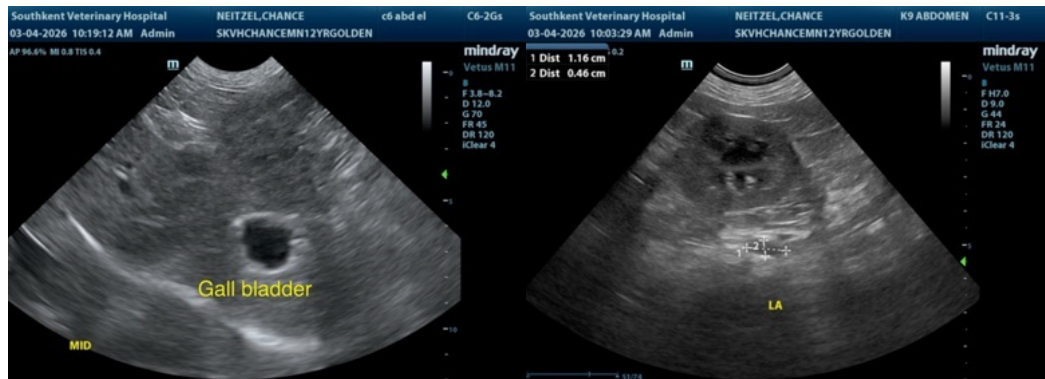
Dr. Lundemulder

INVOICE

72222

DATE

3/4/26



The information and recommendations provided are based on the images presented by the referring veterinarian/sonographer. No evaluation can be communicated regarding pathology that was not visible in the image/video clips provided.

Thank you for this referral. If the clinical or image interpretation does not parallel your findings or if I can be of any further assistance please contact me.

Remo Lobetti, BVSc, MMedVet (Med), PhD, Dipl. ECVIM (Internal Medicine)

info@sonopath.com