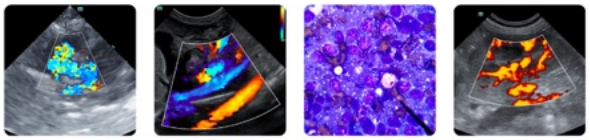

PATIENT
Tank Dorsett

SPECIES
Canine

BREED
French Bulldog

SEX
Neutered male

AGE
5 years

WEIGHT
23.4 lbs

INTERPRETED BY
Remo Lobetti, BVSc, MMedVet (Med), PhD, Dipl. ECVIM

IMAGING PERFORMED BY
Dr. Casper

HOSPITAL NAME
Hometown AH Florida

REFERRING VET
Dr. Hopkins

INVOICE
73934

DATE
3/31/26

PRESENTING CLINICAL SIGNS

- P presented for met check following right renal carcinoma removal (nephrectomy) 10-16-2025
- Rads 3/30/26 - No significant thoracic abnormalities are identified for patient age. No evidence of thoracic metastatic disease is noted.

ULTRASONOGRAPHIC EXAMINATION OF THE ABDOMEN

Urinary System

The urinary bladder is small with a normal thickness and smooth appearance of the wall. Normal anechoic urine with no sediment or uroliths evident.

Normal appearance of the trigone area, proximal urethra, and iliac blood vessels.

Normal appearance and size of the iliac lymph nodes. Ureters not visualized, which can be considered a normal finding.

Normal left renal size (left measured 5.3 cm), architecture, echogenic appearance, cortico-medullary differentiation, which maintains a 1:3 cortex to medulla ratio, pelvis, and capsule. No infarcts, mineralization or renoliths evident.

The right kidney is absent (previous nephrectomy). Normal appearance of the anatomical area of the right kidney.

The prostate is small and hypoechogenic.

Adrenal Glands

The left adrenal gland is not clearly visualized, but appears to be of normal shape, echogenic appearance and size. The right adrenal gland is not visualized.

Spleen

Normal size and echogenic appearance. Smooth homogenous parenchyma and regular curvilinear capsule. Normal volume of the splenic vasculature without any overt congestion or thrombosis evident. No inflammatory, neoplastic, infarction, or infiltrative changes evident. The spleen measured 1.5 cm in width.

Liver

Normal size, echogenic appearance, portal markings, and regular curvilinear capsule. No nodules or masses evident. Normal appearance of the hepatic and portal vasculature.

PATIENT

Tank Dorsett

SPECIES

Canine

BREED

French Bulldog

SEX

Neutered male

AGE

5 years

WEIGHT

23.4 lbs

INTERPRETED BY

Remo Lobetti, BVSc, MMedVet (Med), PhD, Dipl. ECVIM

IMAGING PERFORMED BY

Dr. Casper

HOSPITAL NAME

Hometown AH Florida

REFERRING VET

Dr. Hopkins

INVOICE

73934

DATE

3/31/26

Gallbladder

The gallbladder is full containing normal anechoic bile. Normal thickness and echogenic appearance of the wall. Normal size and appearance of the cystic and common bile duct.

Gastrointestinal

Normal appearance of the stomach, duodenum, small intestine, ileo-cecal junction, and colon with no loss of layering, 1:3 muscularis to mucosa ratio, normal wall thickness and peristaltic activity, and no distension of the lumen.

Pancreas

The visible sections of the pancreas are of normal size and echogenic appearance with a regular capsule. Normal echogenic appearance of the mesentery and fat surrounding the pancreas.

Free Abdomen

Normal mesenteric lymph nodes.

No ascites evident.

ULTRASONOGRAPHIC FINDINGS

- Normal ultrasound examination of the abdomen.

INTERPRETATION OF THE FINDINGS & FURTHER RECOMMENDATIONS

On this ultrasound there is no obvious evident of metastatic neoplasia.

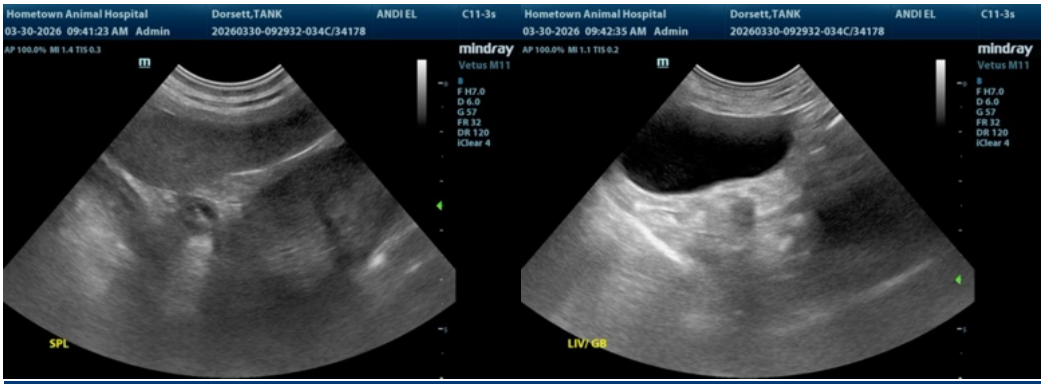

PATIENT

Tank Dorsett

SPECIES

Canine

BREED

French Bulldog

SEX

Neutered male

AGE

5 years

WEIGHT

23.4 lbs

INTERPRETED BY

Remo Lobetti, BVSc, MMedVet (Med), PhD, Dipl. ECVIM

IMAGING PERFORMED BY

Dr. Casper

HOSPITAL NAME

Hometown AH Florida

REFERRING VET

Dr. Hopkins

INVOICE

73934

DATE

3/31/26

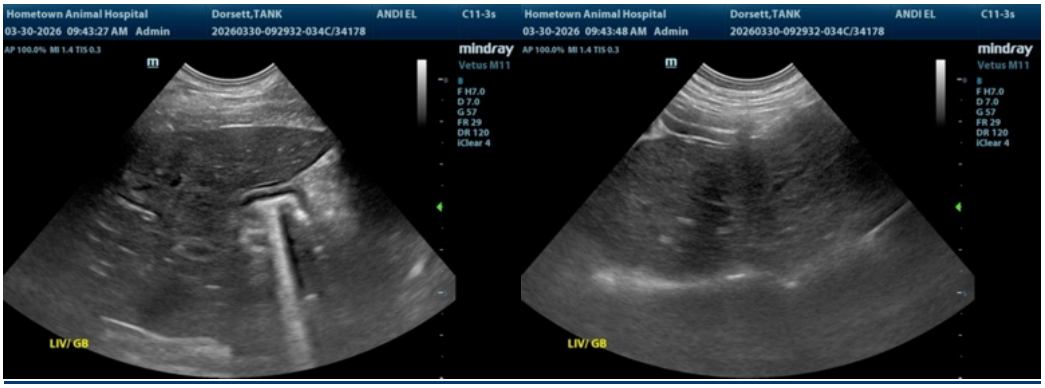

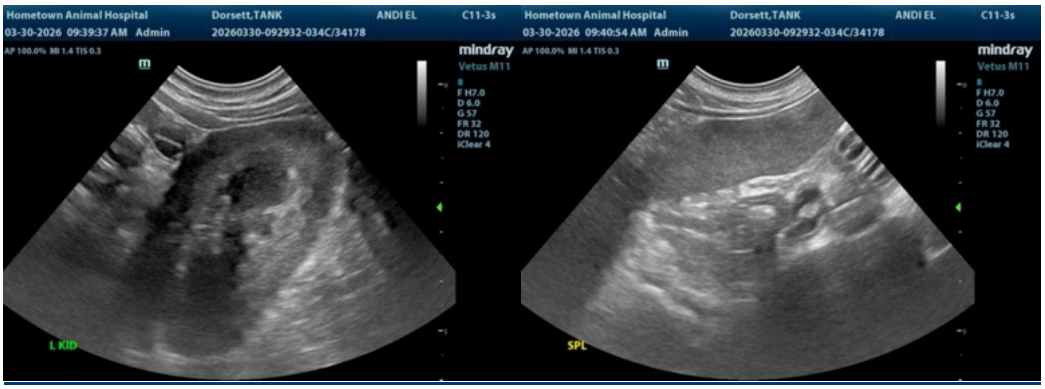

The information and recommendations provided are based on the images presented by the referring veterinarian/sonographer. No evaluation can be communicated regarding pathology that was not visible in the image/video clips provided.

Thank you for this referral. If the clinical or image interpretation does not parallel your findings or if I can be of any further assistance please contact me.

Remo Lobetti, BVSc, MMedVet (Med), PhD, Dipl. ECVIM (Internal Medicine)

info@sonopath.com