



PATIENT

Whiskey Moslow Cody

SPECIES

Canine

BREED

Labrador Retriever Mix

SEX

Spayed female

AGE

9 years

WEIGHT

48.4 lbs

INTERPRETED BY

Remo Lobetti, BVSc,
MMedVet (Med),
PhD, Dipl. ECVIM

IMAGING PERFORMED BY

Brandi Kurzowski

HOSPITAL NAME

Corfu VC

REFERRING VET

Dr. Beatty

INVOICE

72135

DATE

3/3/26

PRESENTING CLINICAL SIGNS

- P presented today for surgical removal of anal gland tumor. P has elevated liver enzymes on BW and o elects to pursue ultrasound since p is here today.
- 2/3/26 Chem- ALT 227 U/L, ALP- 719 U/L CBC- WNL 3/3/26 Chem- ALT 169 U/L, ALP 522 U/L, TBIL 1.4 mg/dL CBC- NSF

ULTRASONOGRAPHIC EXAMINATION OF THE ABDOMEN

Urinary System

The urinary bladder is full with a normal thickness and smooth appearance of the wall. Normal anechoic urine with no sediment or uroliths evident.

Normal appearance of the trigone area, proximal urethra, and iliac blood vessels.

Normal appearance and size of the iliac lymph nodes. Ureters not visualized, which can be considered a normal finding.

Normal renal size (left measured 4.3 cm, right measured 5.9 cm), architecture, echogenic appearance, cortico-medullary differentiation, which maintains a 1:3 cortex to medulla ratio, pelvis, and capsule. No infarcts, mineralization or renoliths evident. Normal color flow pattern is evident in both kidneys.

Adrenal Glands

The left adrenal gland is normal in shape, echogenic appearance, size, position, and appearance of the visible peri-adrenal vasculature. Left adrenal gland measured 0.53 cm and 0.54 cm in width. The right adrenal gland was not clearly visualized, but appears to be of normal shape, echogenic appearance and size.

Spleen

Normal size and echogenic appearance. Smooth homogenous parenchyma and regular curvilinear capsule. Normal volume of the splenic vasculature without any overt congestion or thrombosis evident. No inflammatory, neoplastic, infarction, or infiltrative changes evident. The spleen measures 1.6 cm in width.

Liver

Normal size, echogenic appearance, portal markings, and regular curvilinear capsule. No nodules or masses evident. Normal appearance of the hepatic and portal vasculature.



PATIENT

Whiskey Moslow Cody

SPECIES

Canine

BREED

Labrador Retriever Mix

SEX

Spayed female

AGE

9 years

WEIGHT

48.4 lbs

INTERPRETED BY

Remo Lobetti, BVSc,
MMedVet (Med),
PhD, Dipl. ECVIM

IMAGING PERFORMED BY

Brandi Kurzowski

HOSPITAL NAME

Corfu VC

REFERRING VET

Dr. Beatty

INVOICE

72135

DATE

3/3/26

Gallbladder

The gallbladder is full containing normal anechoic bile. Normal thickness and echogenic appearance of the wall. Normal size and appearance of the cystic and common bile duct.

Gastrointestinal

Normal appearance of the stomach, duodenum, small intestine, ileo-cecal junction, and colon with no loss of layering, 1:3 muscularis to mucosa ratio, normal wall thickness and peristaltic activity, and no distension of the lumen.

Pancreas

The visible sections of the pancreas are of normal size and echogenic appearance with a regular capsule. Normal echogenic appearance of the mesentery and fat surrounding the pancreas.

Free Abdomen

Normal mesenteric lymph nodes.

No ascites evident.

ULTRASONOGRAPHIC FINDINGS

- Normal ultrasound examination of the abdomen.

INTERPRETATION OF THE FINDINGS & FURTHER RECOMMENDATIONS

On this ultrasound there is no obvious evidence of metastatic neoplasia or any obvious etiology for the elevated liver enzyme activity.

Although the liver appears ultrasonographically normal, with the elevated liver enzyme activity an underlying hepatopathy such as reactive hyperplasia, vacuolar and metabolic should still be considered.

Infiltrative neoplasia and hepatitis would be unlikely differential diagnosis.

Further assessment of the elevated liver enzyme activity would be FNA cytology of the liver; however, a tru cut or wedge biopsy may be required for a final etiological diagnosis.

Symptomatic management that could be considered would be the use of Ursodiol with regular monitoring of liver enzyme activity.



PATIENT

Whiskey Moslow Cody

SPECIES

Canine

BREED

Labrador Retriever Mix

SEX

Spayed female

AGE

9 years

WEIGHT

48.4 lbs

INTERPRETED BY

Remo Lobetti, BVSc,
MMedVet (Med),
PhD, Dipl. ECVIM

IMAGING PERFORMED BY

Brandi Kurzowski

HOSPITAL NAME

Corfu VC

REFERRING VET

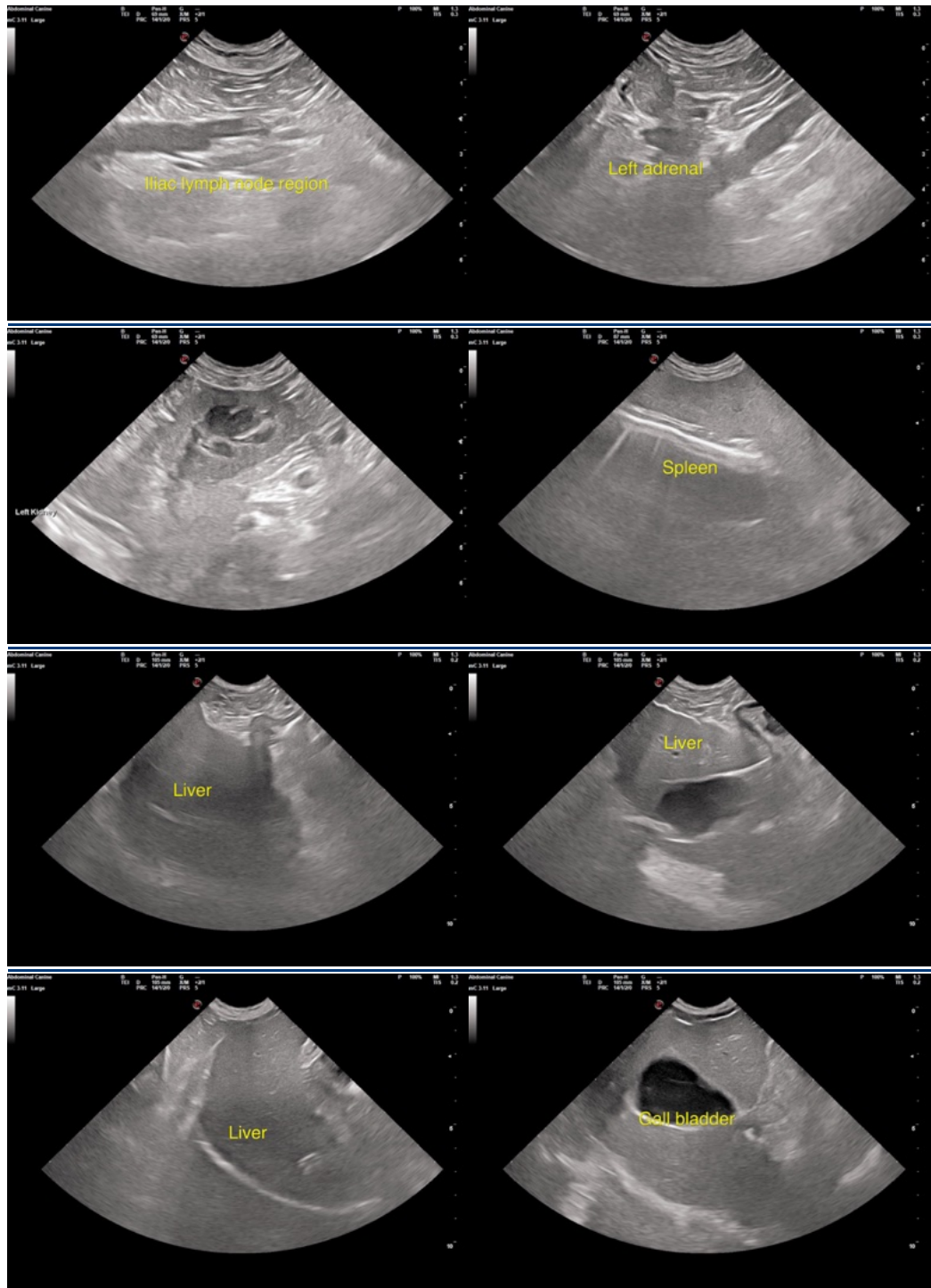
Dr. Beatty

INVOICE

72135

DATE

3/3/26



The information and recommendations provided are based on the images presented by the referring veterinarian/sonographer. No evaluation can be communicated regarding pathology that was not visible in the image/video clips provided.



PATIENT

Whiskey Moslow Cody

SPECIES

Canine

BREED

Labrador Retriever Mix

SEX

Spayed female

AGE

9 years

WEIGHT

48.4 lbs

INTERPRETED BY

Remo Lobetti, BVSc,
MMedVet (Med),
PhD, Dipl. ECVIM

IMAGING PERFORMED BY

Brandi Kurzowski

HOSPITAL NAME

Corfu VC

REFERRING VET

Dr. Beatty

INVOICE

72135

DATE

3/3/26

Thank you for this referral. If the clinical or image interpretation does not parallel your findings or if I can be of any further assistance please contact me.

Remo Lobetti, BVSc, MMedVet (Med), PhD, Dipl. ECVIM (Internal Medicine)

info@sonopath.com