



## PATIENT

Riley Ploep

## SPECIES

Canine

## BREED

Australian Shepherd

## SEX

Spayed female

## AGE

14 years

## WEIGHT

44 lbs

## INTERPRETED BY

Remo Lobetti, BVSc,  
MMedVet (Med),  
PhD, Dipl. ECVIM

## IMAGING PERFORMED BY

Dr. Coe

## HOSPITAL NAME

Riverside AC

## REFERRING VET

Dr. Cline

## INVOICE

73825

## DATE

3/27/26

## PRESENTING CLINICAL SIGNS

- Presented for COHAT. CBC showed mild non-regenerative anemia. Normal WBC/PLT. Chem revealed moderate azotemia (SDMA 18/Crea 2.9/USG 1.018), Hyperglobulinemia (4.7), and mild elevation of ALKP (353).
- No reported PU/PD. On Heartgard/Credelio. Occasional Trazodone for grooming. Eats Science Diet Chix/Barley - no reported appetite concerns/changes.
- Abnormal PE/Chem/CBC/UA Results: PE unremarkable. Moderate periodontal disease with halitosis. Abdomen tense/patient anxious. Moderate azotemia with low USG (1.018). Mild increased ALKP (353), Mild hyperglobulinemia. Mild-Moderate non-regenerative anemia (HCT 29%) - microcytic, normochromic. UAS: WBC ~10/hpf, no RBC, no bacteria, no crystals. Suspect non-hyaline casts. UPC: 0.83 = significant proteinuria (but some WBC sediment)

## ULTRASONOGRAPHIC EXAMINATION OF THE ABDOMEN

### Urinary System

The urinary bladder is small with a normal thickness and smooth appearance of the wall. Normal anechoic urine with no sediment or uroliths evident.

Normal appearance of the trigone area, proximal urethra, and iliac blood vessels.

Normal appearance and size of the iliac lymph nodes. Ureters not visualized, which can be considered a normal finding.

Normal renal size (left measured 4.8 cm, right measured 6.0 cm), increased echogenic appearance, some loss of cortico-medullary differentiation and a normal capsule. Mild, left-sided pyelectasia and normal right sided pelvis. No infarcts, mineralization or renoliths evident. Normal color flow pattern is evident in both kidneys.

### Adrenal Glands

Normal shape, echogenic appearance, size, position, and appearance of the visible peri-adrenal vasculature. Left adrenal gland measured 2.75 cm in length x 0.47 cm and 0.61 cm in width. The right adrenal gland measured 2.62 cm in length x 0.57 cm and 0.78 cm in width.

### Spleen

Normal size and echogenic appearance. Smooth homogenous parenchyma and regular curvilinear capsule. Normal volume of the splenic vasculature without any overt congestion or thrombosis evident. No inflammatory, neoplastic, infarction, or infiltrative changes evident. The spleen measured 1.6 cm in width.



## PATIENT

Riley Ploep

## SPECIES

Canine

## BREED

Australian Shepherd

## SEX

Spayed female

## AGE

14 years

## WEIGHT

44 lbs

## INTERPRETED BY

Remo Lobetti, BVSc,  
MMedVet (Med),  
PhD, Dipl. ECVIM

## IMAGING PERFORMED BY

Dr. Coe

## HOSPITAL NAME

Riverside AC

## REFERRING VET

Dr. Cline

## INVOICE

73825

## DATE

3/27/26

### *Liver*

Normal size, echogenic appearance, portal markings, and regular curvilinear capsule. No nodules or masses evident. Normal appearance of the hepatic and portal vasculature.

### *Gallbladder*

The gallbladder is small containing a small amount of non-adhered hyperechogenic sediment. Normal thickness and echogenic appearance of the wall. Normal size and appearance of the cystic and common bile duct.

### *Gastrointestinal*

Normal appearance of the stomach, duodenum, small intestine, ileo-cecal junction, and colon with no loss of layering, 1:3 muscularis to mucosa ratio, normal wall thickness and peristaltic activity, and no distension of the lumen.

### *Pancreas*

The visible sections of the pancreas are of normal size and echogenic appearance with a regular capsule. Normal echogenic appearance of the mesentery and fat surrounding the pancreas.

### *Free Abdomen*

Normal mesenteric lymph nodes.

No ascites evident.

## ULTRASONOGRAPHIC FINDINGS

- Renal disease.
- Gallbladder sediment.

## INTERPRETATION OF THE FINDINGS & FURTHER RECOMMENDATIONS

The appearance of the kidneys would be consistent with chronic kidney disease and in line with the patient's laboratory findings.

The gallbladder sediment can be considered an incidental finding.

The hyperglobulinemia is most likely secondary to the dental disease.

Further assessment of the renal disease if not already done would be blood pressure.



**PATIENT**

Riley Ploep

**SPECIES**

Canine

**BREED**

Australian Shepherd

**SEX**

Spayed female

**AGE**

14 years

**WEIGHT**

44 lbs

**INTERPRETED BY**

Remo Lobetti, BVSc,  
MMedVet (Med),  
PhD, Dipl. ECVIM

**IMAGING PERFORMED BY**

Dr. Coe

**HOSPITAL NAME**

Riverside AC

**REFERRING VET**

Dr. Cline

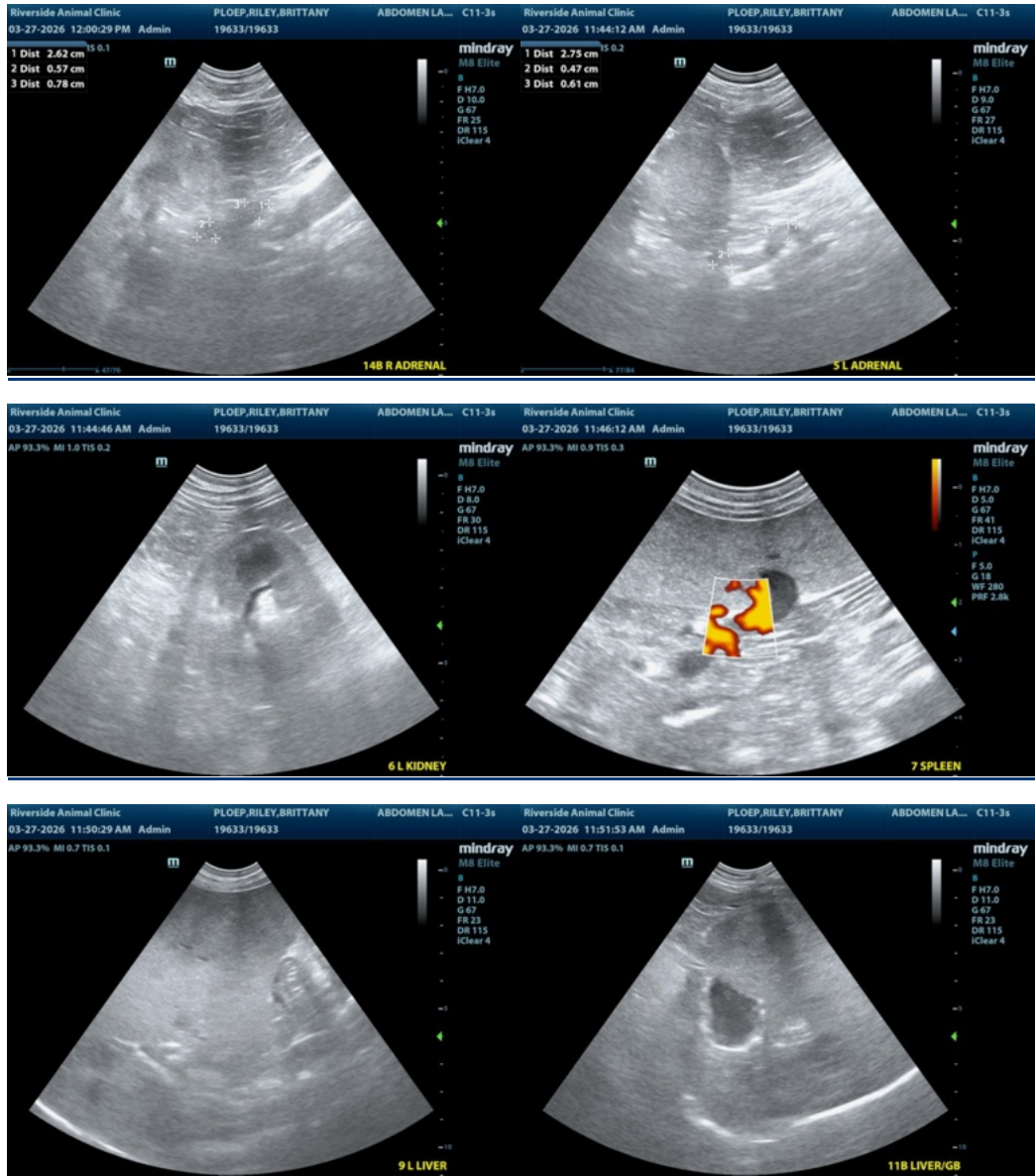
**INVOICE**

73825

**DATE**

3/27/26

Management of the renal disease would be feeding a renal diet, enteric phosphate binders as needed and either an ace inhibitor or receptor blocker for the proteinuria.





## PATIENT

Riley Ploep

## SPECIES

Canine

## BREED

Australian Shepherd

## SEX

Spayed female

## AGE

14 years

## WEIGHT

44 lbs

## INTERPRETED BY

Remo Lobetti, BVSc,  
MMedVet (Med),  
PhD, Dipl. ECVIM

## IMAGING PERFORMED BY

Dr. Coe

## HOSPITAL NAME

Riverside AC

## REFERRING VET

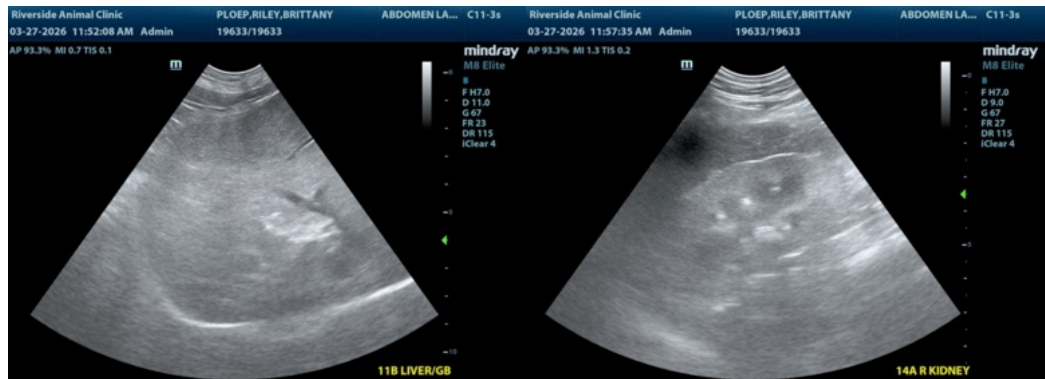Dr. Cline

## INVOICE

73825

## DATE

3/27/26



The information and recommendations provided are based on the images presented by the referring veterinarian/sonographer. No evaluation can be communicated regarding pathology that was not visible in the image/video clips provided.

Thank you for this referral. If the clinical or image interpretation does not parallel your findings or if I can be of any further assistance please contact me.

Remo Lobetti, BVSc, MMedVet (Med), PhD, Dipl. ECVIM (Internal Medicine)

[info@sonopath.com](mailto:info@sonopath.com)