



PATIENT

Kilo Gatz

SPECIES

Canine

BREED

Husky

SEX

Neutered male

AGE

5 years

WEIGHT

71 lbs

INTERPRETED BY

Remo Lobetti, BVSc,
MMedVet (Med),
PhD, Dipl. ECVIM

IMAGING PERFORMED BY

Jonathon Moss

HOSPITAL NAME

Harvest Hills VH

REFERRING VET

Dr. Garvin

INVOICE

73823

DATE

3/27/26

PRESENTING CLINICAL SIGNS

- Epileptic patient for about 3 to 4 years. Experiencing breakthrough seizures. Currently on phenobarbital 100mg SID, Keppra XR 750 mg + 500mg BID. History of atopy - controlled on cytopoint injections and eating hydrolyzed protein diet. History of elevated ALKP and now low ALB 2.4
- Superficial pyoderma on abdomen and inguinal region. Otherwise PE WNL

ULTRASONOGRAPHIC EXAMINATION OF THE ABDOMEN

Urinary System

The urinary bladder is small with a normal thickness and smooth appearance of the wall. Normal anechoic urine with no sediment or uroliths evident.

Normal appearance of the trigone area, proximal urethra, and iliac blood vessels.

Normal appearance and size of the iliac lymph nodes. Ureters not visualized, which can be considered a normal finding.

Normal renal size (left measured 7.0 cm, right measured 6.5 cm), architecture, echogenic appearance, cortico-medullary differentiation, which maintains a 1:3 cortex to medulla ratio, pelvis, and capsule. No infarcts, mineralization or renoliths evident.

The prostate is small and hypoechogenic measuring 1.1 cm in width.

Adrenal Glands

The left adrenal gland is normal in shape, echogenic appearance, size, position, and appearance of the visible peri-adrenal vasculature. Left adrenal gland measured 0.44 cm in width. The right adrenal gland was not clearly visualized, but appears to be of normal shape, echogenic appearance and size.

Spleen

Normal size and echogenic appearance. Smooth homogenous parenchyma and regular curvilinear capsule. Normal volume of the splenic vasculature without any overt congestion or thrombosis evident. No inflammatory, neoplastic, infarction, or infiltrative changes evident. The spleen measures 1.9 cm in width.

Liver

Normal size, echogenic appearance, portal markings, and regular curvilinear capsule. No nodules or masses evident. Normal appearance of the hepatic and portal vasculature.



PATIENT

Kilo Gatz

SPECIES

Canine

BREED

Husky

SEX

Neutered male

AGE

5 years

WEIGHT

71 lbs

INTERPRETED BY

Remo Lobetti, BVSc,
MMedVet (Med),
PhD, Dipl. ECVIM

IMAGING PERFORMED BY

Jonathon Moss

HOSPITAL NAME

Harvest Hills VH

REFERRING VET

Dr. Garvin

INVOICE

73823

DATE

3/27/26

Gallbladder

The gallbladder is small containing normal anechoic bile. Normal thickness and echogenic appearance of the wall. Normal size and appearance of the cystic and common bile duct.

Gastrointestinal

Normal appearance of the stomach, duodenum, small intestine, ileo-cecal junction, and colon with no loss of layering, 1:3 muscularis to mucosa ratio, normal wall thickness and peristaltic activity, and no distension of the lumen.

Pancreas

The visible sections of the pancreas are of normal size and echogenic appearance with a regular capsule. Normal echogenic appearance of the mesentery and fat surrounding the pancreas.

Free Abdomen

Normal mesenteric lymph nodes.

No ascites evident.

ULTRASONOGRAPHIC FINDINGS

- Normal ultrasound examination of the abdomen.

INTERPRETATION OF THE FINDINGS & FURTHER RECOMMENDATIONS

On this ultrasound there is no obvious etiology for the elevated ALP activity or the mild hypoalbuminemia.

The most likely etiology for the elevated ALP activity would be secondary to the phenobarbital therapy.

Possible etiologies for the hypoalbuminemia would be a negative acute phase response to the superficial pyoderma and possibly loss through the intestinal tract (low grade ulceration, intestinal parasites).



PATIENT

Kilo Gatz

SPECIES

Canine

BREED

Husky

SEX

Neutered male

AGE

5 years

WEIGHT

71 lbs

INTERPRETED BY

Remo Lobetti, BVSc,
MMedVet (Med),
PhD, Dipl. ECVIM

**IMAGING
PERFORMED BY**

Jonathon Moss

HOSPITAL NAME

Harvest Hills VH

REFERRING VET

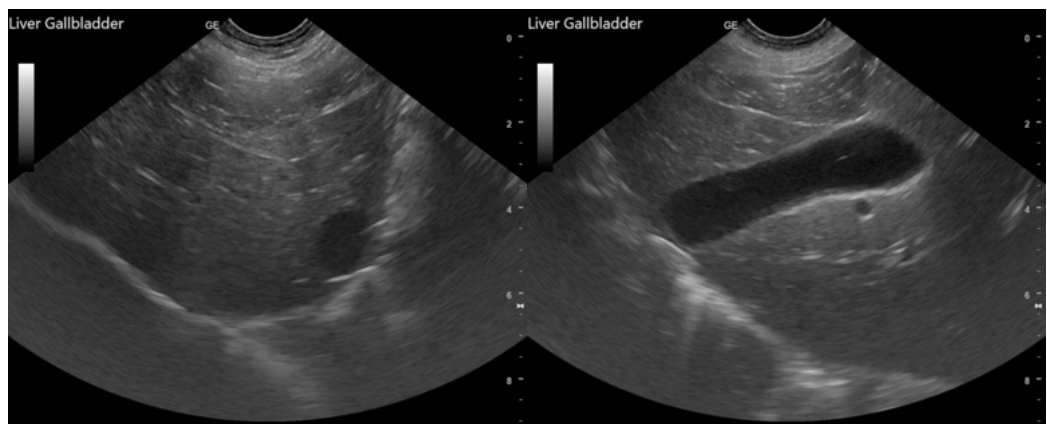
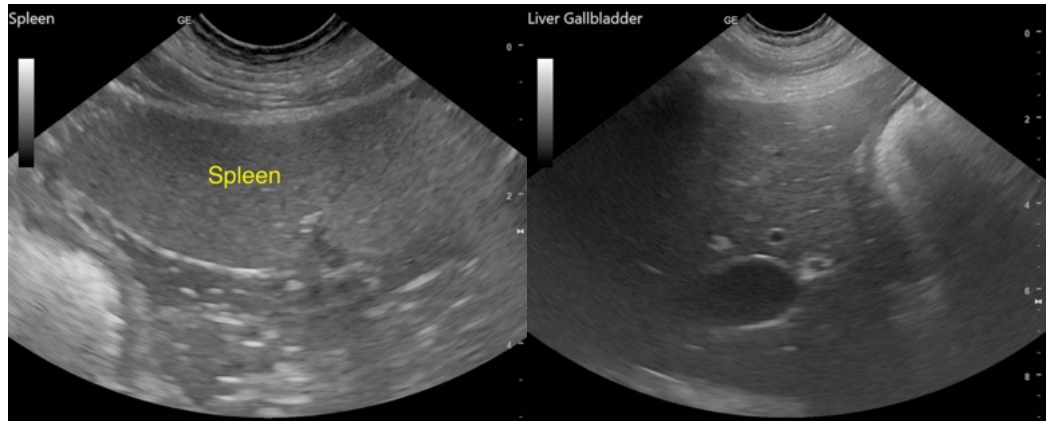
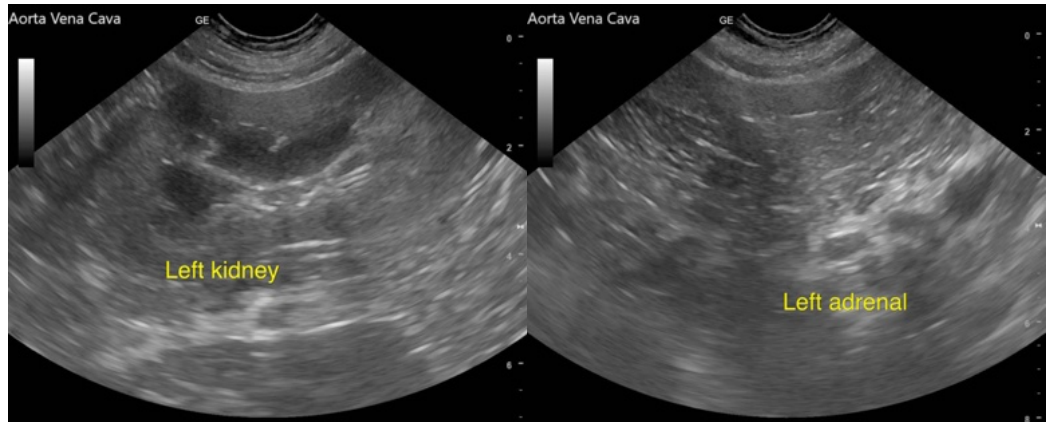
Dr. Garvin

INVOICE

73823

DATE

3/27/26





PATIENT

Kilo Gatz

SPECIES

Canine

BREED

Husky

SEX

Neutered male

AGE

5 years

WEIGHT

71 lbs

INTERPRETED BY

Remo Lobetti, BVSc,
MMedVet (Med),
PhD, Dipl. ECVIM

IMAGING PERFORMED BY

Jonathon Moss

HOSPITAL NAME

Harvest Hills VH

REFERRING VET

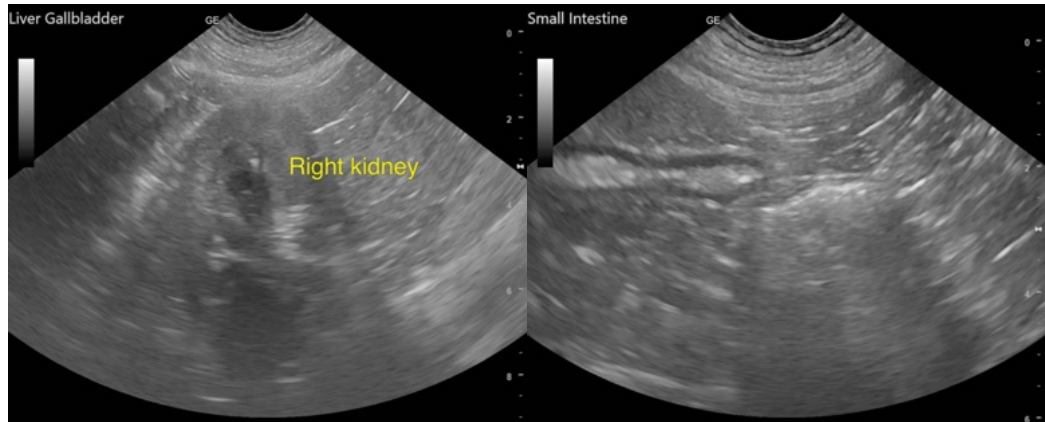
Dr. Garvin

INVOICE

73823

DATE

3/27/26



The information and recommendations provided are based on the images presented by the referring veterinarian/sonographer. No evaluation can be communicated regarding pathology that was not visible in the image/video clips provided.

Thank you for this referral. If the clinical or image interpretation does not parallel your findings or if I can be of any further assistance please contact me.

Remo Lobetti, BVSc, MMedVet (Med), PhD, Dipl. ECVIM (Internal Medicine)

info@sonopath.com