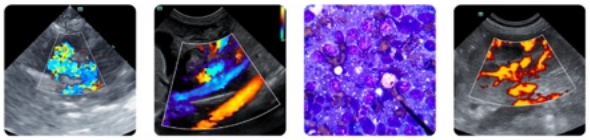



**PATIENT**
Ruby Barrows

**SPECIES**
Canine

**BREED**
Mini Golden

**SEX**
Spayed femlae

**AGE**
3 years

**WEIGHT**
22.1 lbs

**INTERPRETED BY**
Remo Lobetti, BVSc, MMedVet (Med), PhD, Dipl. ECVIM

**IMAGING PERFORMED BY**
Heather

**HOSPITAL NAME**
Animal Care Center of Flanders

**REFERRING VET**
Dr. Casulli

**INVOICE**
73870

**DATE**
3/26/26

## PRESENTING CLINICAL SIGNS

Diagnosed with stage 2 kidney dz and protein losing nephropathy

## ULTRASONOGRAPHIC EXAMINATION OF THE ABDOMEN

### *Urinary System*

The urinary bladder is full with a normal thickness and smooth appearance of the wall. Normal anechoic urine with no sediment or uroliths evident.

Normal appearance of the trigone area, proximal urethra, and iliac blood vessels.

Normal appearance and size of the iliac lymph nodes. Ureters not visualized, which can be considered a normal finding.

The kidneys are bilaterally small (left measured 3.4 cm, right measured 3.5 cm), increased echogenic appearance and complete loss of cortico-medullary differentiation. There is no obvious pyelectasia. The capsular is irregular. No infarcts, mineralization or renoliths evident. Poor color flow pattern is evident in both kidneys.

### *Adrenal Glands*

The left adrenal gland is normal in shape, echogenic appearance, size, position, and appearance of the visible peri-adrenal vasculature. Left adrenal gland measured 0.42 cm in width. The right adrenal gland was not visualized.

### *Spleen*

Normal size and echogenic appearance. Smooth homogenous parenchyma and regular curvilinear capsule. Normal volume of the splenic vasculature without any overt congestion or thrombosis evident. No inflammatory, neoplastic, infarction, or infiltrative changes evident. The spleen measured 1.1 cm in width.

### *Liver*

Normal size, echogenic appearance, portal markings, and regular curvilinear capsule. No nodules or masses evident. Normal appearance of the hepatic and portal vasculature.

### *Gallbladder*

The gallbladder is full containing a moderate amount of non-adhered, hyperechogenic sediment. Normal thickness and echogenic appearance of the wall. Normal size and appearance of the cystic and common bile duct.

**PATIENT**

Ruby Barrows

**SPECIES**

Canine

**BREED**

Mini Golden

**SEX**

Spayed femlae

**AGE**

3 years

**WEIGHT**

22.1 lbs

**INTERPRETED BY**

Remo Lobetti, BVSc, MMedVet (Med), PhD, Dipl. ECVIM

**IMAGING PERFORMED BY**

Heather

**HOSPITAL NAME**

Animal Care Center of Flanders

**REFERRING VET**

Dr. Casulli

**INVOICE**

73870

**DATE**

3/26/26

### *Gastrointestinal*

Normal appearance of the stomach, duodenum, small intestine, ileo-cecal junction, and colon with no loss of layering, 1:3 muscularis to mucosa ratio, normal wall thickness and peristaltic activity, and no distension of the lumen. A moderate amount of ingesta is present in the stomach compatible with a recent meal.

### *Pancreas*

The visible sections of the pancreas are of normal size and echogenic appearance with a regular capsule. Normal echogenic appearance of the mesentery and fat surrounding the pancreas.

### *Free Abdomen*

Normal mesenteric lymph nodes.

No ascites evident.

## ULTRASONOGRAPHIC FINDINGS

- Renal disease.

## INTERPRETATION OF THE FINDINGS & FURTHER RECOMMENDATIONS

The appearance of the kidneys is consistent with renal dysplasia.

Further assessment would be blood pressure (if not already done).

Management of the renal disease would be feeding a renal diet, use of enteric phosphate binders as needed and either an ace inhibitor or receptor blocker.

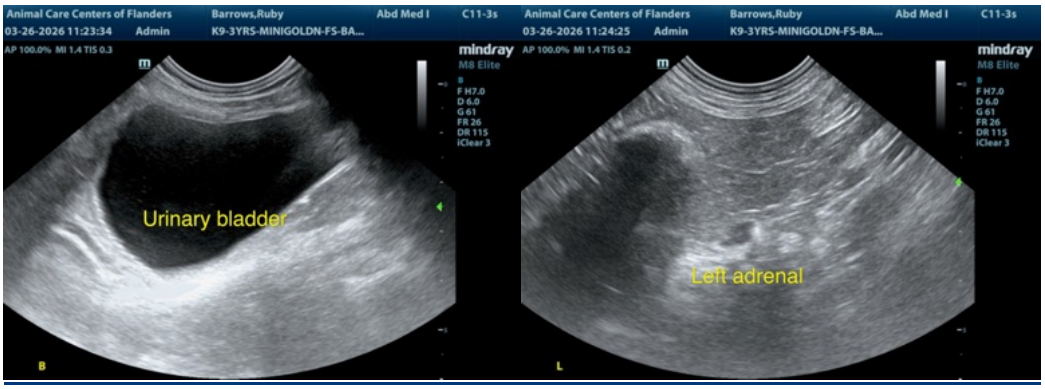

# SonoPath

FOSTERING THE ART OF VETERINARY MEDICINE™

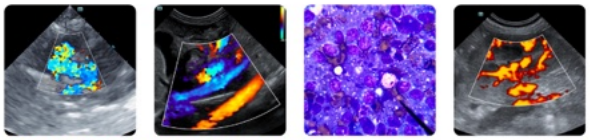

*Clinical Sonography & Telecytology*

*Educational Teleconsultation Services™*

SonoPath.com info@sonopath.com 1.800.838.4268

**PATIENT**

Ruby Barrows

**SPECIES**

Canine

**BREED**

Mini Golden

**SEX**

Spayed femlae

**AGE**

3 years

**WEIGHT**

22.1 lbs

**INTERPRETED BY**

Remo Lobetti, BVSc, MMedVet (Med), PhD, Dipl. ECVIM

**IMAGING PERFORMED BY**

Heather

**HOSPITAL NAME**

Animal Care Center of Flanders

**REFERRING VET**

Dr. Casulli

**INVOICE**

73870

**DATE**

3/26/26

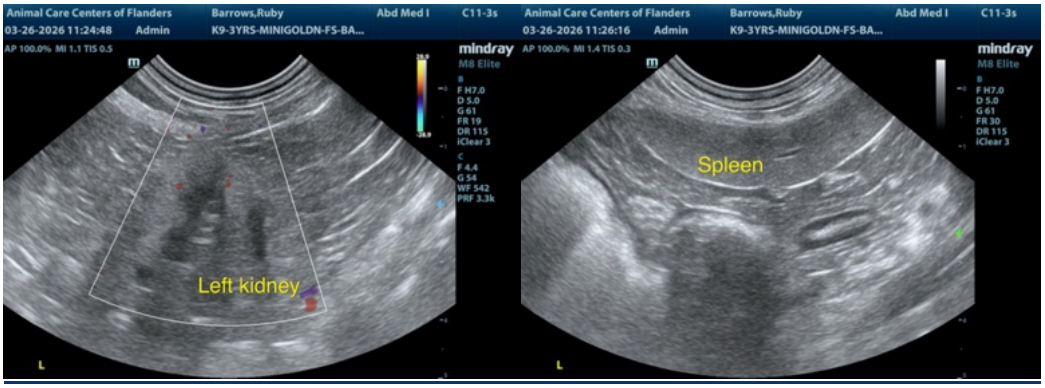


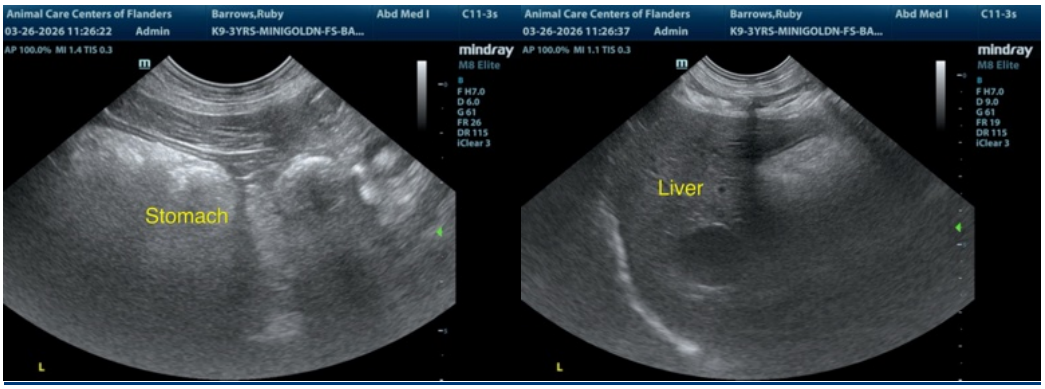


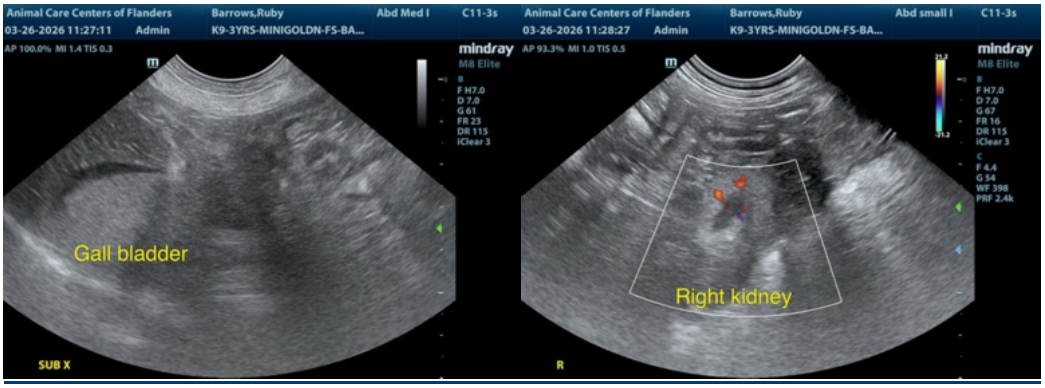


**The information and recommendations provided are based on the images presented by the referring veterinarian/sonographer. No evaluation can be communicated regarding pathology that was not visible in the image/video clips provided.**

Thank you for this referral. If the clinical or image interpretation does not parallel your findings or if I can be of any further assistance please contact me.

**Remo Lobetti**, BVSc, MMedVet (Med), PhD, Dipl. ECVIM (Internal Medicine)

info@sonopath.com