



PATIENT

Josie Ruvolo

SPECIES

Canine

BREED

French Bulldog

SEX

Spayed female

AGE

8 years

WEIGHT

30 lbs

INTERPRETED BY

Remo Lobetti, BVSc,
MMedVet (Med),
PhD, Dipl. ECVIM

IMAGING PERFORMED BY

Rebekah Keller

HOSPITAL NAME

Flanders VC

REFERRING VET

Dr. Gasparro

INVOICE

73871

DATE

3/26/26

PRESENTING CLINICAL SIGNS

- Elevated liver enzymes, ALT 350
- On Denamarin
- Previous U/S performed in Aug/2025 - Hepatopathy
- Aspirates obtained and submitted for cytology

ULTRASONOGRAPHIC EXAMINATION OF THE ABDOMEN

Urinary System

The urinary bladder is small with a normal thickness and smooth appearance of the wall. Normal anechoic urine with no sediment or uroliths evident.

Normal appearance of the trigone area, proximal urethra, and iliac blood vessels.

Normal appearance and size of the iliac lymph nodes. Ureters not visualized, which can be considered a normal finding.

Normal renal size (left measured 4.4 cm, right measured 4.4 cm), architecture, echogenic appearance, cortico-medullary differentiation, which maintains a 1:3 cortex to medulla ratio, pelvis, and capsule. No infarcts, mineralization or renoliths evident. A normal color flow pattern is evident.

Adrenal Glands

Normal shape, echogenic appearance, size, position, and appearance of the visible peri-adrenal vasculature. Left adrenal gland measured 1.77 cm in length x 0.35 cm and 0.33 cm in width. The right adrenal gland measured 2.11 cm in length x 0.54 cm and 0.43 cm in width.

Spleen

Normal size and echogenic appearance. Smooth homogenous parenchyma and regular curvilinear capsule. Normal volume of the splenic vasculature without any overt congestion or thrombosis evident. No inflammatory, neoplastic, infarction, or infiltrative changes evident. The spleen measured 2.2 cm in width.

Liver

Normal size with a diffuse, increased echogenic and coarse appearance, prominent portal markings, and regular curvilinear capsule. No nodules or masses evident. Normal appearance of the hepatic and portal vasculature.

Gallbladder



PATIENT

Josie Ruvolo

SPECIES

Canine

BREED

French Bulldog

SEX

Spayed female

AGE

8 years

WEIGHT

30 lbs

INTERPRETED BY

Remo Lobetti, BVSc,
MMedVet (Med),
PhD, Dipl. ECVIM

IMAGING PERFORMED BY

Rebekah Keller

HOSPITAL NAME

Flanders VC

REFERRING VET

Dr. Gasparro

INVOICE

73871

DATE

3/26/26

The gallbladder is full containing normal a small amount of non-adhered, hyperechogenic sediment. Normal thickness and echogenic appearance of the wall. Normal size and appearance of the cystic and common bile duct.

Gastrointestinal

Normal appearance of the stomach, duodenum, small intestine, ileo-cecal junction, and colon with no loss of layering, 1:3 muscularis to mucosa ratio, normal wall thickness and peristaltic activity, and no distension of the lumen.

Pancreas

The visible sections of the pancreas are of normal size and echogenic appearance with a regular capsule. Normal echogenic appearance of the mesentery and fat surrounding the pancreas.

Free Abdomen

Normal mesenteric lymph nodes.

No ascites evident.

ULTRASONOGRAPHIC FINDINGS

- Hepatopathy.
- Gallbladder sediment.

INTERPRETATION OF THE FINDINGS & FURTHER RECOMMENDATIONS

In comparison with the previous ultrasound, the appearance of the liver parenchyma is similar, but the portal markings have become more prominent.

Etiologies for the hepatopathy would be reactive hyperplasia, vacuolar and metabolic with cholangiohepatitis a possible differential diagnosis.

Infiltrative neoplasia would be a highly unlikely differential diagnosis.

Further assessment would be based on the pending cytology results. However, a tru cut or wedge biopsy may be required for a final etiological diagnosis.

Specific therapy would be dependent on an etiological diagnosis.

Symptomatic management would be to continue with the current therapy and to add Ursodiol with regular monitoring of liver enzyme activity.



PATIENT

Josie Ruvolo

SPECIES

Canine

BREED

French Bulldog

SEX

Spayed female

AGE

8 years

WEIGHT

30 lbs

INTERPRETED BY

Remo Lobetti, BVSc,
MMedVet (Med),
PhD, Dipl. ECVIM

**IMAGING
PERFORMED BY**

Rebekah Keller

HOSPITAL NAME

Flanders VC

REFERRING VET

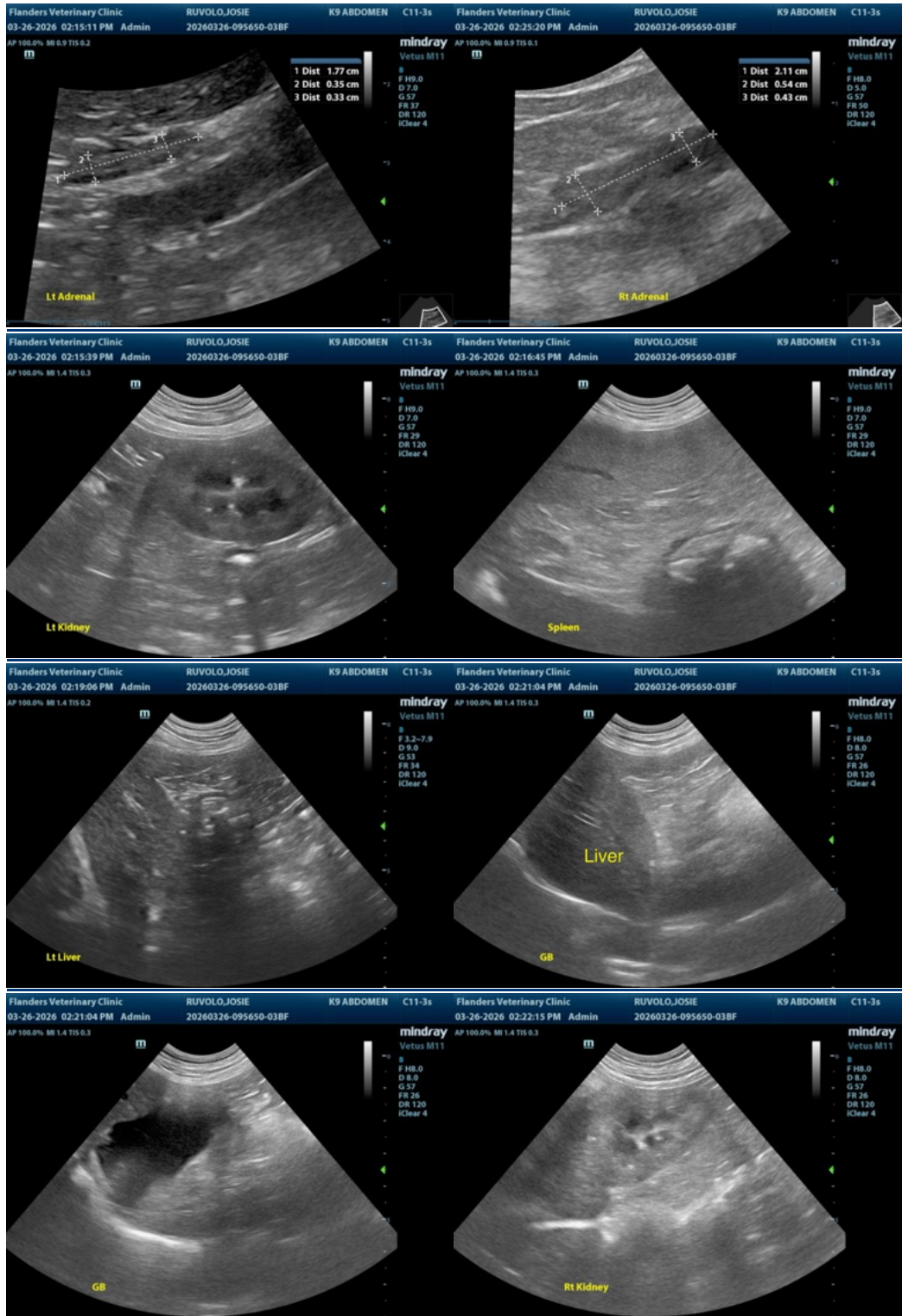
Dr. Gasparro

INVOICE

73871

DATE

3/26/26





PATIENT

Josie Ruvolo

SPECIES

Canine

BREED

French Bulldog

SEX

Spayed female

AGE

8 years

WEIGHT

30 lbs

INTERPRETED BY

Remo Lobetti, BVSc,
MMedVet (Med),
PhD, Dipl. ECVIM

IMAGING PERFORMED BY

Rebekah Keller

HOSPITAL NAME

Flanders VC

REFERRING VET

Dr. Gasparro

INVOICE

73871

DATE

3/26/26

The information and recommendations provided are based on the images presented by the referring veterinarian/sonographer. No evaluation can be communicated regarding pathology that was not visible in the image/video clips provided.

Thank you for this referral. If the clinical or image interpretation does not parallel your findings or if I can be of any further assistance please contact me.

Remo Lobetti, BVSc, MMedVet (Med), PhD, Dipl. ECVIM (Internal Medicine)

info@sonopath.com