



PATIENT

Benson Pirrotta

SPECIES

Canine

BREED

Bichon Frise Shih Tzu

SEX

Neutered male

AGE

3 years

WEIGHT

19 lbs

INTERPRETED BY

Remo Lobetti, BVSc,
MMedVet (Med),
PhD, Dipl. ECVIM

IMAGING PERFORMED BY

Dr. Jeremiah Gabriel

HOSPITAL NAME

Central Jersey AH

REFERRING VET

Dr. Gabriel

INVOICE

73807

DATE

3/25/26

PRESENTING CLINICAL SIGNS

- Vomited 5 times, not eating. No pooping for 24 hours
- Owner declined blood work

ULTRASONOGRAPHIC EXAMINATION OF THE ABDOMEN

Urinary System

The urinary bladder is small with a normal thickness and smooth appearance of the wall. Normal anechoic urine with no sediment or uroliths evident.

Normal appearance of the trigone area, proximal urethra, and iliac blood vessels.

Normal appearance and size of the iliac lymph nodes. Ureters not visualized, which can be considered a normal finding.

Normal left renal size (4.4 cm), architecture, echogenic appearance, cortico-medullary differentiation, which maintains a 1:3 cortex to medulla ratio, pelvis, and capsule. No infarcts, mineralization or renoliths evident.

The right kidney was not visualized.

The prostate is small and hypoechogenic.

Adrenal Glands

The left adrenal gland is normal in shape, echogenic appearance, size, position, and appearance of the visible peri-adrenal vasculature. Left adrenal gland measured 0.37 cm and 0.35 cm in width. The right adrenal gland was not visualized.

Spleen

Normal size and echogenic appearance. Smooth homogenous parenchyma and regular curvilinear capsule. Normal volume of the splenic vasculature without any overt congestion or thrombosis evident. No inflammatory, neoplastic, infarction, or infiltrative changes evident. The spleen measured 1.2 cm in width.

Liver

Normal size, echogenic appearance, portal markings, and regular curvilinear capsule. No nodules or masses evident. Normal appearance of the hepatic and portal vasculature.



PATIENT

Benson Pirrotta

SPECIES

Canine

BREED

Bichon Frise Shih Tzu

SEX

Neutered male

AGE

3 years

WEIGHT

19 lbs

INTERPRETED BY

Remo Lobetti, BVSc,
MMedVet (Med),
PhD, Dipl. ECVIM

IMAGING PERFORMED BY

Dr. Jeremiah Gabriel

HOSPITAL NAME

Central Jersey AH

REFERRING VET

Dr. Gabriel

INVOICE

73807

DATE

3/25/26

Gallbladder

The gallbladder is full containing normal anechoic bile. Normal thickness and echogenic appearance of the wall. Normal size and appearance of the cystic and common bile duct.

Gastrointestinal

Normal appearance of the stomach, duodenum, small intestine, ileo-cecal junction, and colon with no loss of layering, 1:3 muscularis to mucosa ratio, normal wall thickness and peristaltic activity, and no distension of the lumen. A small amount of ingesta and gas present in the stomach.

Pancreas

The visible sections of the pancreas are of normal size and echogenic appearance with a regular capsule. Normal echogenic appearance of the mesentery and fat surrounding the pancreas.

Free Abdomen

Normal mesenteric lymph nodes.

No ascites evident.

ULTRASONOGRAPHIC FINDINGS

- Normal ultrasound examination of the abdomen.

INTERPRETATION OF THE FINDINGS & FURTHER RECOMMENDATIONS

Although the presence of ingesta within the stomach may merely be an incidental finding, with the presenting clinical signs, small gastric foreign body should still be considered.

Although the most likely diagnosis would be a non-specific gastritis such as dietary indiscretion, toxins and viral.

Initial management would be fluid therapy and correction of any electrolyte anomalies if present, antiemetics and feeding small frequent meals of a low fat intestinal type diet.

Repeating the ultrasound after 18-24 hours would be recommended and if there is still no change in the appearance of the ingesta within the stomach, then a gastric foreign body would be an important consideration, possibly necessitating a laparotomy.



PATIENT

Benson Pirrotta

SPECIES

Canine

BREED

Bichon Frise Shih Tzu

SEX

Neutered male

AGE

3 years

WEIGHT

19 lbs

INTERPRETED BY

Remo Lobetti, BVSc,
MMedVet (Med),
PhD, Dipl. ECVIM

**IMAGING
PERFORMED BY**

Dr. Jeremiah Gabriel

HOSPITAL NAME

Central Jersey AH

REFERRING VET

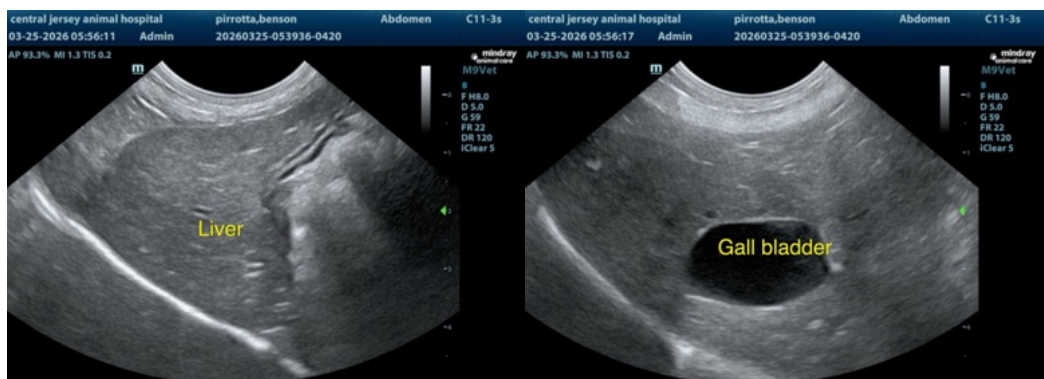
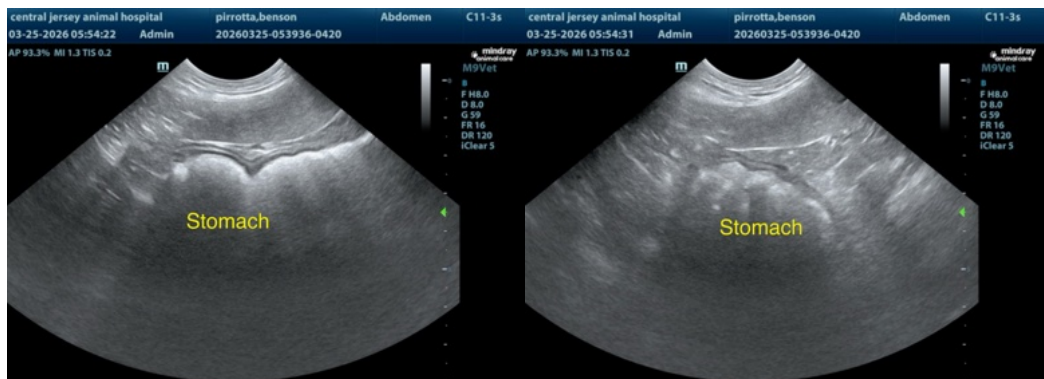
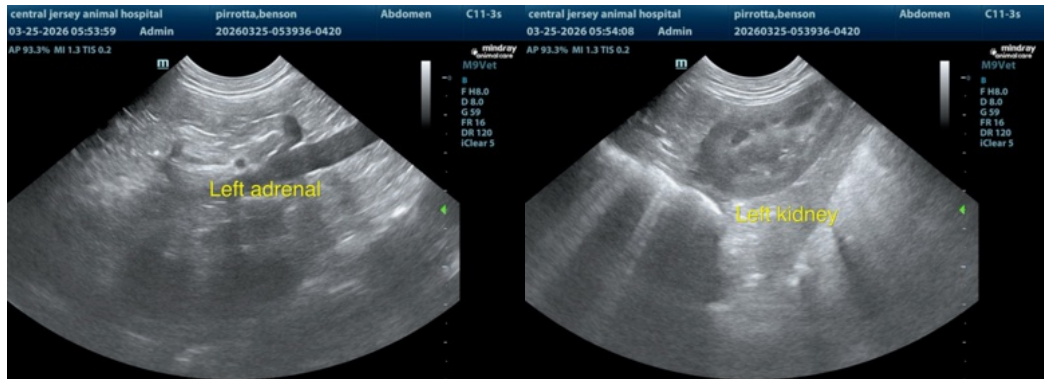
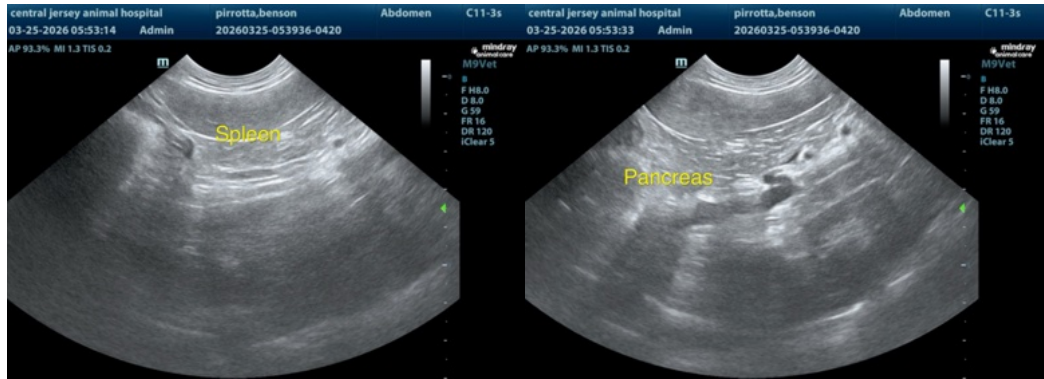
Dr. Gabriel

INVOICE

73807

DATE

3/25/26





PATIENT

Benson Pirrotta

SPECIES

Canine

BREED

Bichon Frise Shih Tzu

SEX

Neutered male

AGE

3 years

WEIGHT

19 lbs

INTERPRETED BY

Remo Lobetti, BVSc,
MMedVet (Med),
PhD, Dipl. ECVIM

IMAGING PERFORMED BY

Dr. Jeremiah Gabriel

HOSPITAL NAME

Central Jersey AH

REFERRING VET

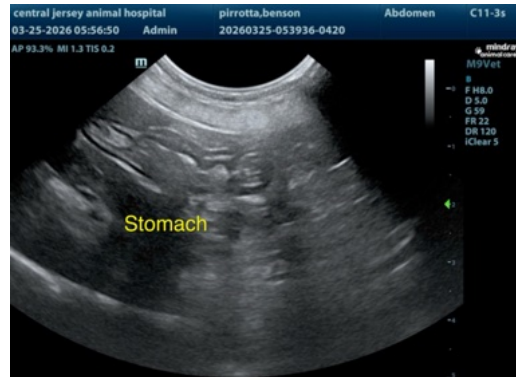Dr. Gabriel

INVOICE

73807

DATE

3/25/26



The information and recommendations provided are based on the images presented by the referring veterinarian/sonographer. No evaluation can be communicated regarding pathology that was not visible in the image/video clips provided.

Thank you for this referral. If the clinical or image interpretation does not parallel your findings or if I can be of any further assistance please contact me.

Remo Lobetti, BVSc, MMedVet (Med), PhD, Dipl. ECVIM (Internal Medicine)

info@sonopath.com