

PATIENT

Ozzy McMahan

SPECIES

Canine

BREED

Pug

SEX

Neutered male

AGE

16 years

WEIGHT

19 lbs

INTERPRETED BY

Remo Lobetti, BVSc,
MMedVet (Med),
PhD, Dipl. ECVIM

IMAGING PERFORMED BY

Keisha Smitley, CVT

HOSPITAL NAME

Geary VS

REFERRING VET

Dr. Geary

INVOICE

73716

DATE

3/23/26

PRESENTING CLINICAL SIGNS

- Patient is here today for blood in urine despite being on Clavamox
- Patient is urinating very bloody urine with clots present
- Patient is paralyzed
- Hematuria Paralyzed in rear legs

ULTRASONOGRAPHIC EXAMINATION OF THE ABDOMEN

Urinary System

The urinary bladder is small with a moderate amount of gas with a thickened and irregular appearance of the wall measuring up to 0.8 cm. Normal anechoic urine with no obvious sediment.

Normal appearance of the trigone area.

ULTRASONOGRAPHIC FINDINGS

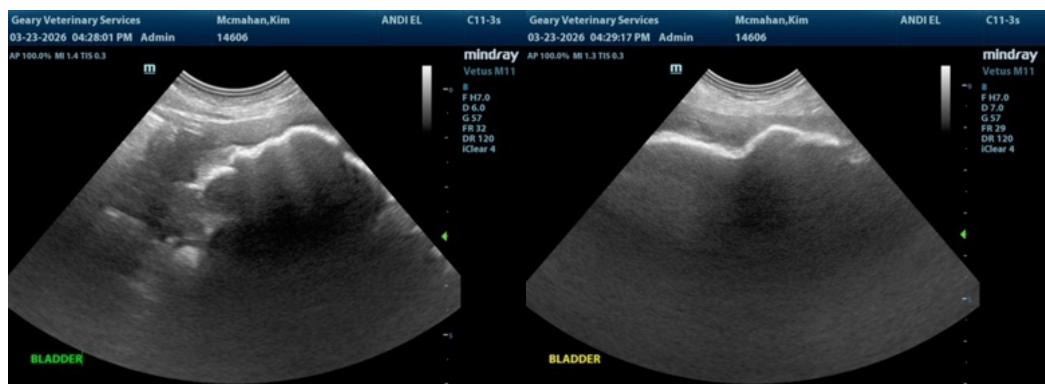- Emphysematous cystitis.

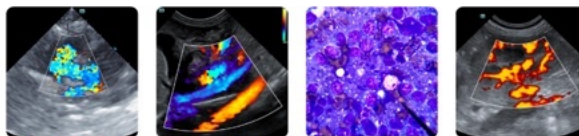
INTERPRETATION OF THE FINDINGS & FURTHER RECOMMENDATIONS

Emphysematous cystitis and hematuria can be ascribed to bacterial infection secondary to urine retention.

Further assessment would be urinalysis and urine culture.

Antibiotic therapy needs to be based on culture and sensitivity results.





PATIENT

Ozzy McMahan

SPECIES

Canine

BREED

Pug

SEX

Neutered male

AGE

16 years

WEIGHT

19 lbs

INTERPRETED BY

Remo Lobetti, BVSc,
MMedVet (Med),
PhD, Dipl. ECVIM

IMAGING PERFORMED BY

Keisha Smitley, CVT

HOSPITAL NAME

Geary VS

REFERRING VET

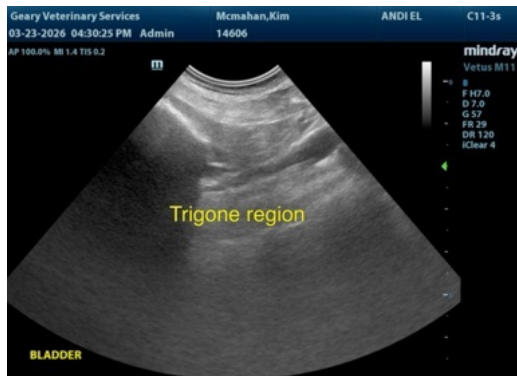Dr. Geary

INVOICE

73716

DATE

3/23/26



The information and recommendations provided are based on the images presented by the referring veterinarian/sonographer. No evaluation can be communicated regarding pathology that was not visible in the image/video clips provided.

Thank you for this referral. If the clinical or image interpretation does not parallel your findings or if I can be of any further assistance please contact me.

Remo Lobetti, BVSc, MMedVet (Med), PhD, Dipl. ECVIM (Internal Medicine)

info@sonopath.com