



## PATIENT

Rita Horton

## SPECIES

Feline

## BREED

Domestic Shorthair

## SEX

Spayed female

## AGE

11 years

## WEIGHT

7.2 lbs

## INTERPRETED BY

Remo Lobetti, BVSc,  
MMedVet (Med),  
PhD, Dipl. ECVIM

## IMAGING PERFORMED BY

Dr. Mack

## HOSPITAL NAME

Northside VC

## REFERRING VET

Dr. Mack

## INVOICE

73611

## DATE

3/19/26

## PRESENTING CLINICAL SIGNS

- Patient is a diabetic for 2 years
- having chronic diarrhea, weight loss and increased urination
- 1/24/26 WBC 18.82, Neu 13.30, Mono 0.92, BASO 0.31, Glucose 69, Glob 5.8 -2/28/26  
Glucose 414

## ULTRASONOGRAPHIC EXAMINATION OF THE ABDOMEN

### *Urinary System*

The urinary bladder is full with a normal thickness and smooth appearance of the wall. Normal anechoic urine with no sediment or uroliths evident.

Normal appearance of the trigone area, proximal urethra, and iliac blood vessels.

Normal appearance and size of the iliac lymph nodes. Ureters not visualized, which can be considered a normal finding.

Normal renal size (left measured 3.2 cm, right measured 3.8 cm), architecture, echogenic appearance, cortico-medullary differentiation, which maintains a 1:3 cortex to medulla ratio, pelvis, and capsule. No infarcts, mineralization or renoliths evident.

### *Adrenal Glands*

The adrenal glands were not visualized.

### *Spleen*

Normal size and echogenic appearance. Smooth homogenous parenchyma and regular curvilinear capsule. Normal volume of the splenic vasculature without any overt congestion or thrombosis evident. No inflammatory, neoplastic, infarction, or infiltrative changes evident. The spleen measured 0.6 cm in width.

### *Liver*

Normal size, echogenic appearance, portal markings, and regular curvilinear capsule. No nodules or masses evident. Normal appearance of the hepatic and portal vasculature.

### *Gallbladder*

The gallbladder is full containing normal anechoic bile. Normal thickness and echogenic appearance of the wall. Normal size and appearance of the cystic and common bile duct.



## PATIENT

Rita Horton

## SPECIES

Feline

## BREED

Domestic Shorthair

## SEX

Spayed female

## AGE

11 years

## WEIGHT

7.2 lbs

## INTERPRETED BY

Remo Lobetti, BVSc,  
MMedVet (Med),  
PhD, Dipl. ECVIM

## IMAGING PERFORMED BY

Dr. Mack

## HOSPITAL NAME

Northside VC

## REFERRING VET

Dr. Mack

## INVOICE

73611

## DATE

3/19/26

## *Gastrointestinal*

Normal appearance of the stomach, duodenum, ileo-cecal junction, and colon with no loss of layering, 1:3 muscularis to mucosa ratio, normal wall thickness and peristaltic activity, and no distension of the lumen. Segmental thickening of the small intestine (up to 0.36 cm) with no loss of layering, but with an increase in the muscularis to mucosa ratio, normal peristaltic activity and no distension of the lumen.

## *Pancreas*

The visible sections of the pancreas are of normal size and echogenic appearance with a regular capsule. Normal echogenic appearance of the mesentery and fat surrounding the pancreas.

## *Free Abdomen*

Normal mesenteric lymph nodes.

No ascites evident.

## ULTRASONOGRAPHIC FINDINGS

- Enteropathy

## INTERPRETATION OF THE FINDINGS & FURTHER RECOMMENDATIONS

Etiologies for the enteropathy would be parasitic enteritis, dietary hypersensitivity and inflammatory bowel disease with emerging lymphoma a possible differential diagnosis.

Exocrine pancreatic insufficiency would be a possible differential diagnosis.

Further assessment would be fecal analysis, cobalamin, folate and TLI assay and endoscopy of the upper GI tract with biopsies.

Specific therapy would be dependent on an etiological diagnosis. Symptomatic management that can be considered would be feeding a novel protein/hypoallergenic diet, course of Fenbendazole, cobalamin supplementation and if there is still not a satisfactory improvement then Budesonide would be recommended. The presence of the severe hyperglycemia and polydipsia could be indicative of pro diabetic control. Further assessment would be fructosamine and possibly a glucose curve.



### PATIENT

Rita Horton

### SPECIES

Feline

### BREED

Domestic Shorthair

### SEX

Spayed female

### AGE

11 years

### WEIGHT

7.2 lbs

### INTERPRETED BY

Remo Lobetti, BVSc,  
MMedVet (Med),  
PhD, Dipl. ECVIM

### IMAGING PERFORMED BY

Dr. Mack

### HOSPITAL NAME

Northside VC

### REFERRING VET

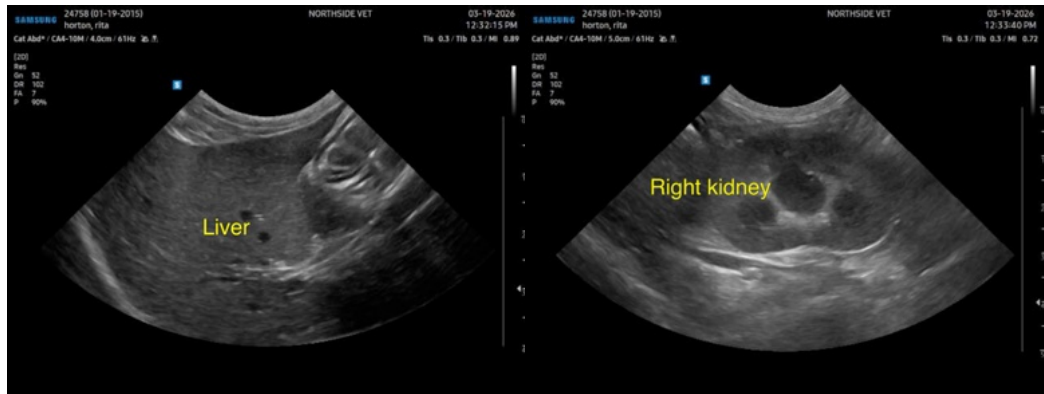
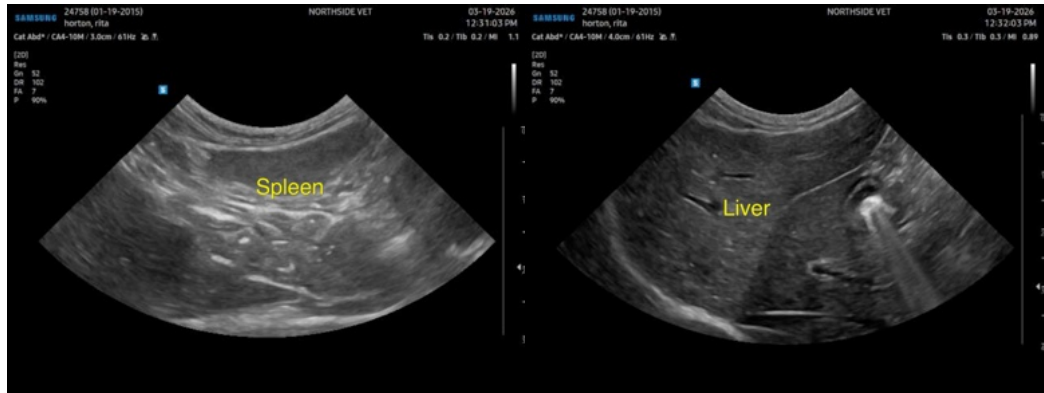
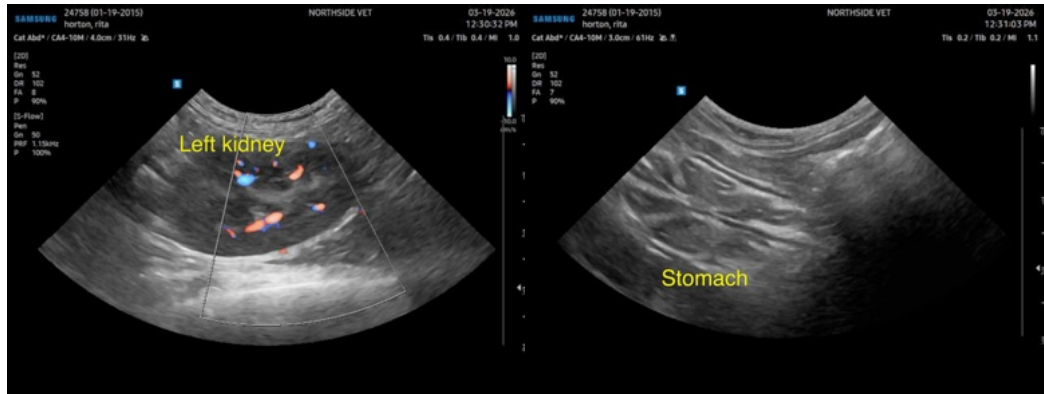
Dr. Mack

### INVOICE

73611

### DATE

3/19/26





## PATIENT

Rita Horton

## SPECIES

Feline

## BREED

Domestic Shorthair

## SEX

Spayed female

## AGE

11 years

## WEIGHT

7.2 lbs

## INTERPRETED BY

Remo Lobetti, BVSc,  
MMedVet (Med),  
PhD, Dipl. ECVIM

## IMAGING PERFORMED BY

Dr. Mack

## HOSPITAL NAME

Northside VC

## REFERRING VET

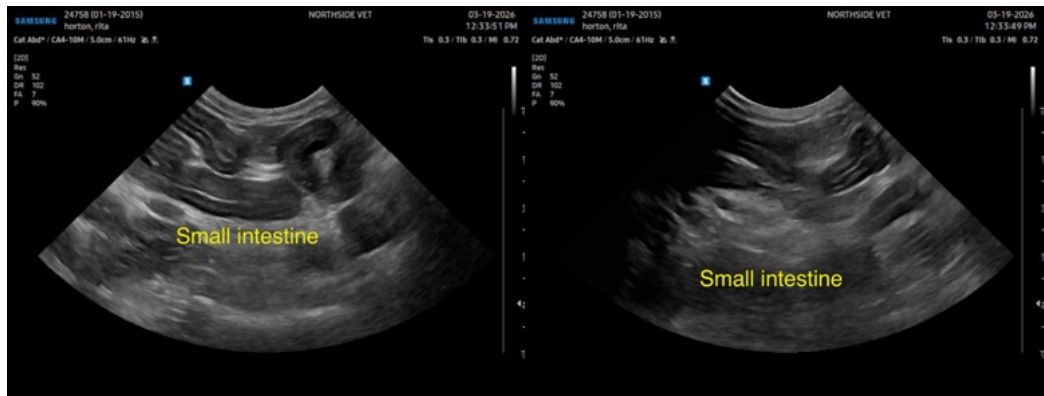
Dr. Mack

## INVOICE

73611

## DATE

3/19/26



The information and recommendations provided are based on the images presented by the referring veterinarian/sonographer. No evaluation can be communicated regarding pathology that was not visible in the image/video clips provided.

Thank you for this referral. If the clinical or image interpretation does not parallel your findings or if I can be of any further assistance please contact me.

Remo Lobetti, BVSc, MMedVet (Med), PhD, Dipl. ECVIM (Internal Medicine)

[info@sonopath.com](mailto:info@sonopath.com)