



## PATIENT

Bentley Diaz

## SPECIES

Canine

## BREED

Australian Shepherd

## SEX

Neutered male

## AGE

9 years

## WEIGHT

39 lbs

## INTERPRETED BY

Remo Lobetti, BVSc,  
MMedVet (Med),  
PhD, Dipl. ECVIM

## IMAGING PERFORMED BY

Julia Bakker, DVM

## HOSPITAL NAME

Orange Blossom  
Veterinary Imaging

## REFERRING VET

Dr. Sanchez

## INVOICE

734

## DATE

3/17/26

## PRESENTING CLINICAL SIGNS

- CONCERNED FOR POSSIBLE MASS ON LIVER

## ULTRASONOGRAPHIC EXAMINATION OF THE ABDOMEN

### *Urinary System*

The urinary bladder is full with a normal thickness and smooth appearance of the wall. Normal anechoic urine with no sediment or uroliths evident.

Normal appearance of the trigone area, proximal urethra, and iliac blood vessels.

Normal appearance and size of the iliac lymph nodes. Ureters not visualized, which can be considered a normal finding.

Normal renal size (left measured 5.5 cm, right measured 5.8 cm), architecture, echogenic appearance, cortico-medullary differentiation, which maintains a 1:3 cortex to medulla ratio, pelvis, and capsule. No infarcts, mineralization or renoliths evident. Normal color flow pattern is evident in both kidneys.

The prostate is small and hypoechogenic.

### *Adrenal Glands*

Normal shape, echogenic appearance, size, position, and appearance of the visible peri-adrenal vasculature. Left adrenal gland measured 2.41 cm x 0.59 cm and 0.57 cm in width. The right adrenal gland measured 2.17 cm in length x 0.47 cm and 0.92 cm in width.

### *Spleen*

Normal size and echogenic appearance. Smooth homogenous parenchyma and regular curvilinear capsule. Normal volume of the splenic vasculature without any overt congestion or thrombosis evident. Focal, hypoechogenic, non-vascularized parenchymal nodule was noted in the body of the spleen measuring 0.6 x 0.8 cm in size. The spleen measured 1.5 cm in width.

### *Liver*

Normal size, echogenic appearance, portal markings, and regular curvilinear capsule. Focal, hypoechogenic, non-vascularized nodule in the caudal aspect of the left lobe measuring 2.0 x 2.2 cm in size. No additional nodules or masses evident. Normal appearance of the hepatic and portal vasculature.

### *Gallbladder*

The gallbladder is full containing a scant amount of non-adhered, hyperechogenic sediment. Normal thickness and echogenic appearance of the wall. Normal size and appearance of the cystic and common bile duct.



## PATIENT

Bentley Diaz

## SPECIES

Canine

## BREED

Australian Shepherd

## SEX

Neutered male

## AGE

9 years

## WEIGHT

39 lbs

## INTERPRETED BY

Remo Lobetti, BVSc,  
MMedVet (Med),  
PhD, Dipl. ECVIM

## IMAGING PERFORMED BY

Julia Bakker, DVM

## HOSPITAL NAME

Orange Blossom  
Veterinary Imaging

## REFERRING VET

Dr. Sanchez

## INVOICE

734

## DATE

3/17/26

## *Gastrointestinal*

Normal appearance of the stomach, duodenum, small intestine, ileo-cecal junction, and colon with no loss of layering, 1:3 muscularis to mucosa ratio, normal wall thickness and peristaltic activity, and no distension of the lumen. A small amount of ingesta is present in the stomach compatible with a recent meal.

## *Pancreas*

The visible sections of the pancreas are of normal size and echogenic appearance with a regular capsule. Normal echogenic appearance of the mesentery and fat surrounding the pancreas.

## *Free Abdomen*

Normal mesenteric lymph nodes.

No ascites evident.

## ULTRASONOGRAPHIC FINDINGS

- Hepatic nodule
- Splenic nodule

## INTERPRETATION OF THE FINDINGS & FURTHER RECOMMENDATIONS

Etiologies for the hepatic nodule would be nodular hyperplasia, granuloma, organized hematoma and possibly emerging neoplasia.

The likely etiology for the splenic nodule would be reactive hyperplasia/extramedullary hemopoiesis, hematoma and granuloma with emerging neoplasia an unlikely differential diagnosis

Further assessment would be FNA cytology of the hepatic and splenic nodules.

Alternatively, regular ultrasound monitoring of the spleen and liver could be considered and if there is any progressive enlargement of either of the nodules then surgical excision should then be considered.

Further specific therapy would be dependent on an etiological diagnosis.



**PATIENT**

Bentley Diaz

**SPECIES**

Canine

**BREED**

Australian Shepherd

**SEX**

Neutered male

**AGE**

9 years

**WEIGHT**

39 lbs

**INTERPRETED BY**

Remo Lobetti, BVSc,  
MMedVet (Med),  
PhD, Dipl. ECVIM

**IMAGING  
PERFORMED BY**

Julia Bakker, DVM

**HOSPITAL NAME**

Orange Blossom  
Veterinary Imaging

**REFERRING VET**

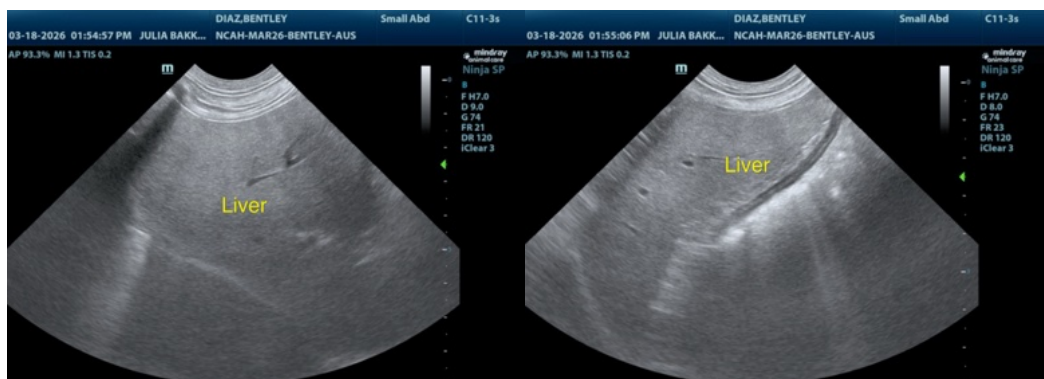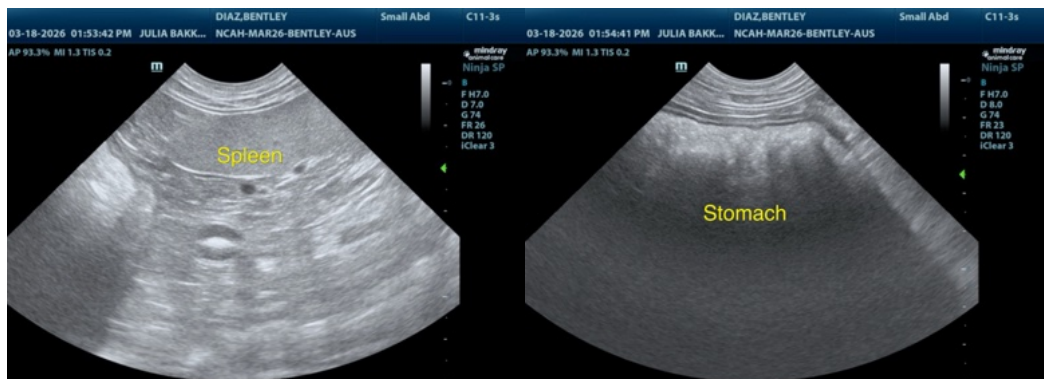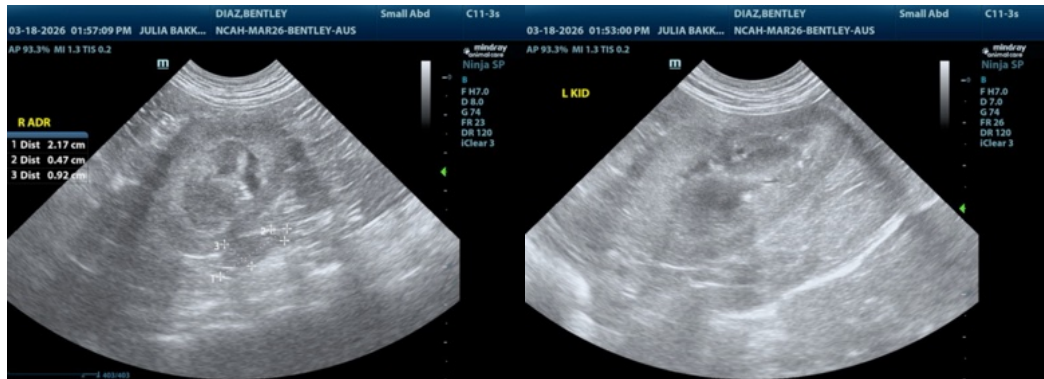
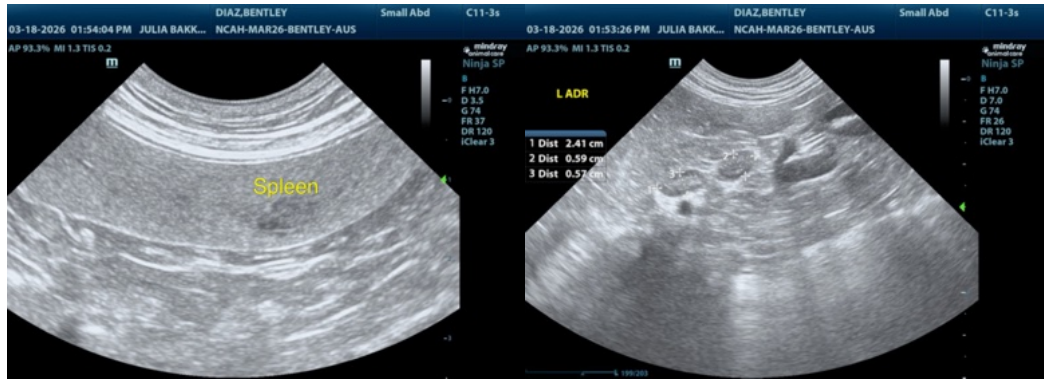
Dr. Sanchez

**INVOICE**

734

**DATE**

3/17/26





## PATIENT

Bentley Diaz

## SPECIES

Canine

## BREED

Australian Shepherd

## SEX

Neutered male

## AGE

9 years

## WEIGHT

39 lbs

## INTERPRETED BY

Remo Lobetti, BVSc,  
MMedVet (Med),  
PhD, Dipl. ECVIM

## IMAGING PERFORMED BY

Julia Bakker, DVM

## HOSPITAL NAME

Orange Blossom  
Veterinary Imaging

## REFERRING VET

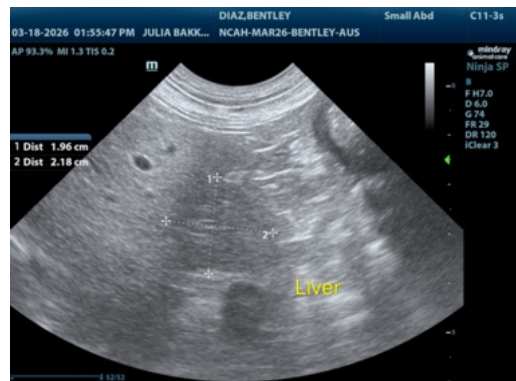
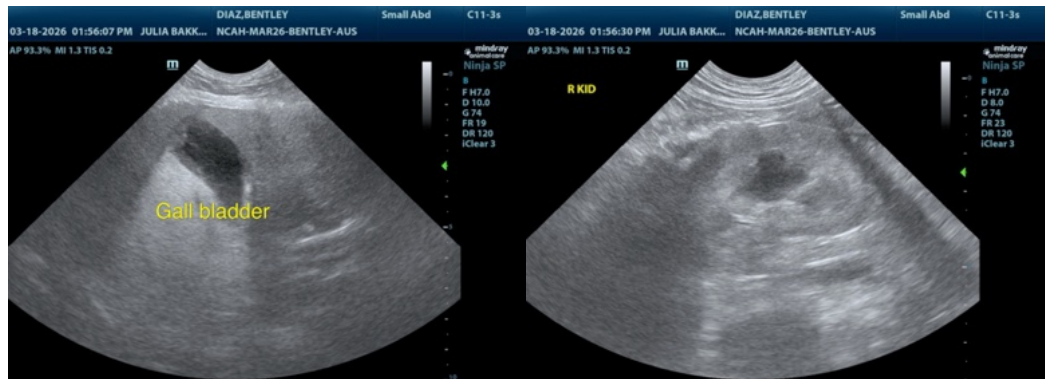
Dr. Sanchez

## INVOICE

734

## DATE

3/17/26



The information and recommendations provided are based on the images presented by the referring veterinarian/sonographer. No evaluation can be communicated regarding pathology that was not visible in the image/video clips provided.

Thank you for this referral. If the clinical or image interpretation does not parallel your findings or if I can be of any further assistance please contact me.

Remo Lobetti, BVSc, MMedVet (Med), PhD, Dipl. ECVIM (Internal Medicine)

[info@sonopath.com](mailto:info@sonopath.com)