



## PATIENT

Shelby Rizk

## SPECIES

Canine

## BREED

Retriever Cross

## SEX

Spayed female

## AGE

12 years

## WEIGHT

29 kg

## INTERPRETED BY

Remo Lobetti, BVSc,  
MMedVet (Med),  
PhD, Dipl. ECVIM

## IMAGING PERFORMED BY

Dr. Celine Ward

## HOSPITAL NAME

Kenora VC

## REFERRING VET

Dr. Ward

## INVOICE

73502

## DATE

3/17/26

## PRESENTING CLINICAL SIGNS

- RI-5-27-25 SHELBY BEAUDOIN - scan sent in May 2025 for MCT staging at that time. Mast cell tumours removed by board-certified specialist in June 2025. Histopathology returned as grade 2/low grade with clear margins
- Newly discovered Mass right hind hip region, mass is ~1cm diameter, round, raised, firm, well circumscribed, mobile --> Mast cells noted on cytology
- U/s submitted for staging, FNAs of liver/spleen and LNs sent to pathologist and pending results
- Bloodwork NSF

## ULTRASONOGRAPHIC EXAMINATION OF THE ABDOMEN

### Urinary System

The urinary bladder is small with a normal thickness and smooth appearance of the wall. Normal anechoic urine with no sediment or uroliths evident.

Normal appearance of the trigone area, proximal urethra, and iliac blood vessels.

Normal appearance and size of the iliac lymph nodes. Ureters not visualized, which can be considered a normal finding.

Normal renal size (left measured 5.5 cm, right measured 5.6 cm), architecture, echogenic appearance, cortico-medullary differentiation, which maintains a 1:3 cortex to medulla ratio, pelvis, and capsule. No infarcts, mineralization or renoliths evident. Normal color flow pattern is noted in both kidneys.

### Adrenal Glands

Normal shape, echogenic appearance, size, position, and appearance of the visible peri-adrenal vasculature. Left adrenal gland measured 0.45 cm in width. The right adrenal gland measured 0.47 cm and 0.53 cm in width.

### Spleen

Normal size and echogenic appearance. Smooth homogenous parenchyma and regular curvilinear capsule. Normal volume of the splenic vasculature without any overt congestion or thrombosis evident. No inflammatory, neoplastic, infarction, or infiltrative changes evident. The spleen measured 1.7 cm in width.

### Liver

Normal size, echogenic appearance, portal markings, and regular curvilinear capsule. No nodules or masses evident. Normal appearance of the hepatic and portal vasculature.



## PATIENT

Shelby Rizk

## SPECIES

Canine

## BREED

Retriever Cross

## SEX

Spayed female

## AGE

12 years

## WEIGHT

29 kg

## INTERPRETED BY

Remo Lobetti, BVSc,  
MMedVet (Med),  
PhD, Dipl. ECVIM

## IMAGING PERFORMED BY

Dr. Celine Ward

## HOSPITAL NAME

Kenora VC

## REFERRING VET

Dr. Ward

## INVOICE

73502

## DATE

3/17/26

## Gallbladder

The gallbladder is full containing a scant amount of non-adhered, hyperechogenic sediment. Normal thickness and echogenic appearance of the wall. Normal size and appearance of the cystic and common bile duct.

## Gastrointestinal

Normal appearance of the stomach, duodenum, small intestine, ileo-cecal junction, and colon with no loss of layering, 1:3 muscularis to mucosa ratio, normal wall thickness and peristaltic activity, and no distension of the lumen. Fecal material is present in the colon.

## Pancreas

The visible sections of the pancreas are of normal size and echogenic appearance with a regular capsule. Normal echogenic appearance of the mesentery and fat surrounding the pancreas.

## Free Abdomen

Normal mesenteric lymph nodes.

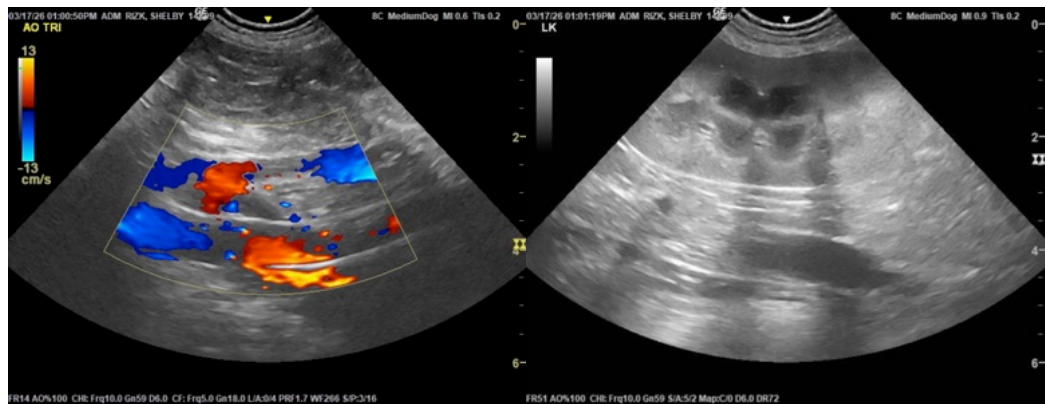
No ascites evident.

## ULTRASONOGRAPHIC FINDINGS

- Normal ultrasound examination of the abdomen.

## INTERPRETATION OF THE FINDINGS & FURTHER RECOMMENDATIONS

On this ultrasound there is no obvious evidence of metastatic mast cell neoplasia.





**PATIENT**

Shelby Rizk

**SPECIES**

Canine

**BREED**

Retriever Cross

**SEX**

Spayed female

**AGE**

12 years

**WEIGHT**

29 kg

**INTERPRETED BY**

Remo Lobetti, BVSc,  
MMedVet (Med),  
PhD, Dipl. ECVIM

**IMAGING  
PERFORMED BY**

Dr. Celine Ward

**HOSPITAL NAME**

Kenora VC

**REFERRING VET**

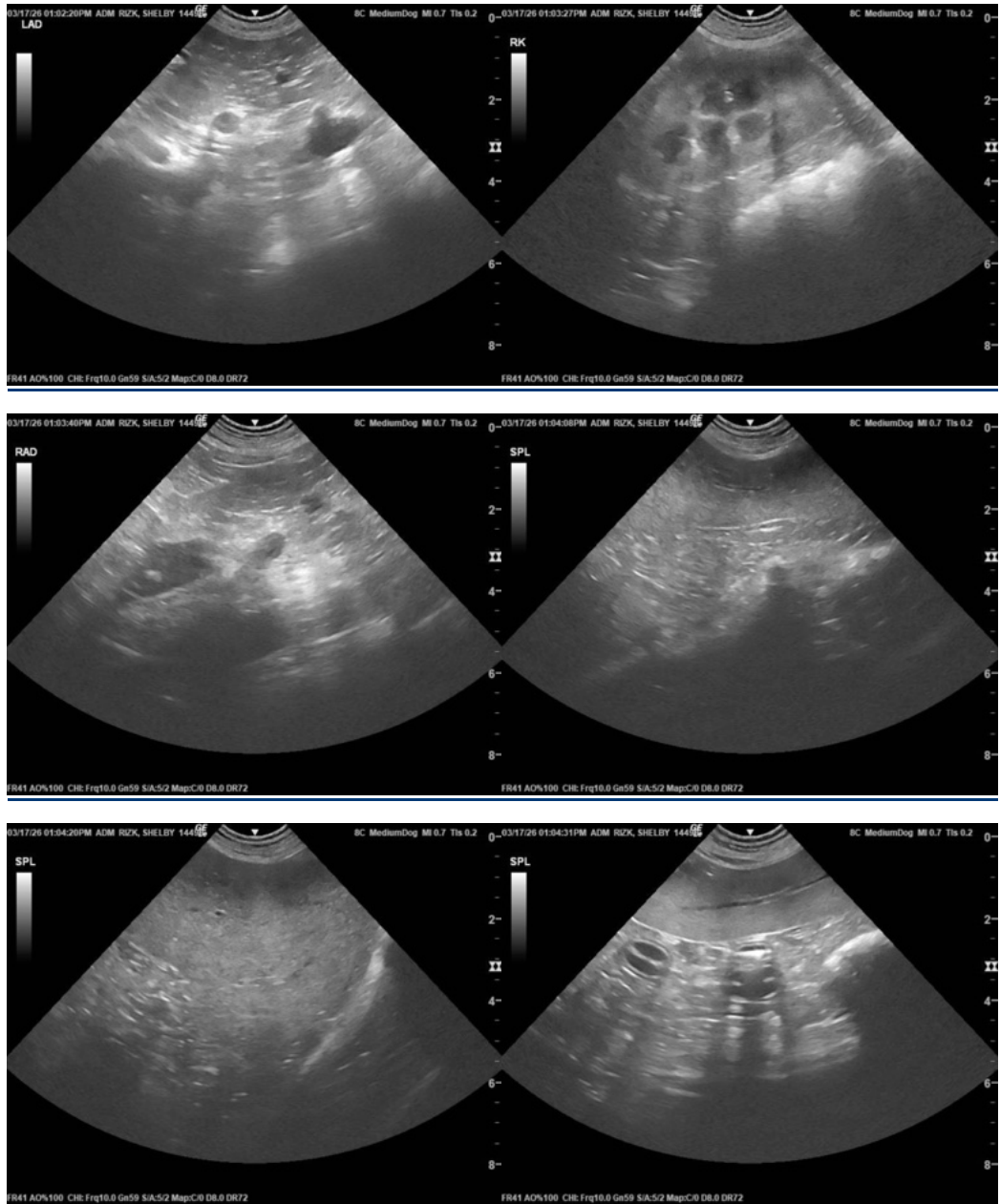
Dr. Ward

**INVOICE**

73502

**DATE**

3/17/26





## PATIENT

Shelby Rizk

## SPECIES

Canine

## BREED

Retriever Cross

## SEX

Spayed female

## AGE

12 years

## WEIGHT

29 kg

## INTERPRETED BY

Remo Lobetti, BVSc,  
MMedVet (Med),  
PhD, Dipl. ECVIM

## IMAGING PERFORMED BY

Dr. Celine Ward

## HOSPITAL NAME

Kenora VC

## REFERRING VET

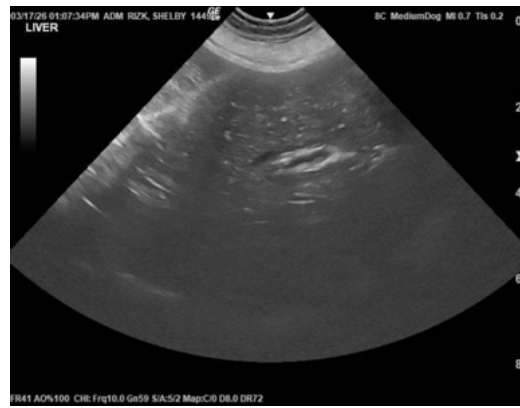
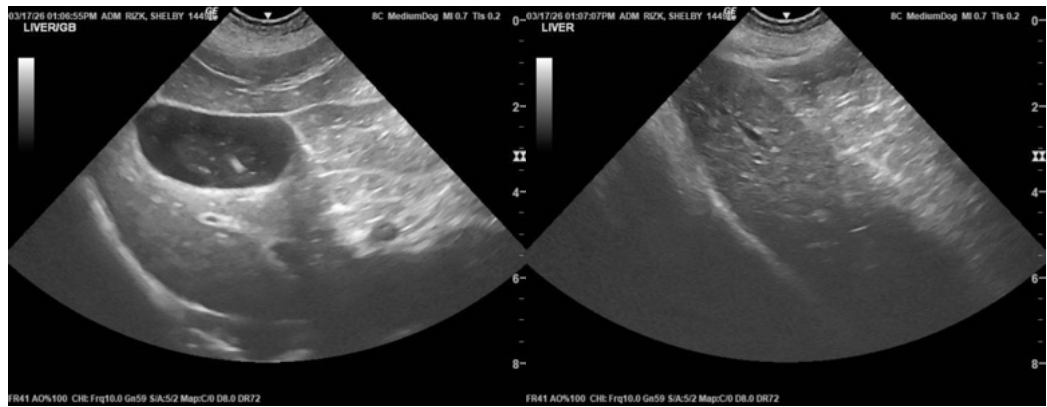
Dr. Ward

## INVOICE

73502

## DATE

3/17/26



The information and recommendations provided are based on the images presented by the referring veterinarian/sonographer. No evaluation can be communicated regarding pathology that was not visible in the image/video clips provided.

Thank you for this referral. If the clinical or image interpretation does not parallel your findings or if I can be of any further assistance please contact me.

Remo Lobetti, BVSc, MMedVet (Med), PhD, Dipl. ECVIM (Internal Medicine)

[info@sonopath.com](mailto:info@sonopath.com)