



## PATIENT

Oslo Pham

## SPECIES

Feline

## BREED

Domestic Shorthair

## SEX

Neutered male

## AGE

11 years

## WEIGHT

10.9 lbs

## INTERPRETED BY

Remo Lobetti, BVSc,  
MMedVet (Med),  
PhD, Dipl. ECVIM

## IMAGING PERFORMED BY

Dr. Jazmin Munoz  
Gonzalez

## HOSPITAL NAME

Oakridge VC

## REFERRING VET

Dr. Munoz-Gonzalez

## INVOICE

73501

## DATE

3/17/26

## PRESENTING CLINICAL SIGNS

- Hx of chronic diarrhea and occasional vomiting. BW overall wnl except mild hypophosphatemia 2.8 (normal between 3.1-7.5), fecal test neg, diarrhea PCR panel revealed *C. perfringens* Alpha Toxin (CPA) Gene at low levels (not clinically significant). On Hills w/d multi benefit for weight loss and GI support.

## ULTRASONOGRAPHIC EXAMINATION OF THE ABDOMEN

### *Urinary System*

The urinary bladder is small with a normal thickness and smooth appearance of the wall. A scant amount of floating, hyperechogenic sediment.

Normal appearance of the trigone area, proximal urethra, and iliac blood vessels.

Normal appearance and size of the iliac lymph nodes. Ureters not visualized, which can be considered a normal finding.

Normal renal size (left measured 3.9 cm, right measured 4.1 cm), architecture, echogenic appearance, cortico-medullary differentiation, which maintains a 1:3 cortex to medulla ratio, pelvis, and capsule. No infarcts, mineralization or renoliths evident. Normal color flow pattern is evident in both kidneys.

### *Adrenal Glands*

The adrenal glands are not visualized.

### *Spleen*

Normal size and echogenic appearance. Smooth homogenous parenchyma and regular curvilinear capsule. Normal volume of the splenic vasculature without any overt congestion or thrombosis evident. No inflammatory, neoplastic, infarction, or infiltrative changes evident. The spleen measured 0.6 cm in width.

### *Liver*

Normal size, echogenic appearance, portal markings, and regular curvilinear capsule. No nodules or masses evident. Normal appearance of the hepatic and portal vasculature.

### *Gallbladder*

The gallbladder is full containing normal anechoic bile. Normal thickness and echogenic appearance of the wall. Normal size and appearance of the cystic and common bile duct.



## PATIENT

Oslo Pham

## SPECIES

Feline

## BREED

Domestic Shorthair

## SEX

Neutered male

## AGE

11 years

## WEIGHT

10.9 lbs

## INTERPRETED BY

Remo Lobetti, BVSc,  
MMedVet (Med),  
PhD, Dipl. ECVIM

## IMAGING PERFORMED BY

Dr. Jazmin Munoz  
Gonzalez

## HOSPITAL NAME

Oakridge VC

## REFERRING VET

Dr. Munoz-Gonzalez

## INVOICE

73501

## DATE

3/17/26

## ***Gastrointestinal***

Normal appearance of the stomach, duodenum, small intestine, ileo-cecal junction, and colon with no loss of layering, 1:3 muscularis to mucosa ratio, normal wall thickness and peristaltic activity, and no distension of the lumen. Fecal material is present in the colon.

## ***Pancreas***

The visible sections of the pancreas are of normal size and echogenic appearance with a regular capsule. Normal echogenic appearance of the mesentery and fat surrounding the pancreas.

## ***Free Abdomen***

Normal mesenteric lymph nodes.

No ascites evident.

## **ULTRASONOGRAPHIC FINDINGS**

- Normal ultrasound examination of the abdomen.

## **INTERPRETATION OF THE FINDINGS & FURTHER RECOMMENDATIONS**

On this ultrasound there is no obvious etiology for the presenting clinical signs.

Although the GI tract appears ultrasonographically normal, with the presenting clinical signs, an underlying enteropathy such as dietary hypersensitivity and inflammatory bowel disease should still be considered. Exocrine pancreatic insufficiency would be a less likely differential diagnosis.

Further assessment would be cobalamin, folate and TLI assay and endoscopy of the upper GI tract with biopsies.

Specific therapy would be dependent on an etiological diagnosis. Symptomatic management that could be considered would be feeding a novel protein/hypoallergenic diet, cobalamin supplementation and if there is still not a satisfactory improvement then a course of Prednisolone would then be indicated.



**PATIENT**

Oslo Pham

**SPECIES**

Feline

**BREED**

Domestic Shorthair

**SEX**

Neutered male

**AGE**

11 years

**WEIGHT**

10.9 lbs

**INTERPRETED BY**

Remo Lobetti, BVSc,  
MMedVet (Med),  
PhD, Dipl. ECVIM

**IMAGING PERFORMED BY**

Dr. Jazmin Munoz  
Gonzalez

**HOSPITAL NAME**

Oakridge VC

**REFERRING VET**

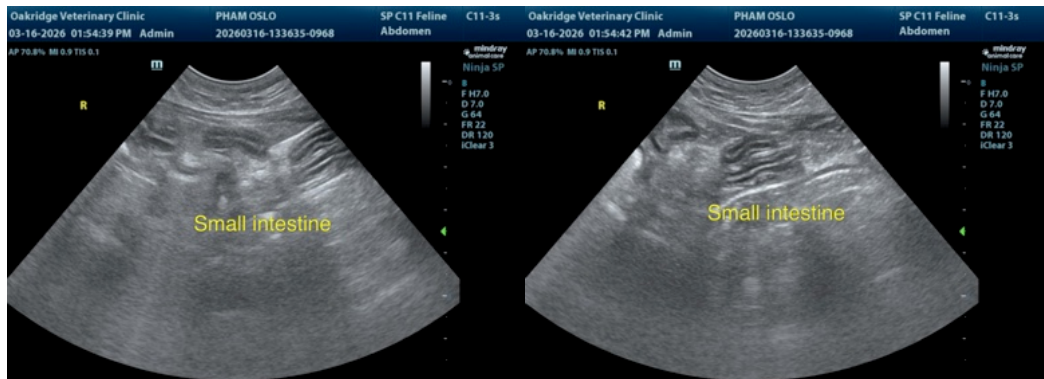
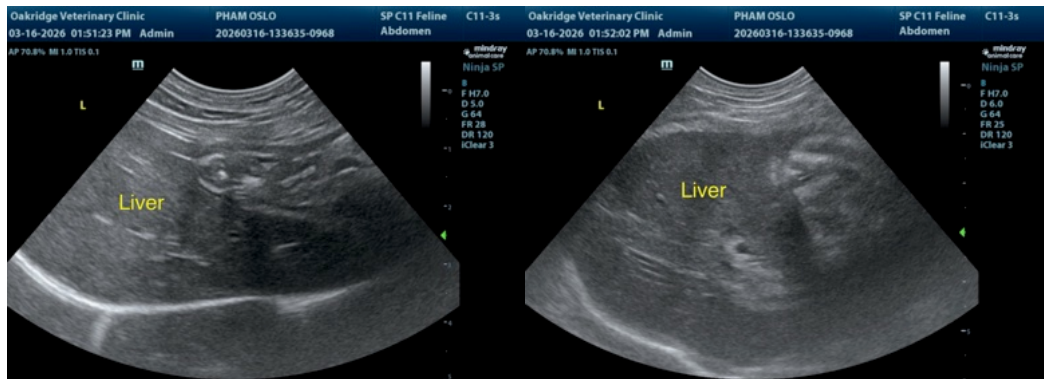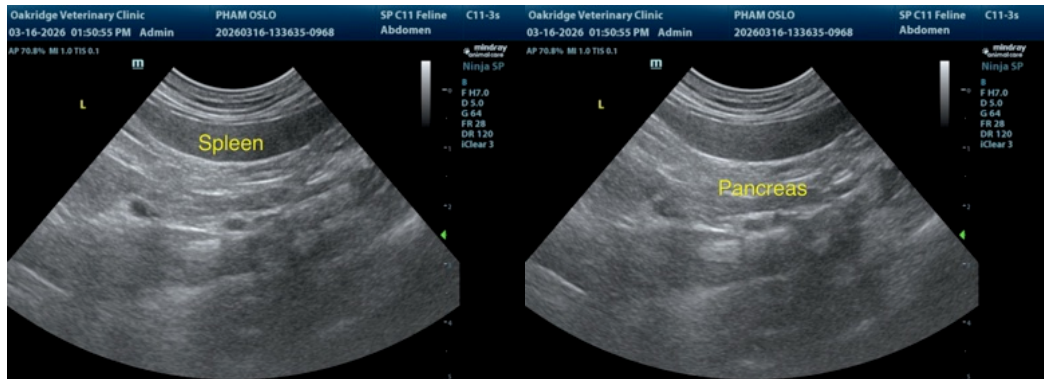
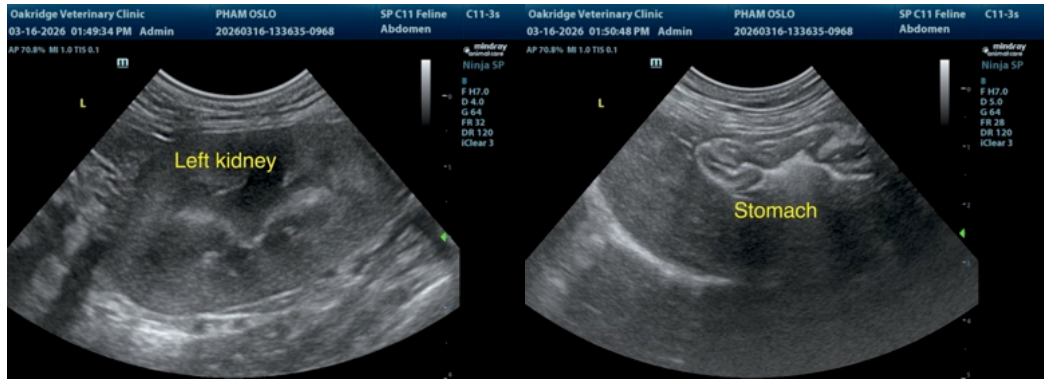
Dr. Munoz-Gonzalez

**INVOICE**

73501

**DATE**

3/17/26





## PATIENT

Oslo Pham

## SPECIES

Feline

## BREED

Domestic Shorthair

## SEX

Neutered male

## AGE

11 years

## WEIGHT

10.9 lbs

## INTERPRETED BY

Remo Lobetti, BVSc,  
MMedVet (Med),  
PhD, Dipl. ECVIM

## IMAGING PERFORMED BY

Dr. Jazmin Munoz  
Gonzalez

## HOSPITAL NAME

Oakridge VC

## REFERRING VET

Dr. Munoz-Gonzalez

## INVOICE

73501

## DATE

3/17/26

The information and recommendations provided are based on the images presented by the referring veterinarian/sonographer. No evaluation can be communicated regarding pathology that was not visible in the image/video clips provided.

Thank you for this referral. If the clinical or image interpretation does not parallel your findings or if I can be of any further assistance please contact me.

Remo Lobetti, BVSc, MMedVet (Med), PhD, Dipl. ECVIM (Internal Medicine)

[info@sonopath.com](mailto:info@sonopath.com)