



## PATIENT

Tiger Lilly Baker

## SPECIES

Canine

## BREED

Mix

## SEX

Spayed female

## AGE

12 years

## WEIGHT

53 lbs

## INTERPRETED BY

Remo Lobetti, BVSc,  
MMedVet (Med),  
PhD, Dipl. ECVIM

## IMAGING PERFORMED BY

Dr. Jones

## HOSPITAL NAME

Northwind AH

## REFERRING VET

Dr. Jones

## INVOICE

73456

## DATE

3/16/26

## PRESENTING CLINICAL SIGNS

- Significant weight loss (12 lbs since June 2025)
- Elevated ALT/ALKP
- ALT 187 ALKP 1663

## ULTRASONOGRAPHIC EXAMINATION OF THE ABDOMEN

### *Urinary System*

The urinary bladder is small with a normal thickness and smooth appearance of the wall. Normal anechoic urine with no sediment or uroliths evident.

Normal appearance of the trigone area, proximal urethra, and iliac blood vessels.

Normal appearance and size of the iliac lymph nodes. Ureters not visualized, which can be considered a normal finding.

Normal renal size (left measured 5.5 cm, right measured 5.4 cm), architecture, echogenic appearance, cortico-medullary differentiation, which maintains a 1:3 cortex to medulla ratio, pelvis, and capsule. No infarcts, mineralization or renoliths evident. Normal color flow pattern is evident in both kidneys.

### *Adrenal Glands*

Normal shape, echogenic appearance, size, position, and appearance of the visible peri-adrenal vasculature. Left adrenal gland measured 0.61 cm and 0.81 cm in width. The right adrenal gland measured 0.62 cm and 0.65 cm in width.

### *Spleen*

Normal size and echogenic appearance. Smooth homogenous parenchyma and regular curvilinear capsule. Normal volume of the splenic vasculature without any overt congestion or thrombosis evident. No inflammatory, neoplastic, infarction, or infiltrative changes evident. The spleen measured 1.6 cm in width.

### *Liver*

Normal size, echogenic appearance, portal markings, and regular curvilinear capsule. Large, isoechoic, non-vascularized mass in the caudal aspect of the right lobe measuring 4.6 x 6.7 cm in size. A hepatic cyst is present in the left lobe and measured 2.8 x 4.0 cm in size. No nodules or additional masses are evident. Normal appearance of the hepatic and portal vasculature.



## PATIENT

Tiger Lilly Baker

## SPECIES

Canine

## BREED

Mix

## SEX

Spayed female

## AGE

12 years

## WEIGHT

53 lbs

## INTERPRETED BY

Remo Lobetti, BVSc,  
MMedVet (Med),  
PhD, Dipl. ECVIM

## IMAGING PERFORMED BY

Dr. Jones

## HOSPITAL NAME

Northwind AH

## REFERRING VET

Dr. Jones

## INVOICE

73456

## DATE

3/16/26

## ***Gallbladder***

The gallbladder is full containing scant amount of non-adhered, hyperechogenic sediment. Normal thickness and echogenic appearance of the wall. Normal size and appearance of the cystic and common bile duct.

## ***Gastrointestinal***

Normal appearance of the stomach, duodenum, small intestine, ileo-cecal junction, and colon with no loss of layering, 1:3 muscularis to mucosa ratio, normal wall thickness and peristaltic activity, and no distension of the lumen. A small amount of ingesta is present within the stomach compatible with a recent meal. Fecal material was present in the colon.

## ***Pancreas***

Normal size and echogenic appearance with a regular capsule. Normal echogenic appearance of the mesentery and fat surrounding the pancreas.

## ***Free Abdomen***

Normal mesenteric lymph nodes.

No ascites evident.

## **ULTRASONOGRAPHIC FINDINGS**

- Hepatic mass.
- Hepatic cyst.

## **INTERPRETATION OF THE FINDINGS & FURTHER RECOMMENDATIONS**

The appearance of the hepatic mass would be consistent with a hepatoma with emerging hepatocellular carcinoma a less likely differential diagnosis.

The hepatic cyst can be considered an incidental finding.

Further assessment would be FNA cytology of the mass; however, a tru cut or wedge biopsy may be required for a final etiological diagnosis.

Specific therapy would be dependent on an etiological diagnosis.



## PATIENT

Tiger Lilly Baker

## SPECIES

Canine

## BREED

Mix

## SEX

Spayed female

## AGE

12 years

## WEIGHT

53 lbs

## INTERPRETED BY

Remo Lobetti, BVSc,  
MMedVet (Med),  
PhD, Dipl. ECVIM

## IMAGING PERFORMED BY

Dr. Jones

## HOSPITAL NAME

Northwind AH

## REFERRING VET

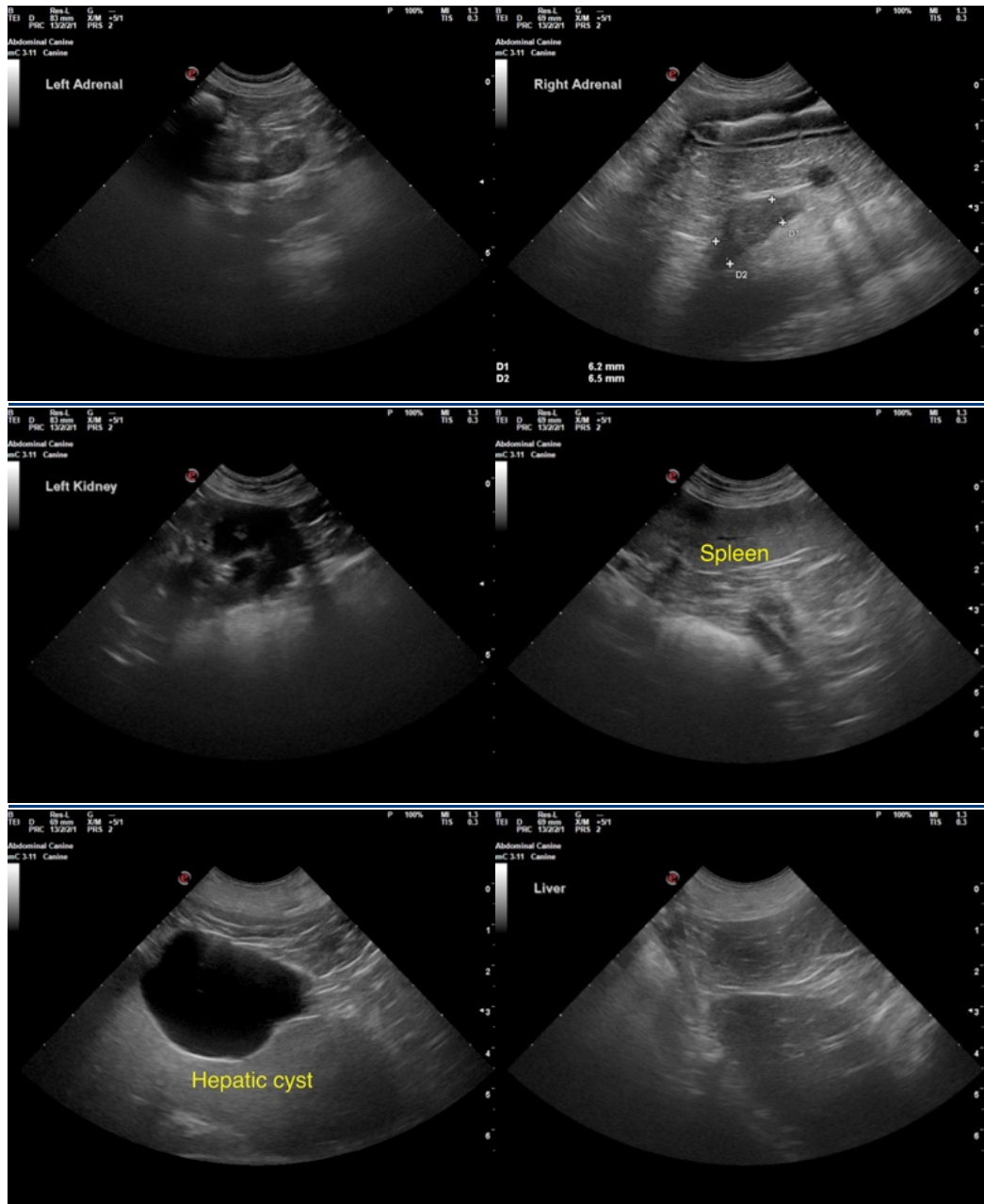
Dr. Jones

## INVOICE

73456

## DATE

3/16/26





## PATIENT

Tiger Lilly Baker

## SPECIES

Canine

## BREED

Mix

## SEX

Spayed female

## AGE

12 years

## WEIGHT

53 lbs

## INTERPRETED BY

Remo Lobetti, BVSc,  
MMedVet (Med),  
PhD, Dipl. ECVIM

## IMAGING PERFORMED BY

Dr. Jones

## HOSPITAL NAME

Northwind AH

## REFERRING VET

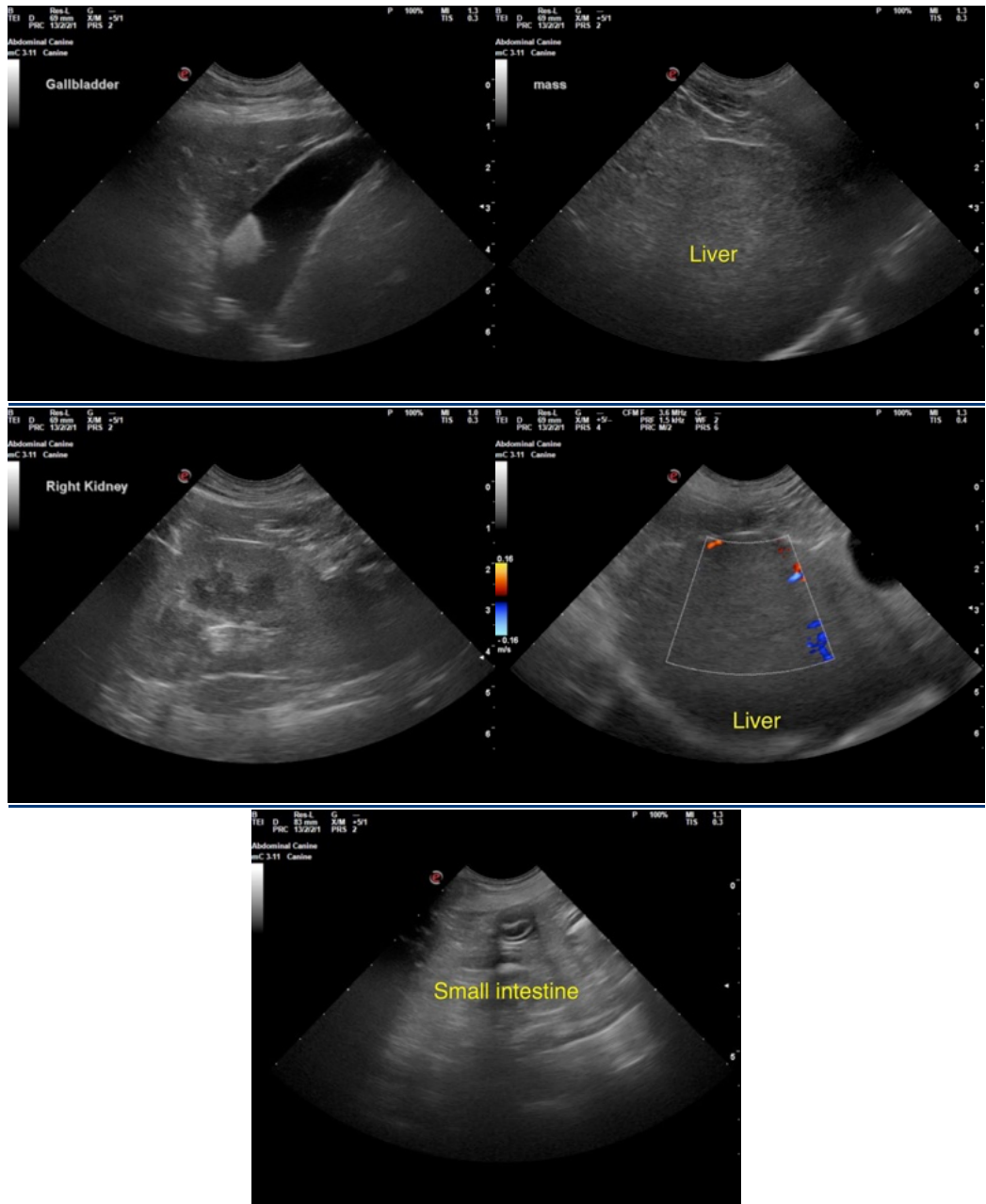
Dr. Jones

## INVOICE

73456

## DATE

3/16/26



The information and recommendations provided are based on the images presented by the referring veterinarian/sonographer. No evaluation can be communicated regarding pathology that was not visible in the image/video clips provided.

Thank you for this referral. If the clinical or image interpretation does not parallel your findings or if I can be of any further assistance please contact me.

Remo Lobetti, BVSc, MMedVet (Med), PhD, Dipl. ECVIM (Internal Medicine)

[info@sonopath.com](mailto:info@sonopath.com)