



PATIENT

Piper Chavers

SPECIES

Canine

BREED

Chihuahua Mix

SEX

Spayed female

AGE

10 years

WEIGHT

6.7 lbs

INTERPRETED BY

Remo Lobetti, BVSc,
MMedVet (Med),
PhD, Dipl. ECVIM

IMAGING PERFORMED BY

Dr. Allison Maxey

HOSPITAL NAME

Evergreen AH

REFERRING VET

Dr. Maxey

INVOICE

73457

DATE

3/16/26

PRESENTING CLINICAL SIGNS

- Increasing ALT elevation on bloodwork.
- Initially discovered on routine annual bloodwork
- Pet is clinically normal per owner.
- 2/21/26 - ALT 903 U/L, remainder of liver enzymes unremarkable Recheck 3/11/26 - ALT 1,553 U/L Bile acids pending. Owner declined urinalysis and leptospirosis testing.

ULTRASONOGRAPHIC EXAMINATION OF THE ABDOMEN

Urinary System

The urinary bladder is small with a normal thickness and smooth appearance of the wall. Normal anechoic urine with no sediment or uroliths evident.

Normal appearance of the trigone area, proximal urethra, and iliac blood vessels.

Normal appearance and size of the iliac lymph nodes. Ureters not visualized, which can be considered a normal finding.

Normal renal size (left measured 2.9 cm, right measured 2.8 cm), architecture, echogenic appearance, cortico-medullary differentiation, which maintains a 1:3 cortex to medulla ratio, pelvis, and capsule. No infarcts, mineralization or renoliths evident.

Adrenal Glands

The left adrenal gland is normal in shape, echogenic appearance, size, position, and appearance of the visible peri-adrenal vasculature. Left adrenal gland measured 0.28 cm and 0.28 cm in width. The right adrenal gland was not clearly visualized, but appears to be of normal shape, echogenic appearance and size.

Spleen

Normal size and echogenic appearance. Smooth homogenous parenchyma and regular curvilinear capsule. Normal volume of the splenic vasculature without any overt congestion or thrombosis evident. No inflammatory, neoplastic, infarction, or infiltrative changes evident.

Liver

Normal size, echogenic appearance, portal markings, and regular curvilinear capsule. No nodules or masses evident. Normal appearance of the hepatic and portal vasculature.



PATIENT

Piper Chavers

SPECIES

Canine

BREED

Chihuahua Mix

SEX

Spayed female

AGE

10 years

WEIGHT

6.7 lbs

INTERPRETED BY

Remo Lobetti, BVSc,
MMedVet (Med),
PhD, Dipl. ECVIM

IMAGING PERFORMED BY

Dr. Allison Maxey

HOSPITAL NAME

Evergreen AH

REFERRING VET

Dr. Maxey

INVOICE

73457

DATE

3/16/26

Gallbladder

The gallbladder is full containing normal anechoic bile. Normal thickness and echogenic appearance of the wall. Normal size and appearance of the cystic and common bile duct.

Gastrointestinal

Normal appearance of the stomach, duodenum, small intestine, ileo-cecal junction, and colon with no loss of layering, 1:3 muscularis to mucosa ratio, normal wall thickness and peristaltic activity, and no distension of the lumen.

Pancreas

The visible sections of the pancreas are of normal size and echogenic appearance with a regular capsule. Normal echogenic appearance of the mesentery and fat surrounding the pancreas.

Free Abdomen

Normal mesenteric lymph nodes.

No ascites evident.

ULTRASONOGRAPHIC FINDINGS

- Normal ultrasound examination of the abdomen.

INTERPRETATION OF THE FINDINGS & FURTHER RECOMMENDATIONS

On this ultrasound there is no obvious etiology for the elevated ALT activity.

Although the liver appears ultrasonographically normal, with the progressive elevation of ALT activity, an underlying hepatopathy such as reactive hyperplasia, vacuolar and metabolic should still be considered. Hepatitis and infiltrative neoplasia would be highly unlikely differential diagnosis.

Further assessment would be based on the pending results, but could include FNA cytology of the liver.

A tru cut or wedge biopsy may be required for a final etiological diagnosis.

Specific therapy would be dependent on an etiological diagnosis.

Symptomatic management that can be considered would be the use of Ursodiol with regular monitoring of liver enzyme activity.



PATIENT

Piper Chavers

SPECIES

Canine

BREED

Chihuahua Mix

SEX

Spayed female

AGE

10 years

WEIGHT

6.7 lbs

INTERPRETED BY

Remo Lobetti, BVSc,
MMedVet (Med),
PhD, Dipl. ECVIM

**IMAGING
PERFORMED BY**

Dr. Allison Maxey

HOSPITAL NAME

Evergreen AH

REFERRING VET

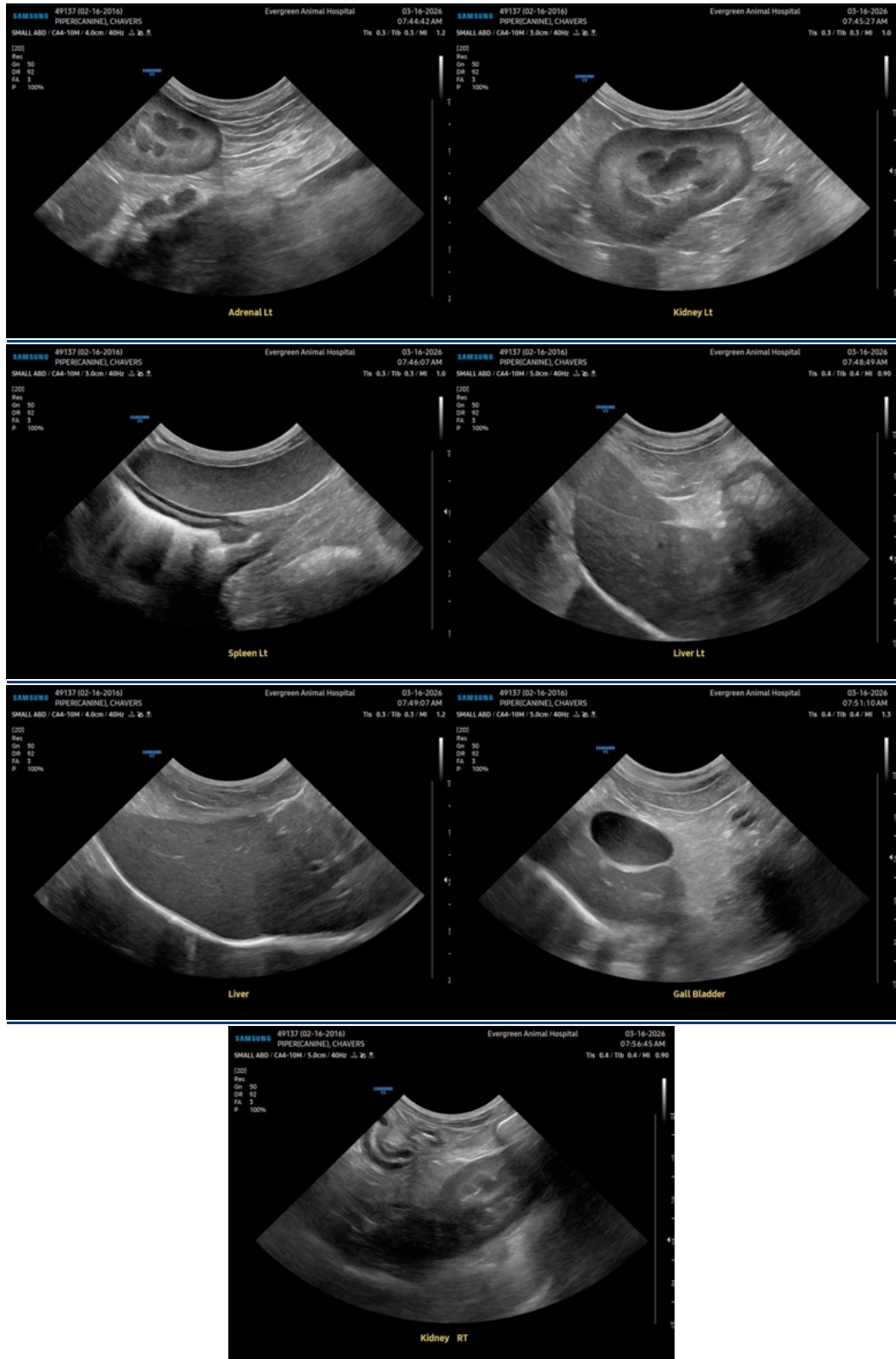
Dr. Maxey

INVOICE

73457

DATE

3/16/26





PATIENT

Piper Chavers

SPECIES

Canine

BREED

Chihuahua Mix

SEX

Spayed female

AGE

10 years

WEIGHT

6.7 lbs

INTERPRETED BY

Remo Lobetti, BVSc,
MMedVet (Med),
PhD, Dipl. ECVIM

IMAGING PERFORMED BY

Dr. Allison Maxey

HOSPITAL NAME

Evergreen AH

REFERRING VET

Dr. Maxey

INVOICE

73457

DATE

3/16/26

The information and recommendations provided are based on the images presented by the referring veterinarian/sonographer. No evaluation can be communicated regarding pathology that was not visible in the image/video clips provided.

Thank you for this referral. If the clinical or image interpretation does not parallel your findings or if I can be of any further assistance please contact me.

Remo Lobetti, BVSc, MMedVet (Med), PhD, Dipl. ECVIM (Internal Medicine)

info@sonopath.com