



## PATIENT

Nola Hart

## SPECIES

Canine

## BREED

Boxer Mix

## SEX

Spayed female

## AGE

8 years

## WEIGHT

53.9 lbs

## INTERPRETED BY

Remo Lobetti, BVSc,  
MMedVet (Med),  
PhD, Dipl. ECVIM

## IMAGING PERFORMED BY

Cory Bassett

## HOSPITAL NAME

All Creatures Small AH

## REFERRING VET

Dr. Bassett

## INVOICE

73465

## DATE

3/16/26

## PRESENTING CLINICAL SIGNS

3/2 pf increased anxiety and being mopey and clingy with O Pet did vomit one time. O unsure if behavior change was due to medical reason or new toddler in the house and new baby  
Rx'd Gabapentin and Fluoxetine  
After 1 week O discontinued Gaba as pet was not eating and not acting like herself  
History pancreatitis treatment at ER vet on 1/3  
Abnormal PE/Chem/CBC/UA Results: BW performed today 3/16 hemolyzed sample: RBC 9.49 (5.65-8.87) Hemoglob 20.8 (13.1-20.5) WBC 4.02 (5.05-16.76) Neut 2.63 (2.95-11.64) Phos 2.3 (2.5-6.8) Albumin 4.0 (2.2-3.9) ALT 195 (10-125) TB 1.1 (0.0-0.9) Lipase 2345 (200-1800)

## ULTRASONOGRAPHIC EXAMINATION OF THE ABDOMEN

### Urinary System

The urinary bladder is small with a normal thickness and smooth appearance of the wall. Normal anechoic urine with no sediment or uroliths evident.

Normal appearance of the trigone area, proximal urethra, and iliac blood vessels.

Normal appearance and size of the iliac lymph nodes. Ureters not visualized, which can be considered a normal finding.

Normal renal size (left measured 5.6 cm, right measured 6.3 cm), architecture, echogenic appearance, cortico-medullary differentiation, which maintains a 1:3 cortex to medulla ratio, pelvis, and capsule. No infarcts, mineralization or renoliths evident. Normal color flow pattern is evident in the left kidney.

### Adrenal Glands

The left adrenal gland is normal in shape, echogenic appearance, size, position, and appearance of the visible peri-adrenal vasculature. Left adrenal gland measured 0.45 cm in width. The right adrenal gland was not visualized, but appears to be of normal shape, echogenic appearance and size.

### Spleen

Normal size and echogenic appearance. Smooth homogenous parenchyma and regular curvilinear capsule. Normal volume of the splenic vasculature without any overt congestion or thrombosis evident. No inflammatory, neoplastic, infarction, or infiltrative changes evident. The spleen measured 2.7 cm.

### Liver

Normal size, echogenic appearance, portal markings, and regular curvilinear capsule. No nodules or masses evident. Normal appearance of the hepatic and portal vasculature.



## PATIENT

Nola Hart

## SPECIES

Canine

## BREED

Boxer Mix

## SEX

Spayed female

## AGE

8 years

## WEIGHT

53.9 lbs

## INTERPRETED BY

Remo Lobetti, BVSc,  
MMedVet (Med),  
PhD, Dipl. ECVIM

## IMAGING PERFORMED BY

Cory Bassett

## HOSPITAL NAME

All Creatures Small AH

## REFERRING VET

Dr. Bassett

## INVOICE

73465

## DATE

3/16/26

## Gallbladder

The gallbladder is full containing normal anechoic bile. Normal thickness and echogenic appearance of the wall. Normal size and appearance of the cystic and common bile duct.

## Gastrointestinal

Normal appearance of the stomach, duodenum, small intestine, ileo-cecal junction, and colon with no loss of layering, 1:3 muscularis to mucosa ratio, normal wall thickness and peristaltic activity, and no distension of the lumen.

## Pancreas

The visible sections of the pancreas are of normal size and echogenic appearance with a regular capsule. Normal echogenic appearance of the mesentery and fat surrounding the pancreas.

## Free Abdomen

Normal mesenteric lymph nodes.

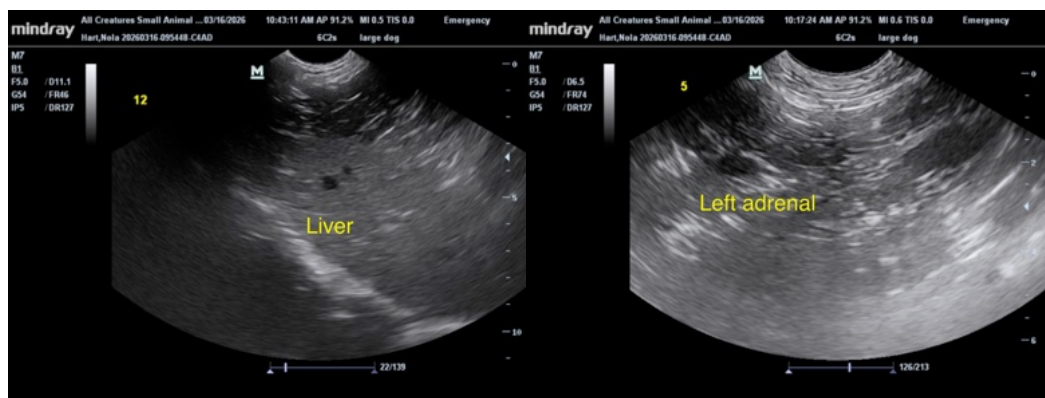
No ascites evident.

## ULTRASONOGRAPHIC FINDINGS

- Normal ultrasound examination of the abdomen.

## INTERPRETATION OF THE FINDINGS & FURTHER RECOMMENDATIONS

No specific therapy is recommended in this patient.





**PATIENT**

Nola Hart

**SPECIES**

Canine

**BREED**

Boxer Mix

**SEX**

Spayed female

**AGE**

8 years

**WEIGHT**

53.9 lbs

**INTERPRETED BY**

Remo Lobetti, BVSc,  
MMedVet (Med),  
PhD, Dipl. ECVIM

**IMAGING PERFORMED BY**

Cory Bassett

**HOSPITAL NAME**

All Creatures Small AH

**REFERRING VET**

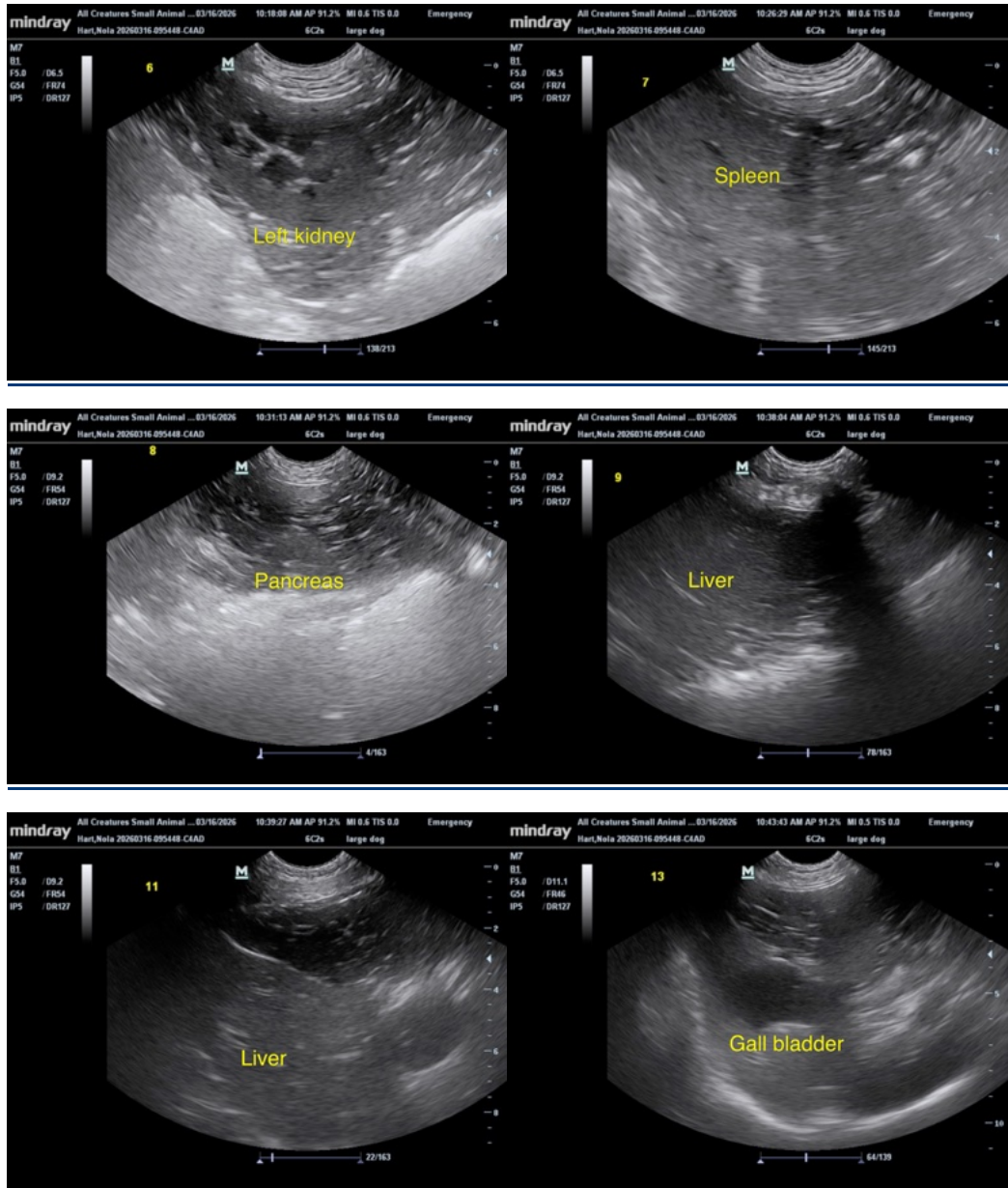
Dr. Bassett

**INVOICE**

73465

**DATE**

3/16/26





## PATIENT

Nola Hart

## SPECIES

Canine

## BREED

Boxer Mix

## SEX

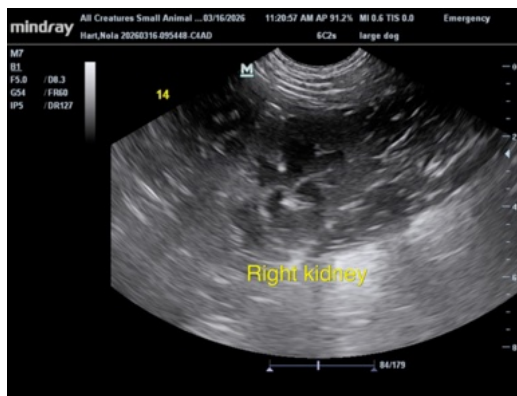
Spayed female

## AGE

8 years

## WEIGHT

53.9 lbs



The information and recommendations provided are based on the images presented by the referring veterinarian/sonographer. No evaluation can be communicated regarding pathology that was not visible in the image/video clips provided.

Thank you for this referral. If the clinical or image interpretation does not parallel your findings or if I can be of any further assistance please contact me.

Remo Lobetti, BVSc, MMedVet (Med), PhD, Dipl. ECVIM (Internal Medicine)

[info@sonopath.com](mailto:info@sonopath.com)

## INTERPRETED BY

Remo Lobetti, BVSc,  
MMedVet (Med),  
PhD, Dipl. ECVIM

## IMAGING PERFORMED BY

Cory Bassett

## HOSPITAL NAME

All Creatures Small AH

## REFERRING VET

Dr. Bassett

## INVOICE

73465

## DATE

3/16/26