



PATIENT

Kaci Nicholson

SPECIES

Canine

BREED

Coonhound

SEX

Spayed female

AGE

9 years

WEIGHT

42.5 lbs

INTERPRETED BY

Remo Lobetti, BVSc,
MMedVet (Med),
PhD, Dipl. ECVIM

IMAGING PERFORMED BY

Brandon

HOSPITAL NAME

Dillsburg VC

REFERRING VET

Dr. Amber

INVOICE

73460

DATE

3/12/26

PRESENTING CLINICAL SIGNS

- History of bleeding from anus. left side anal gland is thickened. anal glands imaged to try to help assess for signs of neoplasia. hypothyroid controlled on thyrosin but losing weight. mild increase in triglycerides likely because not fasted. ALKP mildly increased at 351. Urine specific gravity was 1.040 in sept. spleen feels elongated and a little thickened in the middle. on abdominal radiographs there is an area in the center that is a little irregular/fuzzy with a spot that is more dense but not defined mass. the liver is very elongated as well.
- Elongated spleen and liver on rads. ALKP 351. triglycerides 449. PSL 275.

ULTRASONOGRAPHIC EXAMINATION OF THE ABDOMEN

Urinary System

The urinary bladder is full with a normal thickness and smooth appearance of the wall. Normal anechoic urine with no sediment or uroliths evident.

Normal appearance of the trigone area, proximal urethra, and iliac blood vessels.

Normal appearance and size of the iliac lymph nodes. Ureters not visualized, which can be considered a normal finding.

Normal renal size (left measured 4.6 cm, right measured 5.9 cm), architecture, echogenic appearance, cortico-medullary differentiation, which maintains a 1:3 cortex to medulla ratio, pelvis, and capsule. No infarcts, mineralization or renoliths evident.

Adrenal Glands

Normal shape, echogenic appearance, size, position, and appearance of the visible peri-adrenal vasculature. Left adrenal gland measured 2.07 cm in length x 0.55 and 0.65 cm in width. The right adrenal gland measured 2.18 cm in length x 0.61 cm and 0.74 cm in width.

Spleen

Normal size and echogenic appearance. Smooth homogenous parenchyma and regular curvilinear capsule. Normal volume of the splenic vasculature without any overt congestion or thrombosis evident. No inflammatory, neoplastic, infarction, or infiltrative changes evident. The spleen measured 2.2 cm in width.

Liver

Normal size, echogenic appearance, portal markings, and regular curvilinear capsule. No nodules or masses evident. Normal appearance of the hepatic and portal vasculature.



PATIENT

Kaci Nicholson

SPECIES

Canine

BREED

Coonhound

SEX

Spayed female

AGE

9 years

WEIGHT

42.5 lbs

INTERPRETED BY

Remo Lobetti, BVSc,
MMedVet (Med),
PhD, Dipl. ECVIM

IMAGING PERFORMED BY

Brandon

HOSPITAL NAME

Dillsburg VC

REFERRING VET

Dr. Amber

INVOICE

73460

DATE

3/12/26

Gallbladder

The gallbladder is full containing a small amount of dependent mineralized sediment/small choleliths. Normal thickness and echogenic appearance of the wall. Normal size and appearance of the cystic and common bile duct.

Gastrointestinal

Normal appearance of the stomach, duodenum, small intestine, ileo-cecal junction, and colon with no loss of layering, 1:3 muscularis to mucosa ratio, normal wall thickness and peristaltic activity, and no distension of the lumen.

Pancreas

The visible sections of the pancreas are of normal size and echogenic appearance with a regular capsule. Normal echogenic appearance of the mesentery and fat surrounding the pancreas.

Free Abdomen

Normal mesenteric lymph nodes.

No ascites evident.

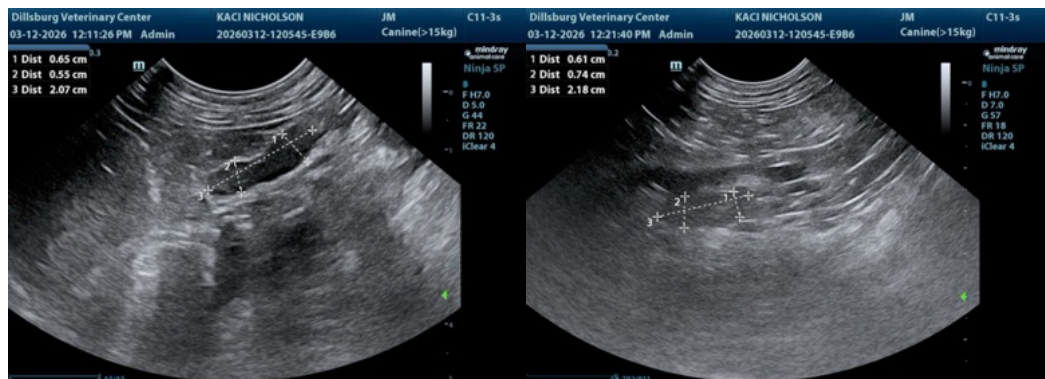
No obvious anal gland nodules or masses are evident.

ULTRASONOGRAPHIC FINDINGS

- Gallbladder sediment.

INTERPRETATION OF THE FINDINGS & FURTHER RECOMMENDATIONS

In essence a normal ultrasound examination of the abdomen as the gallbladder sediment can be considered an incidental finding.





PATIENT

Kaci Nicholson

SPECIES

Canine

BREED

Coonhound

SEX

Spayed female

AGE

9 years

WEIGHT

42.5 lbs

INTERPRETED BY

Remo Lobetti, BVSc,
MMedVet (Med),
PhD, Dipl. ECVIM

IMAGING PERFORMED BY

Brandon

HOSPITAL NAME

Dillsburg VC

REFERRING VET

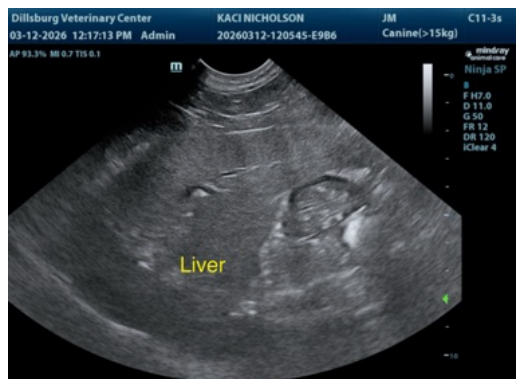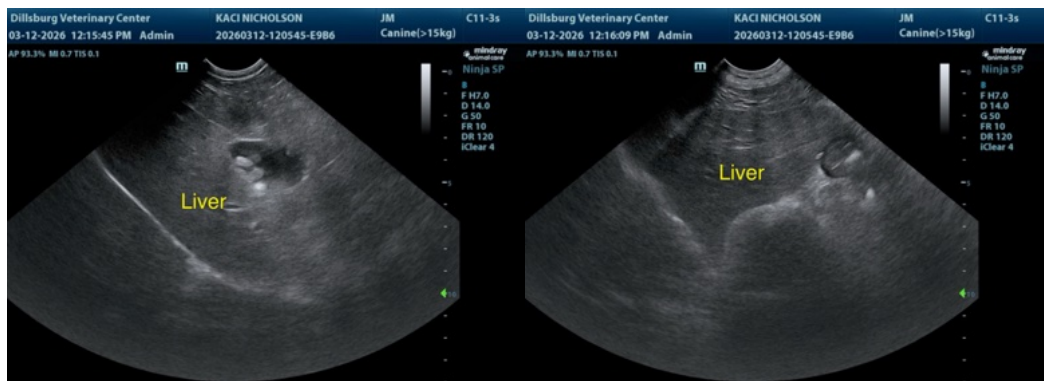
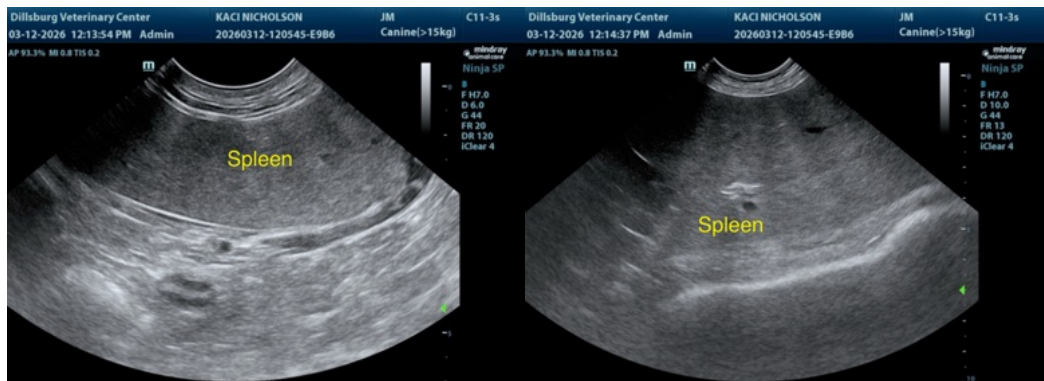
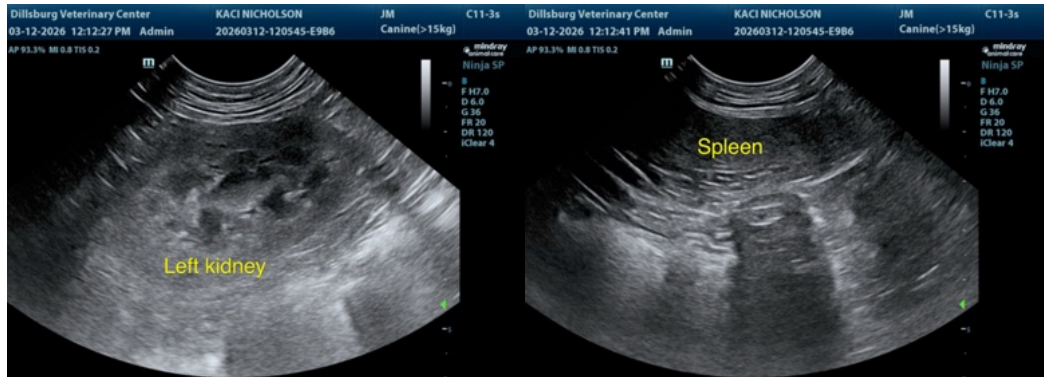
Dr. Amber

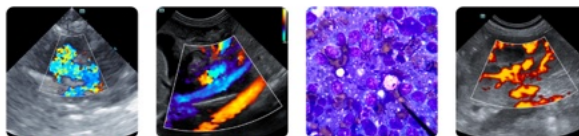
INVOICE

73460

DATE

3/12/26





PATIENT

Kaci Nicholson

SPECIES

Canine

BREED

Coonhound

SEX

Spayed female

AGE

9 years

WEIGHT

42.5 lbs

INTERPRETED BY

Remo Lobetti, BVSc,
MMedVet (Med),
PhD, Dipl. ECVIM

IMAGING PERFORMED BY

Brandon

HOSPITAL NAME

Dillsburg VC

REFERRING VET

Dr. Amber

INVOICE

73460

DATE

3/12/26

The information and recommendations provided are based on the images presented by the referring veterinarian/sonographer. No evaluation can be communicated regarding pathology that was not visible in the image/video clips provided.

Thank you for this referral. If the clinical or image interpretation does not parallel your findings or if I can be of any further assistance please contact me.

Remo Lobetti, BVSc, MMedVet (Med), PhD, Dipl. ECVIM (Internal Medicine)

info@sonopath.com