



PATIENT

Darth Vader Gutierrez

SPECIES

Feline

BREED

Domestic Shorthair

SEX

Neutered male

AGE

12 years

WEIGHT

14.2 lbs

INTERPRETED BY

Remo Lobetti, BVSc,
MMedVet (Med),
PhD, Dipl. ECVIM

IMAGING PERFORMED BY

Dr. Stranzl

HOSPITAL NAME

Dakota VC

REFERRING VET

Dr. Stranzl

INVOICE

73372

DATE

3/10/26

PRESENTING CLINICAL SIGNS

- P has been vomiting for 2 months 2 vomit a day and every day. no blood P is eating normal sometimes food sometimes bile.

ULTRASONOGRAPHIC EXAMINATION OF THE ABDOMEN

Urinary System

The urinary bladder is full with a normal thickness and smooth appearance of the wall. A scant amount of floating, hyperechogenic sediment.

Normal appearance of the trigone area, proximal urethra, and iliac blood vessels.

Normal appearance and size of the iliac lymph nodes. Ureters not visualized, which can be considered a normal finding.

Normal renal size (left measured 4.2 cm, right measured 4.0 cm), architecture, echogenic appearance, cortico-medullary differentiation, which maintains a 1:3 cortex to medulla ratio, pelvis, and capsule. Bilateral corticomedullary rim sign was present. No infarcts, mineralization or renoliths evident.

Adrenal Glands

The adrenal glands were not visualized.

Spleen

Normal size and echogenic appearance. Smooth homogenous parenchyma and regular curvilinear capsule. Normal volume of the splenic vasculature without any overt congestion or thrombosis evident. No inflammatory, neoplastic, infarction, or infiltrative changes evident. The spleen measured 1.0 cm in width.

Liver

Normal size, echogenic appearance, portal markings, and regular curvilinear capsule. No nodules or masses evident. Normal appearance of the hepatic and portal vasculature.

Gallbladder

The gallbladder is small containing normal anechoic bile. Normal thickness and echogenic appearance of the wall. Normal size and appearance of the cystic and common bile duct.



PATIENT

Darth Vader Gutierrez

SPECIES

Feline

BREED

Domestic Shorthair

SEX

Neutered male

AGE

12 years

WEIGHT

14.2 lbs

INTERPRETED BY

Remo Lobetti, BVSc,
MMedVet (Med),
PhD, Dipl. ECVIM

IMAGING PERFORMED BY

Dr. Stranzl

HOSPITAL NAME

Dakota VC

REFERRING VET

Dr. Stranzl

INVOICE

73372

DATE

3/10/26

Gastrointestinal

Normal appearance of the stomach, duodenum, ileo-cecal junction, and colon with no loss of layering, 1:3 muscularis to mucosa ratio, normal wall thickness and peristaltic activity, and no distension of the lumen. Thickening of the small intestine (up to 0.5 cm) with no loss of layering but with a marked increase in the muscularis to mucosa ratio, normal peristaltic activity and no distension of the lumen.

Pancreas

The visible sections of the pancreas are of normal size and echogenic appearance with a regular capsule. Normal echogenic appearance of the mesentery and fat surrounding the pancreas.

Free Abdomen

Enlarged mesenteric lymph nodes measuring up to 1.4 x 4.0 cm in size with a hypoechogenic appearance and a rounded shape.

Hyperechogenic appearance of the mesentery surrounding the lymph nodes.

No ascites evident.

ULTRASONOGRAPHIC FINDINGS

- Enteropathy.
- Mesenteric lymphadenomegaly.
- Corticomedullary rim sign.

INTERPRETATION OF THE FINDINGS & FURTHER RECOMMENDATIONS

With the small intestinal changes and the mesenteric lymphadenomegaly the most likely etiology would be lymphoma with granulomatous disease a differential diagnosis.

The corticomedullary rim sign can be ascribed as secondary to either lymphoma or granulomatous disease.

Initial further assessment would be FNA cytology of the mesenteric lymph nodes and if no-diagnostic then endoscopy of the upper GI tract with biopsies and possibly FNA cytology of the small intestinal wall.

Specific therapy would be dependent on an etiological diagnosis.



PATIENT

Darth Vader Gutierrez

SPECIES

Feline

BREED

Domestic Shorthair

SEX

Neutered male

AGE

12 years

WEIGHT

14.2 lbs

INTERPRETED BY

Remo Lobetti, BVSc,
MMedVet (Med),
PhD, Dipl. ECVIM

IMAGING PERFORMED BY

Dr. Stranzl

HOSPITAL NAME

Dakota VC

REFERRING VET

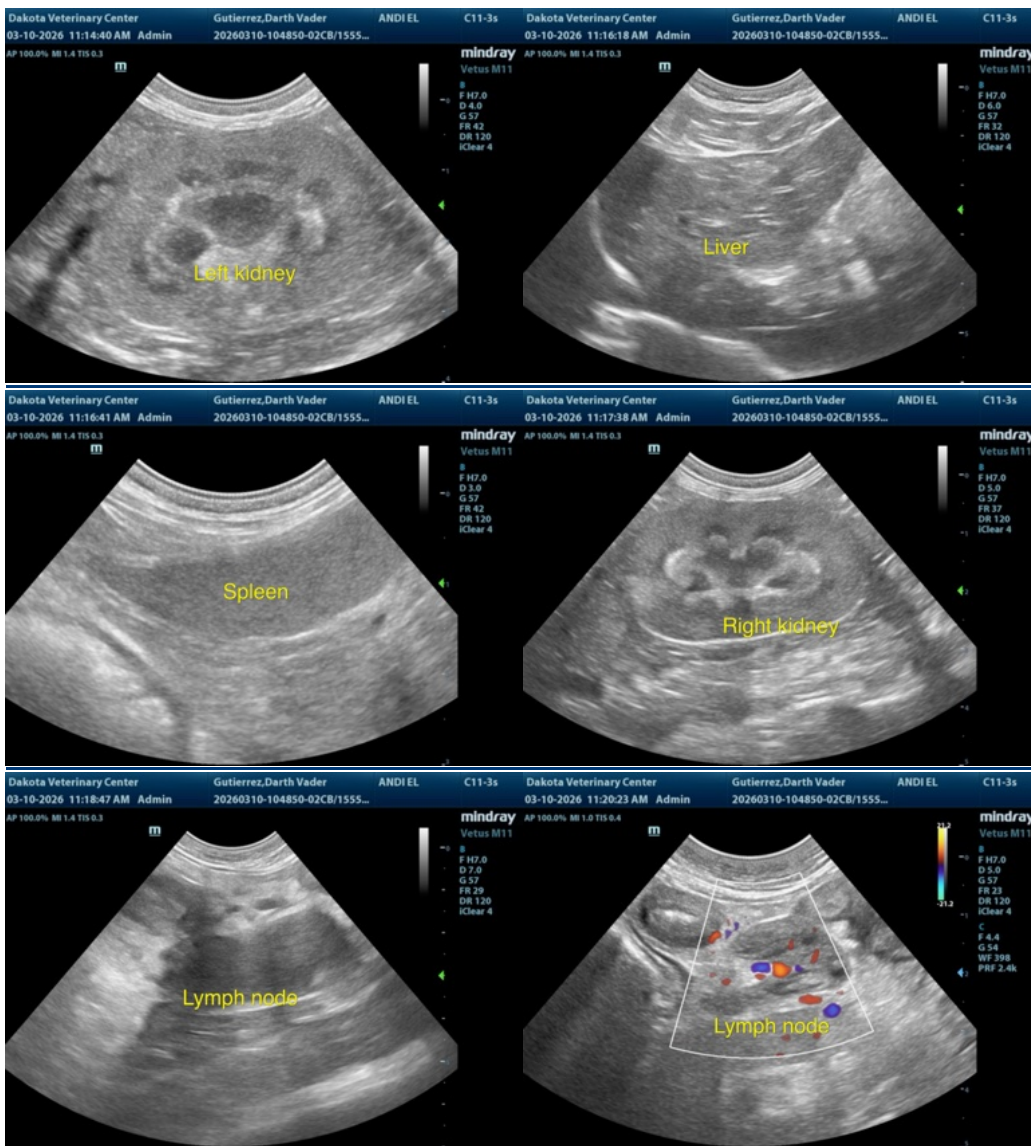
Dr. Stranzl

INVOICE

73372

DATE

3/10/26





PATIENT

Darth Vader Gutierrez

SPECIES

Feline

BREED

Domestic Shorthair

SEX

Neutered male

AGE

12 years

WEIGHT

14.2 lbs

INTERPRETED BY

Remo Lobetti, BVSc,
MMedVet (Med),
PhD, Dipl. ECVIM

IMAGING PERFORMED BY

Dr. Stranzl

HOSPITAL NAME

Dakota VC

REFERRING VET

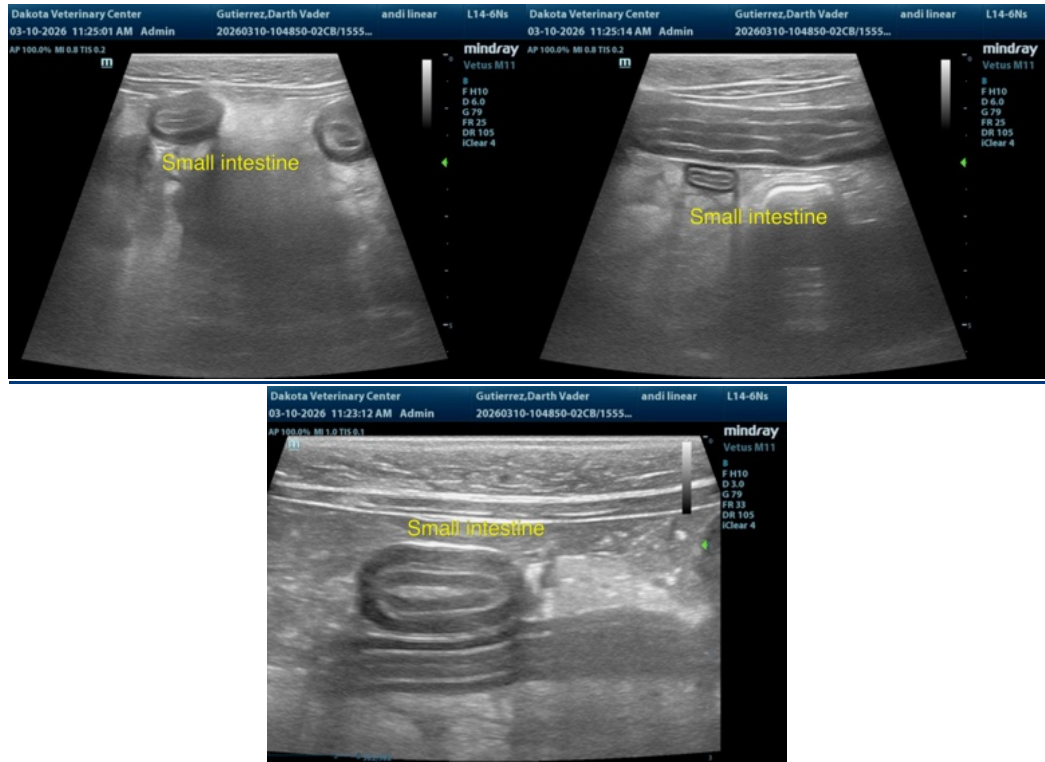
Dr. Stranzl

INVOICE

73372

DATE

3/10/26



The information and recommendations provided are based on the images presented by the referring veterinarian/sonographer. No evaluation can be communicated regarding pathology that was not visible in the image/video clips provided.

Thank you for this referral. If the clinical or image interpretation does not parallel your findings or if I can be of any further assistance please contact me.

Remo Lobetti, BVSc, MMedVet (Med), PhD, Dipl. ECVIM (Internal Medicine)

info@sonopath.com