



PATIENT

Skipper Welsh

SPECIES

Canine

BREED

Golden Retriever

SEX

Intact male

AGE

8 years

WEIGHT

79.4 lbs

INTERPRETED BY

Remo Lobetti, BVSc,
MMedVet (Med),
PhD, Dipl. ECVIM

IMAGING PERFORMED BY

Dr. Jones

HOSPITAL NAME

Northwind AH

REFERRING VET

Dr. Jones

INVOICE

71379

DATE

2/9/26

PRESENTING CLINICAL SIGNS

P has hypercalcemia with renal disease recently noted. P was previously just PU/PD but now is vomiting at every meal (yellow bile). Mild weight loss. Concerned about possible neoplasia or other reason for the clinical signs and hypercalcemia

ULTRASONOGRAPHIC EXAMINATION OF THE ABDOMEN

Urinary System

The urinary bladder is small with a normal thickness and smooth appearance of the wall. Normal anechoic urine with no sediment or uroliths evident.

Normal appearance of the trigone area, proximal urethra, and iliac blood vessels.

Normal appearance and size of the iliac lymph nodes. Ureters not visualized, which can be considered a normal finding.

Normal renal size (left measured 7.0 cm, right measured 8.0 cm), architecture, echogenic appearance, cortico-medullary differentiation, which maintains a 1:3 cortex to medulla ratio, pelvis, and capsule. No infarcts, mineralization or renoliths evident. Normal color flow pattern is evident in both kidneys.

Normal size and appearance of the prostate measuring 3.0 x 3.5 cm in size.

Adrenal Glands

The left adrenal gland is normal in shape, echogenic appearance, size, position, and appearance of the visible peri-adrenal vasculature. Left adrenal gland measured 0.46 cm and 0.52 cm in width. The right adrenal gland was not visualized, but appears to be of normal shape, echogenic appearance and size.

Spleen

Normal size and echogenic appearance. Smooth homogenous parenchyma and regular curvilinear capsule. Normal volume of the splenic vasculature without any overt congestion or thrombosis evident. No inflammatory, neoplastic, infarction, or infiltrative changes evident. The spleen measured 2.2 cm in width.

Liver

Normal size, echogenic appearance, portal markings, and regular curvilinear capsule. No nodules or masses evident. Normal appearance of the hepatic and portal vasculature.

Gallbladder

The gallbladder is full containing normal anechoic bile. Normal thickness and echogenic appearance of the wall. Normal size and appearance of the cystic and common bile duct.



PATIENT

Skipper Welsh

SPECIES

Canine

BREED

Golden Retriever

SEX

Intact male

AGE

8 years

WEIGHT

79.4 lbs

INTERPRETED BY

Remo Lobetti, BVSc,
MMedVet (Med),
PhD, Dipl. ECVIM

IMAGING PERFORMED BY

Dr. Jones

HOSPITAL NAME

Northwind AH

REFERRING VET

Dr. Jones

INVOICE

71379

DATE

2/9/26

Gastrointestinal

Normal appearance of the stomach, duodenum, small intestine, ileo-cecal junction, and colon with no loss of layering, 1:3 muscularis to mucosa ratio, normal wall thickness and peristaltic activity, and no distension of the lumen.

Pancreas

The visible sections of the pancreas are of normal size and echogenic appearance with a regular capsule. Normal echogenic appearance of the mesentery and fat surrounding the pancreas.

Free Abdomen

Normal mesenteric lymph nodes.

No ascites evident.

Irregular, hypoechogenic non-vascularized mass in the mid cranial abdomen measuring 2.5 x 4.0 cm in size and is not associated with any obvious organ system.

ULTRASONOGRAPHIC FINDINGS

- Abdominal mass.

INTERPRETATION OF THE FINDINGS & FURTHER RECOMMENDATIONS

The most likely etiology for the abdominal mass would be neoplasia with granuloma a less likely differential diagnosis.

The hypercalcemia can be attributed to the abdominal mass.

Possible organs of origin would be mesenteric lymph node or the mesentery.

Further assessment would be three view thoracic radiographs and FNA cytology of the mass.

Specific therapy would be dependent on an etiological diagnosis.



PATIENT

Skipper Welsh

SPECIES

Canine

BREED

Golden Retriever

SEX

Intact male

AGE

8 years

WEIGHT

79.4 lbs

INTERPRETED BY

Remo Lobetti, BVSc,
MMedVet (Med),
PhD, Dipl. ECVIM

IMAGING PERFORMED BY

Dr. Jones

HOSPITAL NAME

Northwind AH

REFERRING VET

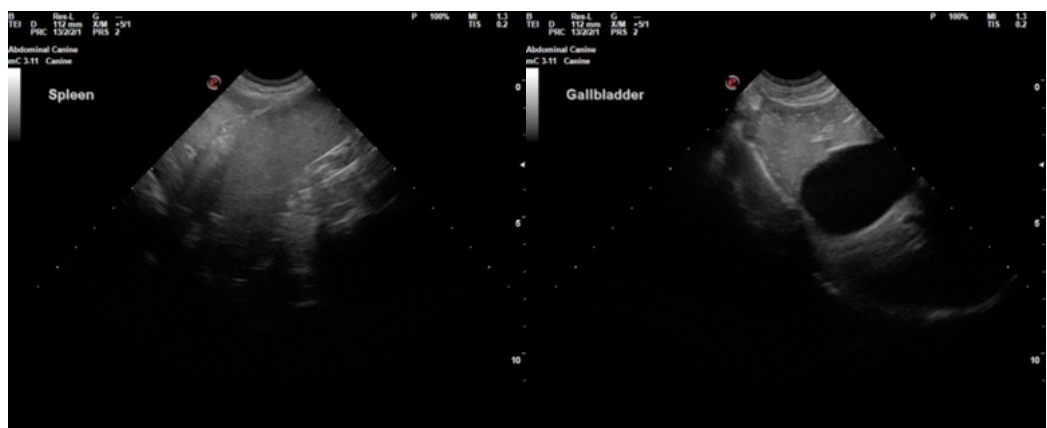
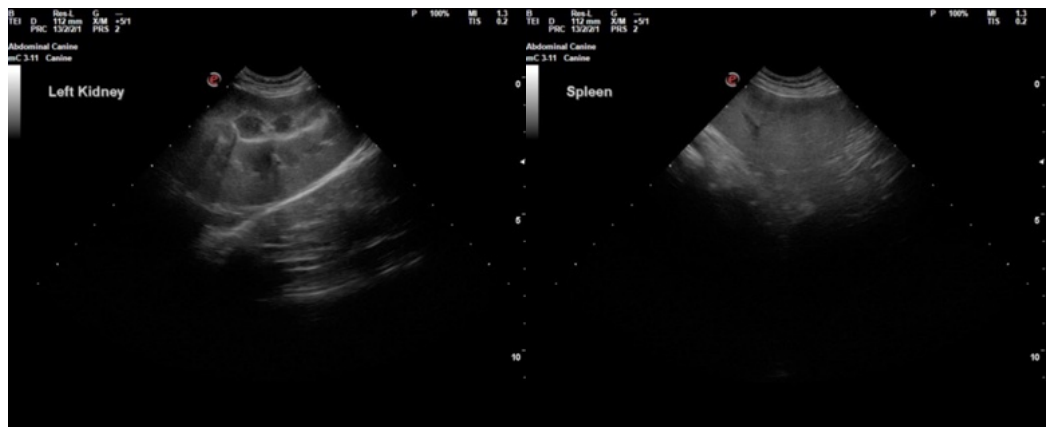
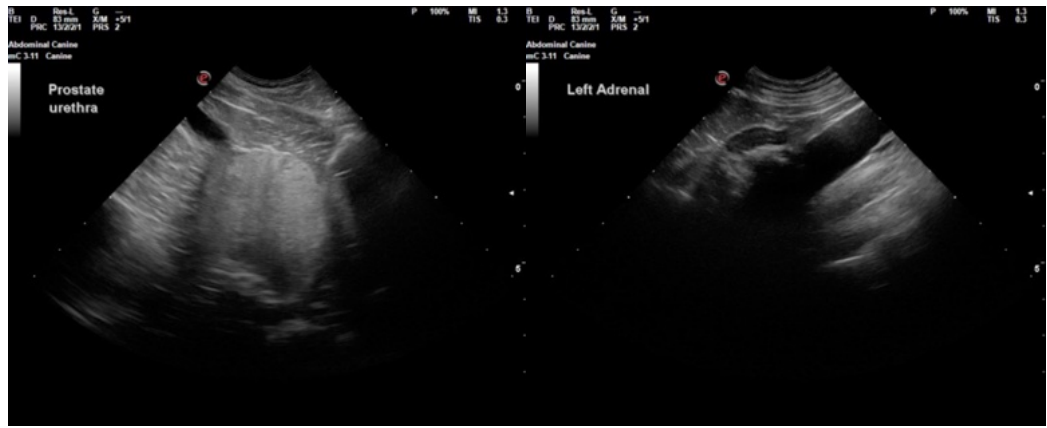
Dr. Jones

INVOICE

71379

DATE

2/9/26





PATIENT

Skipper Welsh

SPECIES

Canine

BREED

Golden Retriever

SEX

Intact male

AGE

8 years

WEIGHT

79.4 lbs

INTERPRETED BY

Remo Lobetti, BVSc,
MMedVet (Med),
PhD, Dipl. ECVIM

IMAGING PERFORMED BY

Dr. Jones

HOSPITAL NAME

Northwind AH

REFERRING VET

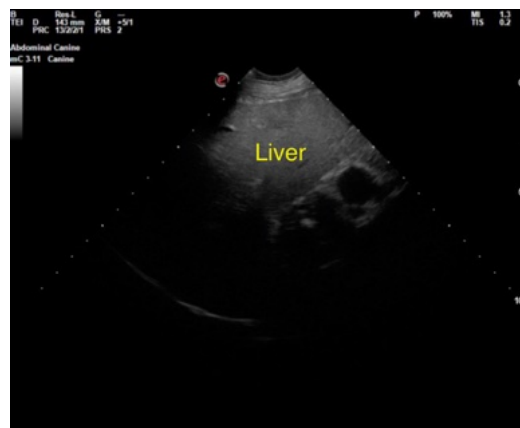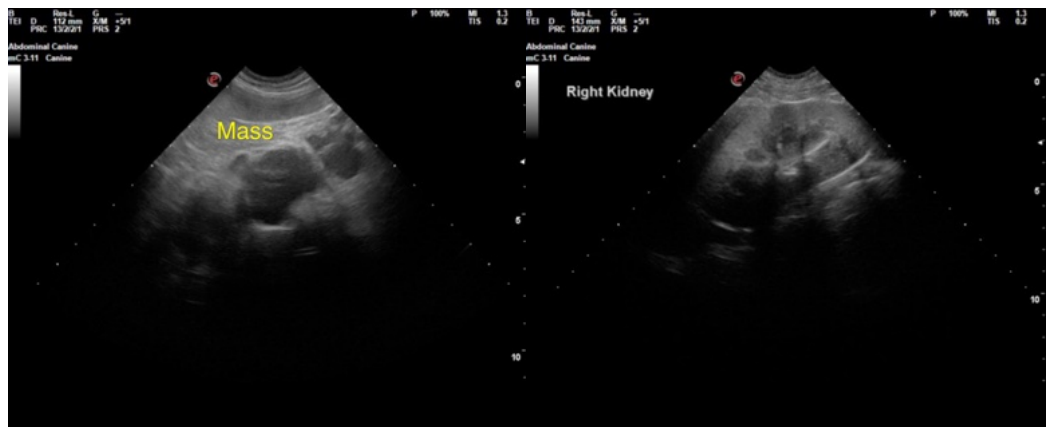
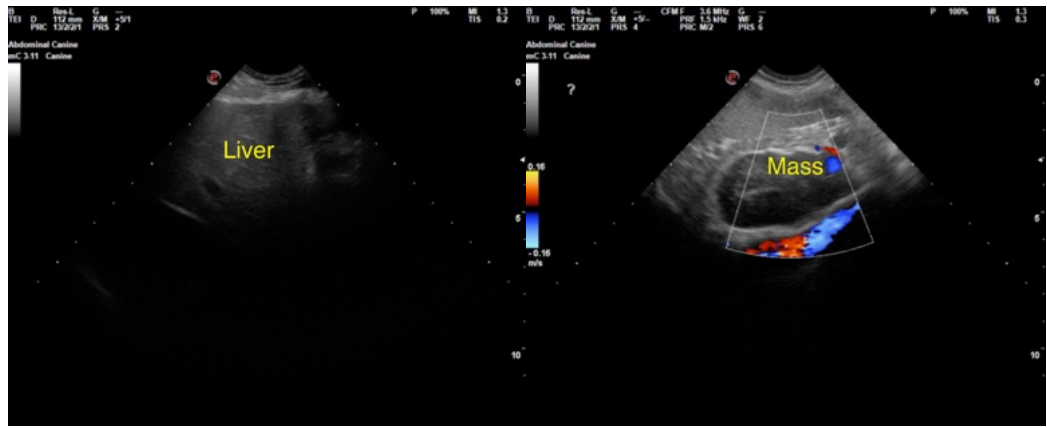
Dr. Jones

INVOICE

71379

DATE

2/9/26



The information and recommendations provided are based on the images presented by the referring veterinarian/sonographer. No evaluation can be communicated regarding pathology that was not visible in the image/video clips provided.

Thank you for this referral. If the clinical or image interpretation does not parallel your findings or if I can be of any further assistance please contact me.

Remo Lobetti, BVSc, MMedVet (Med), PhD, Dipl. ECVIM (Internal Medicine)
info@sonopath.com