



PATIENT

Poe Swenson

SPECIES

Feline

BREED

Domestic Medium Hair

SEX

Neutered male

AGE

8 years

WEIGHT

12.5 lbs

INTERPRETED BY

Remo Lobetti, BVSc,
MMedVet (Med),
PhD, Dipl. ECVIM

IMAGING PERFORMED BY

Dr. Ukachi Ugorji

HOSPITAL NAME

Craig Road AH

REFERRING VET

Dr. Ugorji

INVOICE

71420

DATE

2/9/26

PRESENTING CLINICAL SIGNS

- 8-year-old neutered male domestic longhair presented for hyporexia/anorexia since approximately one week. Owner reports Poe will take treats (e.g., Churu-type, hydration treat) and lick gravy from wet food but will not eat chunks or kibble. Lip smacking noted. History of intermittent vomiting a few months ago that resolved. No diarrhea reported. Weight loss noted by owner. Possible chronic cough mentioned by owner in context of a chronic heart condition. No records provided at intake, but owner states Poe was seen at Sunridge/Sunrise Animal Hospital on 02/07/26 for same issue and received antiemetic injection and an appetite stimulant. EDUD: Eating markedly decreased; drinking not specified; urination not specified; defecation without diarrhea per owner. No vaccine or medication allergies reported. No recent travel reported.

ULTRASONOGRAPHIC EXAMINATION OF THE ABDOMEN

Urinary System

The urinary bladder is full with a normal thickness and smooth appearance of the wall. A scant amount of floating, hyperechogenic sediment.

Normal appearance of the trigone area, proximal urethra, and iliac blood vessels.

Normal appearance and size of the iliac lymph nodes. Ureters not visualized, which can be considered a normal finding.

Normal renal size (left measured 4.2 cm, right measured 4.2 cm), architecture, echogenic appearance, cortico-medullary differentiation, which maintains a 1:3 cortex to medulla ratio, pelvis, and capsule. No infarcts, mineralization or renoliths evident. Normal color flow pattern is noted.

Adrenal Glands

Normal shape, echogenic appearance, size, position, and appearance of the visible peri-adrenal vasculature. Left adrenal gland measured 1.1 cm in length x 0.35 cm in width. The right adrenal gland measured 0.96 cm in length x 0.3 cm in width.

Spleen

Normal size and echogenic appearance. Smooth homogenous parenchyma and regular curvilinear capsule. Normal volume of the splenic vasculature without any overt congestion or thrombosis evident. No inflammatory, neoplastic, infarction, or infiltrative changes evident. The spleen measured 0.6 cm in width.

Liver

Normal size, echogenic appearance, portal markings, and regular curvilinear capsule. No nodules or masses evident. Normal appearance of the hepatic and portal vasculature.



PATIENT

Poe Swenson

SPECIES

Feline

BREED

Domestic Medium Hair

SEX

Neutered male

AGE

8 years

WEIGHT

12.5 lbs

INTERPRETED BY

Remo Lobetti, BVSc,
MMedVet (Med),
PhD, Dipl. ECVIM

IMAGING PERFORMED BY

Dr. Ukachi Ugorji

HOSPITAL NAME

Craig Road AH

REFERRING VET

Dr. Ugorji

INVOICE

71420

DATE

2/9/26

Gallbladder

The gallbladder is full containing normal anechoic bile. Normal thickness and echogenic appearance of the wall. Normal size and appearance of the cystic and common bile duct.

Gastrointestinal

Normal appearance of the stomach, duodenum, small intestine, ileo-cecal junction, and colon with no loss of layering, 1:3 muscularis to mucosa ratio, normal wall thickness and peristaltic activity, and no distension of the lumen.

Pancreas

Normal size (left pancreas measured 0.4 cm in width) with a hypoechoic appearance and an irregular capsule. Hyperechoic appearance of the mesentery and fat surrounding the pancreas. The visible pancreatic duct measured 0.2 cm in diameter.

Free Abdomen

Normal mesenteric lymph nodes.

No ascites evident.

ULTRASONOGRAPHIC FINDINGS

- Pancreatitis.

INTERPRETATION OF THE FINDINGS & FURTHER RECOMMENDATIONS

Further assessment would be FPL/PSL assay.

Management of the pancreatitis would be fluid therapy as needed, correction of any electrolyte anomalies, analgesics, antiemetics and feeding small frequent meals of a low-fat intestinal type diet.



PATIENT

Poe Swenson

SPECIES

Feline

BREED

Domestic Medium Hair

SEX

Neutered male

AGE

8 years

WEIGHT

12.5 lbs

INTERPRETED BY

Remo Lobetti, BVSc,
MMedVet (Med),
PhD, Dipl. ECVIM

IMAGING PERFORMED BY

Dr. Ukachi Ugorji

HOSPITAL NAME

Craig Road AH

REFERRING VET

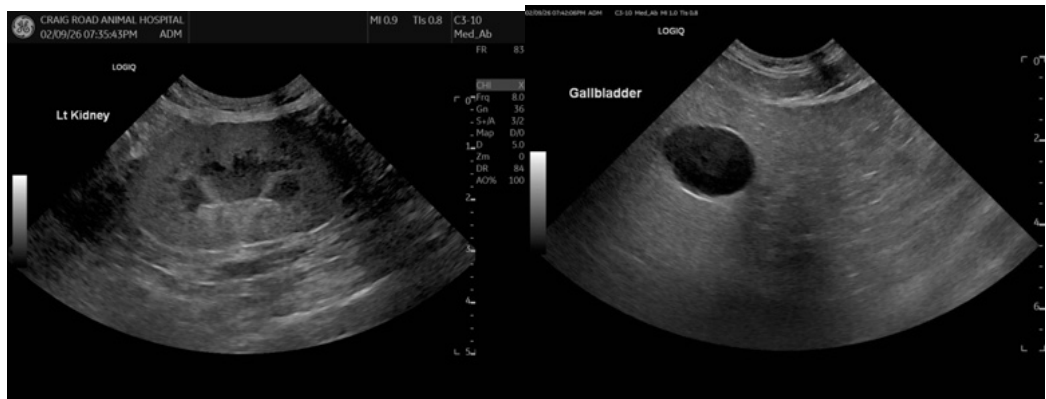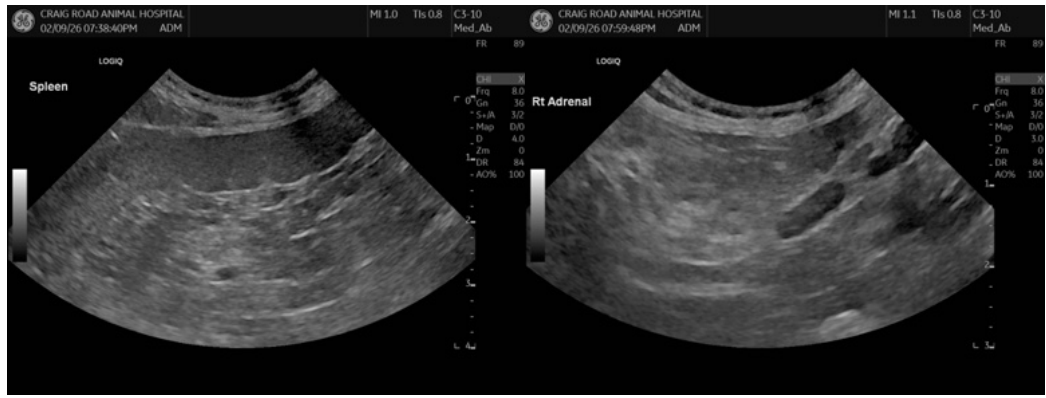
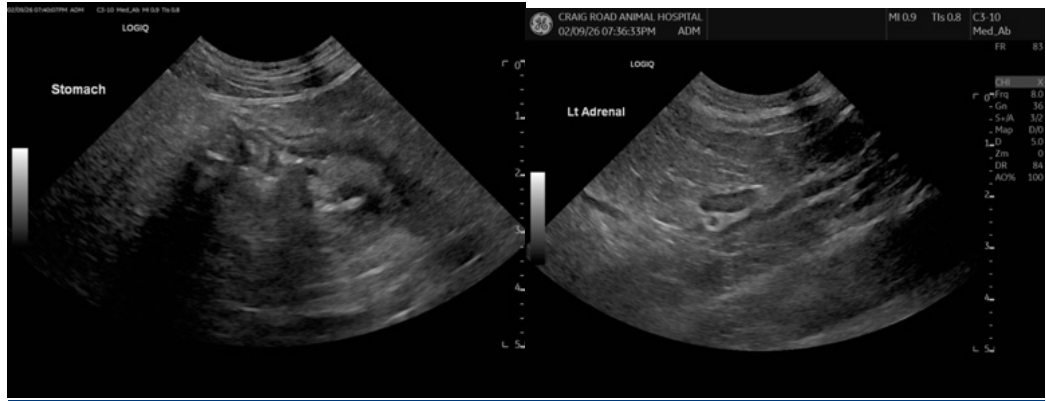
Dr. Ugorji

INVOICE

71420

DATE

2/9/26





PATIENT

Poe Swenson

SPECIES

Feline

BREED

Domestic Medium Hair

SEX

Neutered male

AGE

8 years

WEIGHT

12.5 lbs

INTERPRETED BY

Remo Lobetti, BVSc,
MMedVet (Med),
PhD, Dipl. ECVIM

IMAGING PERFORMED BY

Dr. Ukachi Ugorji

HOSPITAL NAME

Craig Road AH

REFERRING VET

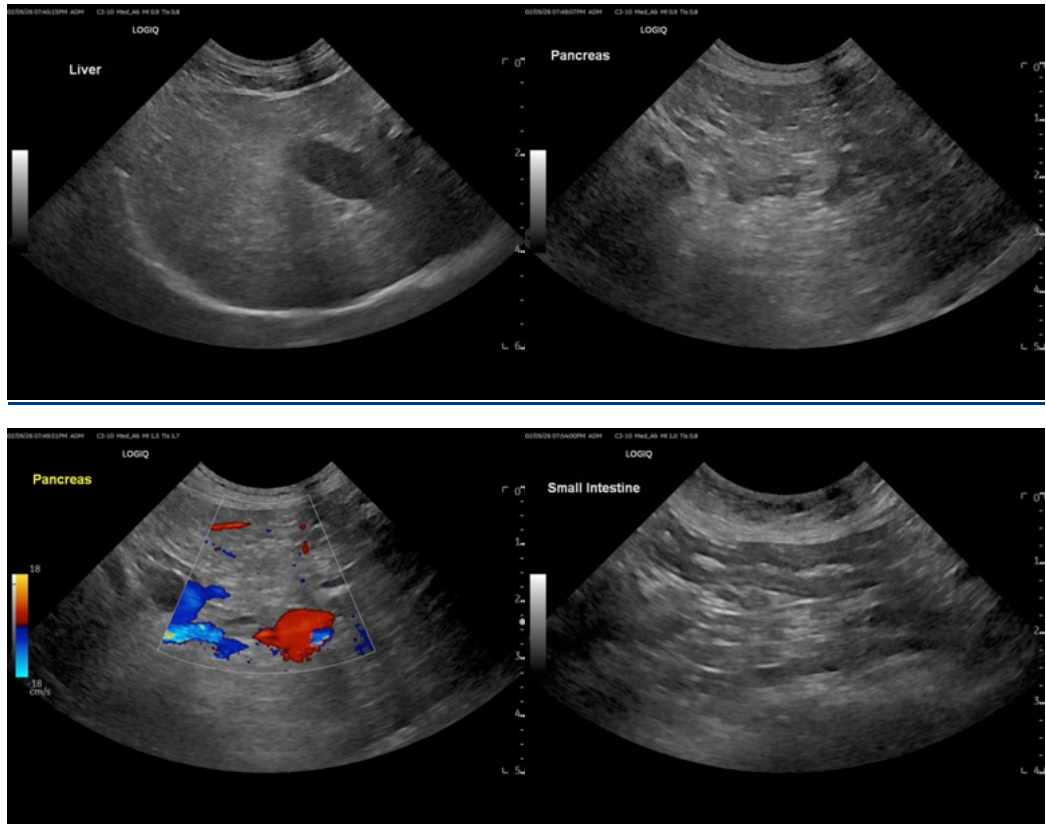
Dr. Ugorji

INVOICE

71420

DATE

2/9/26



The information and recommendations provided are based on the images presented by the referring veterinarian/sonographer. No evaluation can be communicated regarding pathology that was not visible in the image/video clips provided.

Thank you for this referral. If the clinical or image interpretation does not parallel your findings or if I can be of any further assistance please contact me.

Remo Lobetti, BVSc, MMedVet (Med), PhD, Dipl. ECVIM (Internal Medicine)

info@sonopath.com