



## PATIENT

Lexi Sagot

## SPECIES

Canine

## BREED

Mix

## SEX

Spayed female

## AGE

13 years

## WEIGHT

55 lbs

## INTERPRETED BY

Remo Lobetti, BVSc,  
MMedVet (Med),  
PhD, Dipl. ECVIM

## IMAGING PERFORMED BY

Dr. Scott

## HOSPITAL NAME

Wyckoff VH

## REFERRING VET

Dr. Eisenberg

## INVOICE

71381

## DATE

2/9/26

## PRESENTING CLINICAL SIGNS

- Decreased app, PU/PD, urinary accidents
- long history of occasional vomiting
- PE - skin issues improved CBC/chem WNL, T bili 0.4 USG about a week ago was 1.035

## ULTRASONOGRAPHIC EXAMINATION OF THE ABDOMEN

### *Urinary System*

The urinary bladder is small with a normal thickness and smooth appearance of the wall. Normal anechoic urine with no sediment or uroliths evident.

Normal appearance of the trigone area, proximal urethra, and iliac blood vessels.

Normal appearance and size of the iliac lymph nodes. Ureters not visualized, which can be considered a normal finding.

Normal renal size (left measured 6.0 cm, right measured 6.5 cm), architecture, echogenic appearance, cortico-medullary differentiation, which maintains a 1:3 cortex to medulla ratio, pelvis, and capsule. No infarcts, mineralization or renoliths evident.

### *Adrenal Glands*

The adrenal glands are not clearly visualized, but both appear to be of normal shape, echogenic appearance and size.

### *Spleen*

Normal size and echogenic appearance. Smooth homogenous parenchyma and regular curvilinear capsule. Normal volume of the splenic vasculature without any overt congestion or thrombosis evident. No inflammatory, neoplastic, infarction, or infiltrative changes evident. The spleen measured 1.2 cm in width.

### *Liver*

Normal size, echogenic appearance, portal markings, and regular curvilinear capsule. No nodules or masses evident. Normal appearance of the hepatic and portal vasculature.

### *Gallbladder*

The gallbladder is small containing normal anechoic bile. Normal thickness and echogenic appearance of the wall. Normal size and appearance of the cystic and common bile duct.



## PATIENT

Lexi Sagot

## SPECIES

Canine

## BREED

Mix

## SEX

Spayed female

## AGE

13 years

## WEIGHT

55 lbs

## INTERPRETED BY

Remo Lobetti, BVSc,  
MMedVet (Med),  
PhD, Dipl. ECVIM

## IMAGING PERFORMED BY

Dr. Scott

## HOSPITAL NAME

Wyckoff VH

## REFERRING VET

Dr. Eisenberg

## INVOICE

71381

## DATE

2/9/26

## *Gastrointestinal*

Normal appearance of the stomach, duodenum, small intestine, ileo-cecal junction, and colon with no loss of layering, 1:3 muscularis to mucosa ratio, normal wall thickness and peristaltic activity, and no distension of the lumen.

## *Pancreas*

The visible sections of the pancreas are of normal size and echogenic appearance with a regular capsule. Normal echogenic appearance of the mesentery and fat surrounding the pancreas.

## *Free Abdomen*

Normal mesenteric lymph nodes.

No ascites evident.

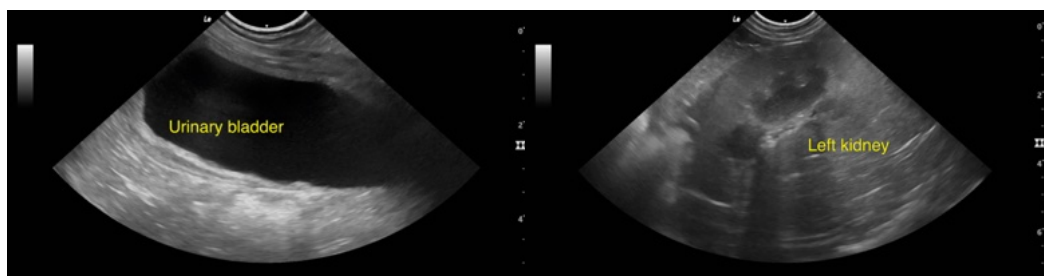
## ULTRASONOGRAPHIC FINDINGS

- Normal ultrasound examination of the abdomen.

## INTERPRETATION OF THE FINDINGS & FURTHER RECOMMENDATIONS

A urine specific gravity of 1.035 is unlikely to cause polyuria/polydipsia. It is possible that the owner is misinterpreting polyuria/polydipsia for urinary incontinence.

Specific therapy would be dependent on an etiological diagnosis.





## PATIENT

Lexi Sagot

## SPECIES

Canine

## BREED

Mix

## SEX

Spayed female

## AGE

13 years

## WEIGHT

55 lbs

## INTERPRETED BY

Remo Lobetti, BVSc,  
MMedVet (Med),  
PhD, Dipl. ECVIM

## IMAGING PERFORMED BY

Dr. Scott

## HOSPITAL NAME

Wyckoff VH

## REFERRING VET

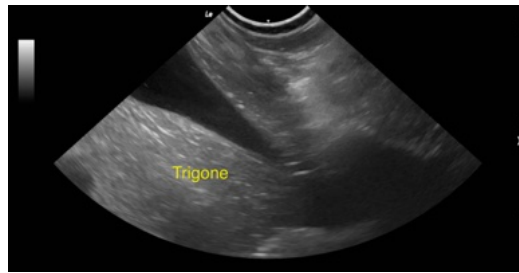
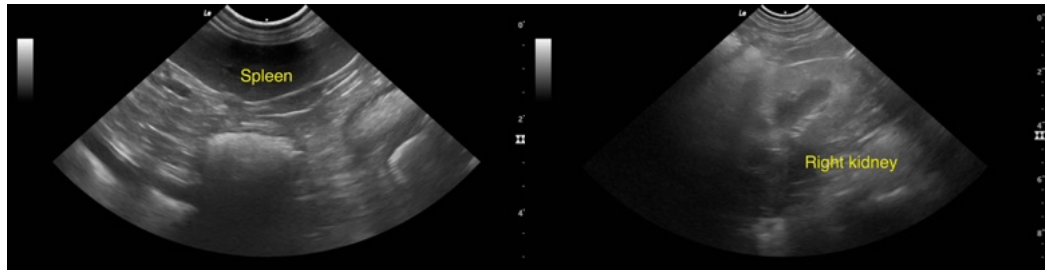
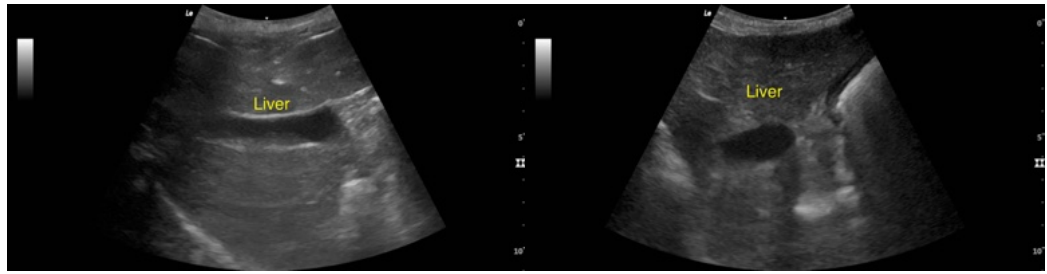
Dr. Eisenberg

## INVOICE

71381

## DATE

2/9/26



The information and recommendations provided are based on the images presented by the referring veterinarian/sonographer. No evaluation can be communicated regarding pathology that was not visible in the image/video clips provided.

Thank you for this referral. If the clinical or image interpretation does not parallel your findings or if I can be of any further assistance please contact me.

Remo Lobetti, BVSc, MMedVet (Med), PhD, Dipl. ECVIM (Internal Medicine)

[info@sonopath.com](mailto:info@sonopath.com)