



PATIENT

Kit Paluba

SPECIES

Canine

BREED

Golden Retriever

SEX

Spayed female

AGE

10 years

WEIGHT

46 lbs

INTERPRETED BY

Remo Lobetti, BVSc,
MMedVet (Med),
PhD, Dipl. ECVIM

IMAGING PERFORMED BY

Dr. Emily Shotts

HOSPITAL NAME

Riverbend Veterinary
Pet Care Hospital

REFERRING VET

Dr. Shotts

INVOICE

71342

DATE

2/6/26

PRESENTING CLINICAL SIGNS

- Approximately 10 year old FS golden retriever that was adopted from Turkey in 2023. Patient presented on 1/28/2026 for her annual where bloodwork revealed a mild non-regenerative anemia (RBC 5.77 m/uL, HCT 40.1%, reticulocytes 17 k/uL) with otherwise unremarkable bloodwork. Pet was noted to be more clingy at home and had a new SQ lump, but otherwise normal. On cytology the lump was compatible with a keratin inclusion cyst. Path review of CBC confirmed a slight/mild non-regenerative anemia based on polychromasia and reticulocyte count. The cause was not apparent. No hemotropic organisms or significant RBC morphologic abnormalities were appreciated. Medications include apoquel, simparica and proheart annually.

ULTRASONOGRAPHIC EXAMINATION OF THE ABDOMEN

Urinary System

The urinary bladder is small with a normal thickness and smooth appearance of the wall. Normal anechoic urine with no sediment or uroliths evident.

Normal appearance of the trigone area, proximal urethra, and iliac blood vessels.

Normal appearance and size of the iliac lymph nodes. Ureters not visualized, which can be considered a normal finding.

Normal renal size (left measured 6.6 cm, right measured 7.2 cm), architecture, echogenic appearance, cortico-medullary differentiation, which maintains a 1:3 cortex to medulla ratio, pelvis, and capsule. No infarcts, mineralization or renoliths evident.

Adrenal Glands

Normal shape, echogenic appearance, size, position, and appearance of the visible peri-adrenal vasculature. Left adrenal gland measured 0.42 cm in width. The right adrenal gland measured 0.46 cm in width.

Spleen

Normal size and echogenic appearance. Smooth homogenous parenchyma and regular curvilinear capsule. Normal volume of the splenic vasculature without any overt congestion or thrombosis evident. No inflammatory, neoplastic, infarction, or infiltrative changes evident. The spleen measured 2.2 cm in width.

Liver

Normal size, echogenic appearance, portal markings, and regular curvilinear capsule. No nodules or masses evident. Normal appearance of the hepatic and portal vasculature.



PATIENT

Kit Paluba

SPECIES

Canine

BREED

Golden Retriever

SEX

Spayed female

AGE

10 years

WEIGHT

46 lbs

INTERPRETED BY

Remo Lobetti, BVSc,
MMedVet (Med),
PhD, Dipl. ECVIM

IMAGING PERFORMED BY

Dr. Emily Shotts

HOSPITAL NAME

Riverbend Veterinary
Pet Care Hospital

REFERRING VET

Dr. Shotts

INVOICE

71342

DATE

2/6/26

Gallbladder

The gallbladder is full containing normal anechoic bile. Normal thickness and echogenic appearance of the wall. Normal size and appearance of the cystic and common bile duct.

Gastrointestinal

Normal appearance of the stomach, duodenum, small intestine, ileo-cecal junction, and colon with no loss of layering, 1:3 muscularis to mucosa ratio, normal wall thickness and peristaltic activity, and no distension of the lumen.

Pancreas

The visible sections of the pancreas are of normal size and echogenic appearance with a regular capsule. Normal echogenic appearance of the mesentery and fat surrounding the pancreas.

Free Abdomen

Normal mesenteric lymph nodes.

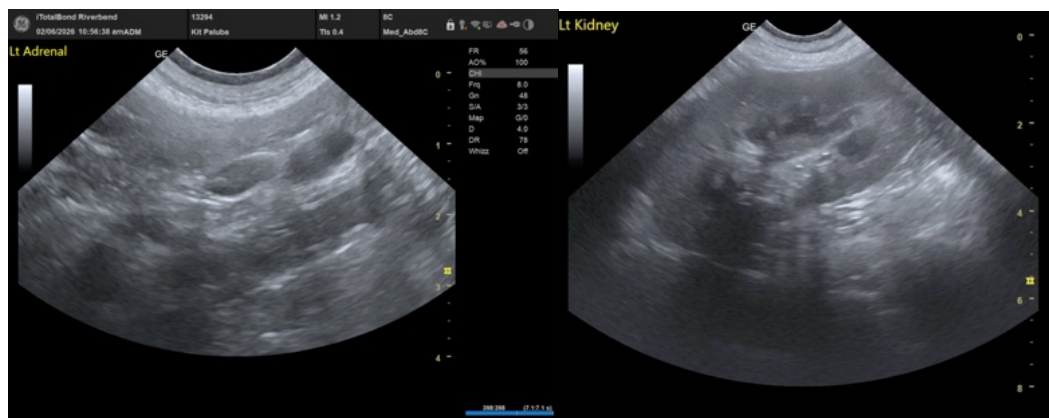
No ascites evident.

ULTRASONOGRAPHIC FINDINGS

- Normal ultrasound examination of the abdomen.

INTERPRETATION OF THE FINDINGS & FURTHER RECOMMENDATIONS

No specific therapy is recommended at this time.





PATIENT

Kit Paluba

SPECIES

Canine

BREED

Golden Retriever

SEX

Spayed female

AGE

10 years

WEIGHT

46 lbs

INTERPRETED BY

Remo Lobetti, BVSc,
MMedVet (Med),
PhD, Dipl. ECVIM

IMAGING PERFORMED BY

Dr. Emily Shotts

HOSPITAL NAME

Riverbend Veterinary
Pet Care Hospital

REFERRING VET

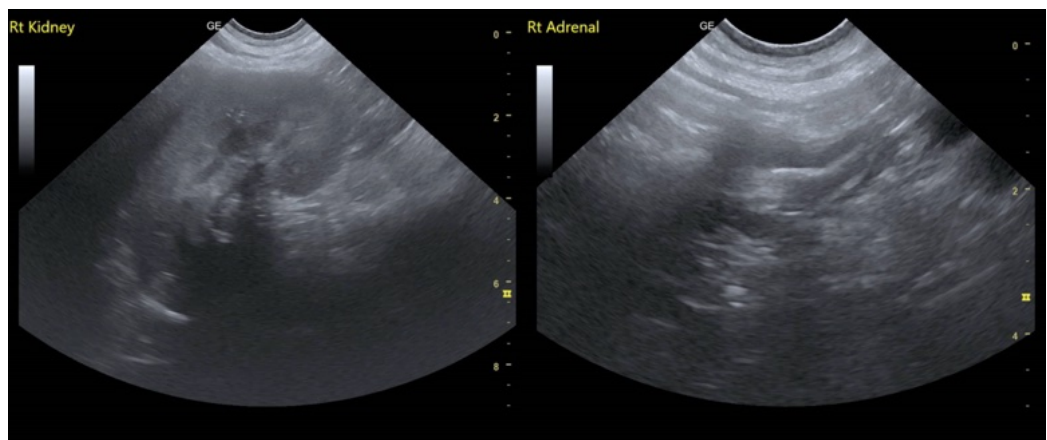
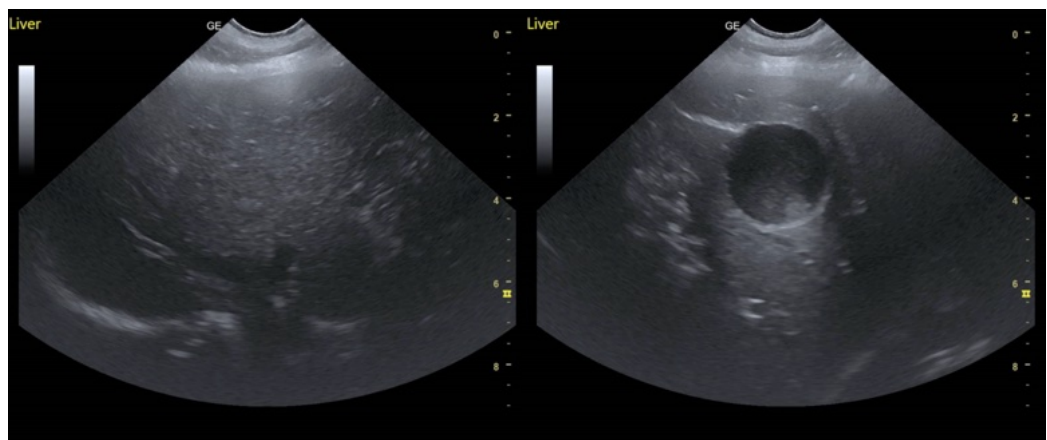
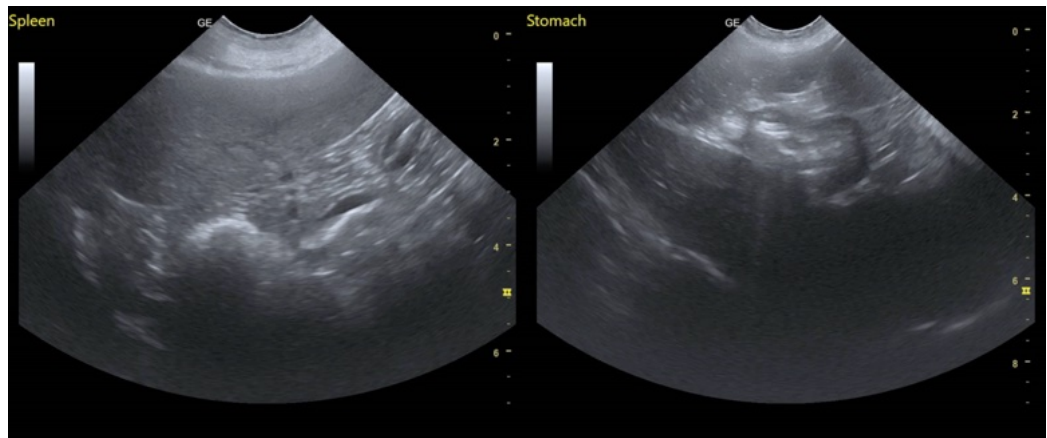
Dr. Shotts

INVOICE

71342

DATE

2/6/26





PATIENT

Kit Paluba

SPECIES

Canine

BREED

Golden Retriever

SEX

Spayed female

AGE

10 years

WEIGHT

46 lbs

INTERPRETED BY

Remo Lobetti, BVSc,
MMedVet (Med),
PhD, Dipl. ECVIM

IMAGING PERFORMED BY

Dr. Emily Shotts

HOSPITAL NAME

Riverbend Veterinary
Pet Care Hospital

REFERRING VET

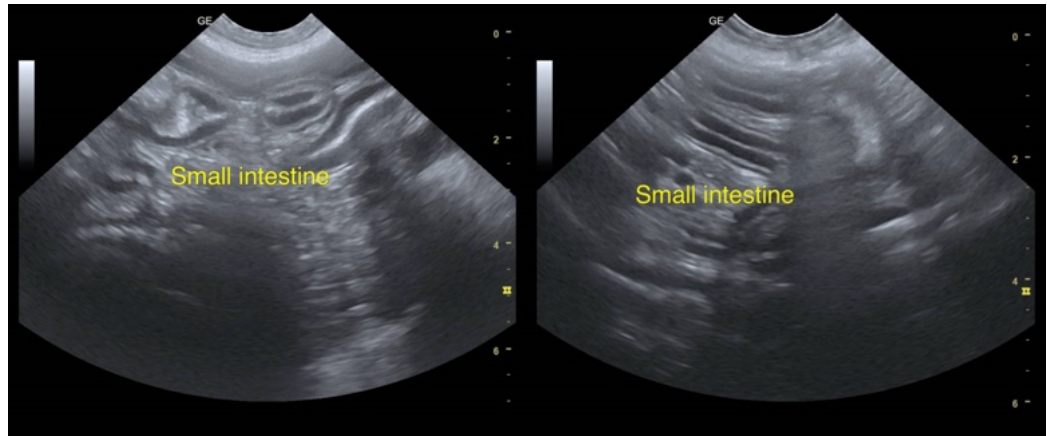
Dr. Shotts

INVOICE

71342

DATE

2/6/26



The information and recommendations provided are based on the images presented by the referring veterinarian/sonographer. No evaluation can be communicated regarding pathology that was not visible in the image/video clips provided.

Thank you for this referral. If the clinical or image interpretation does not parallel your findings or if I can be of any further assistance please contact me.

Remo Lobetti, BVSc, MMedVet (Med), PhD, Dipl. ECVIM (Internal Medicine)

info@sonopath.com