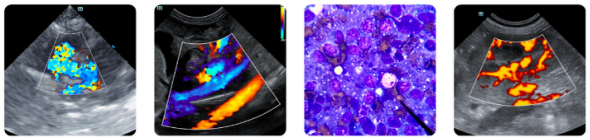

PATIENT

Bella St Denny

SPECIES

Canine

BREED

Pit Labrador

SEX

Female

AGE

13 years

WEIGHT

50.8 lbs

INTERPRETED BY

Remo Lobetti, BVSc, MMedVet (Med), PhD, Dipl. ECVIM

IMAGING PERFORMED BY

Danielle Shemanski, DVM, MA

HOSPITAL NAME

Western New York Vetererinay Service

REFERRING VET

Dr. Richard Beikirch

INVOICE

71345

DATE

2/6/26

PRESENTING CLINICAL SIGNS

- RDVM REASON FOR REFERRAL: Patient presented on 02/02/2026 for evaluation of an abdominal mass and decreased appetite leading to 10lb wt loss. A mass, approximately 18 cm in diameter, was palpated in the left cranial abdomen.
- A Grade I-II/VI systolic murmur was auscultated.
- Abdominal ultrasonography is recommended to differentiate the origin of the mass (splenic, renal, or other).
- She has a progressive history of degenerative myelopathy, causing forelimb weakness hind limb paralysis, and subsequent urinary incontinence (dark, smelly urine) and difficult, intermittent, incontinent defecation.
- MEDICATIONS: trazadone
- RDVM reports bloodwork is unremarkable

ULTRASONOGRAPHIC EXAMINATION OF THE ABDOMEN

Urinary System

The urinary bladder is full with a normal thickness and smooth appearance of the wall. A large amount of floating, hypoechogenic and hyperechogenic sediment. The urinary bladder wall measured 0.5 cm.

Normal appearance of the trigone area, proximal urethra, and iliac blood vessels.

Normal appearance and size of the iliac lymph nodes (1.0 x 1.18 cm). Ureters not visualized, which can be considered a normal finding.

Normal renal size (left measured 6.3 cm, right measured 7.3 cm), architecture, echogenic appearance, cortico-medullary differentiation, which maintains a 1:3 cortex to medulla ratio, pelvis, and capsule. No infarcts, mineralization or renoliths evident.

Adrenal Glands

Normal shape, echogenic appearance, size, position, and appearance of the visible peri-adrenal vasculature. Left adrenal gland measured 3.58 cm in length x 0.75 cm and 0.84 cm in width. The right adrenal gland measured 0.65 cm in width.

Spleen

Normal size and echogenic appearance. Smooth homogenous parenchyma and regular curvilinear capsule. Normal volume of the splenic vasculature without any overt congestion or thrombosis evident. No inflammatory, neoplastic, infarction, or infiltrative changes evident. The spleen measured 2.1 cm in width.

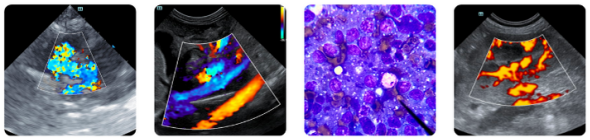

SonoPath.com info@sonopath.com 1.800.838.4268

PATIENT

Bella St Denny

SPECIES

Canine

BREED

Pit Labrador

SEX

Female

AGE

13 years

WEIGHT

50.8 lbs

INTERPRETED BY

Remo Lobetti, BVSc, MMedVet (Med), PhD, Dipl. ECVIM

IMAGING PERFORMED BY

Danielle Shemanski, DVM, MA

HOSPITAL NAME

Western New York Vetererinay Service

REFERRING VET

Dr. Richard Beikirch

INVOICE

71345

DATE

2/6/26

Liver

Normal size, echogenic appearance, portal markings, and regular curvilinear capsule. No nodules or masses evident. Normal appearance of the hepatic and portal vasculature.

Gallbladder

The gallbladder is full containing normal anechoic bile. Normal thickness and echogenic appearance of the wall. Normal size and appearance of the cystic and common bile duct.

Gastrointestinal

Normal appearance of the stomach, duodenum, small intestine, ileo-cecal junction, and colon with no loss of layering, 1:3 muscularis to mucosa ratio, normal wall thickness and peristaltic activity, and no distension of the lumen.

Pancreas

The visible sections of the pancreas are of normal size and echogenic appearance with a regular capsule. Normal echogenic appearance of the mesentery and fat surrounding the pancreas.

Free Abdomen

Normal mesenteric lymph nodes.

No ascites evident.

Large, irregular, mottled echogenic, cystic and non-vascularized mass in the midabdomen not associated with any obvious organ. The mass measures approximately 13 x 16 cm. FNA was taken of the mass.

Thorax

Normal appearance of the heart. No pericardial or pleural effusion evident.

ULTRASONOGRAPHIC FINDINGS

- Abdominal mass.
- Urinary bladder sediment.

PATIENT

Bella St Denny

SPECIES

Canine

BREED

Pit Labrador

SEX

Female

AGE

13 years

WEIGHT

50.8 lbs

INTERPRETED BY

Remo Lobetti, BVSc, MMedVet (Med), PhD, Dipl. ECVIM

IMAGING PERFORMED BY

Danielle Shemanski, DVM, MA

HOSPITAL NAME

Western New York Vetererinay Service

REFERRING VET

Dr. Richard Beikirch

INVOICE

71345

DATE

2/6/26

INTERPRETATION OF THE FINDINGS & FURTHER RECOMMENDATIONS

The most likely etiology for the abdominal mass would be neoplasia with granuloma and organized hematoma a less likely differential diagnosis.

Etiologies for the urinary bladder sediment would be incidental debris, hematuria and bacterial cystitis.

Further assessment would be based on the pending cytology results, but could include urinalysis and urine culture.

Specific therapy would be dependent on an etiological diagnosis.

Laparotomy can be considered as it may be both diagnostic and therapeutic with further specific therapy dependent on an etiological diagnosis.

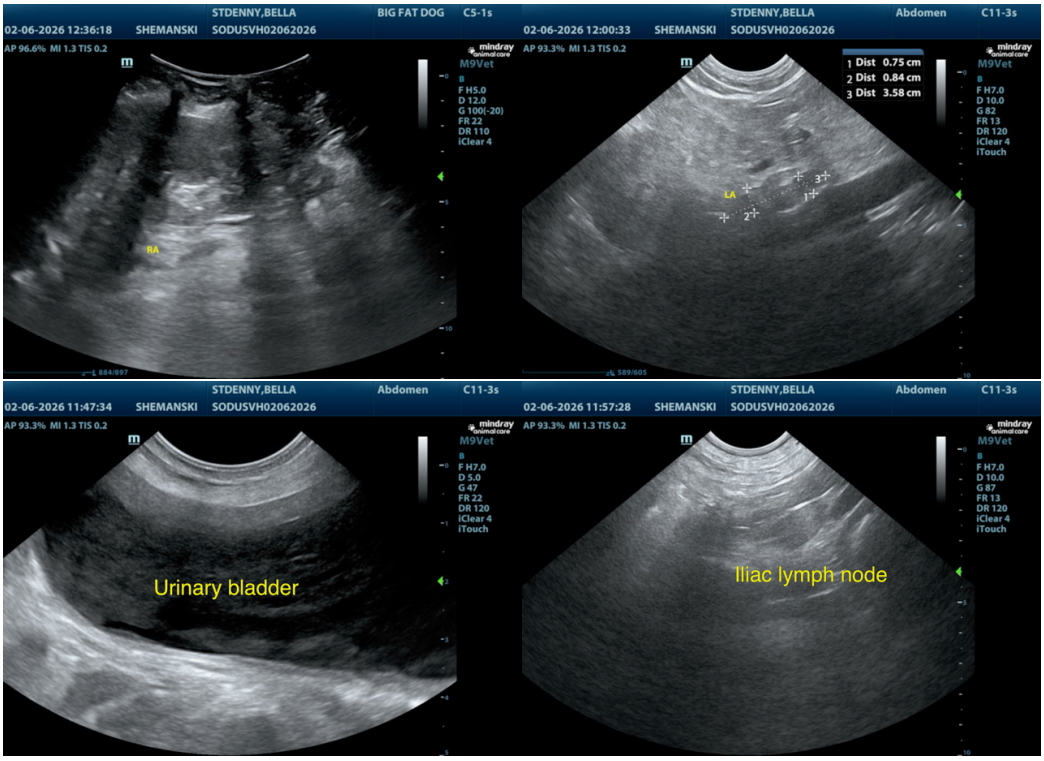

SonoPath
FOSTERING THE ART OF VETERINARY MEDICINE™

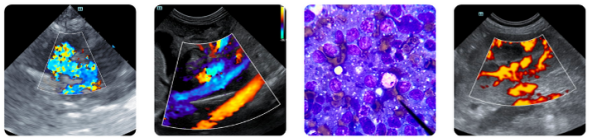

Clinical Sonography & Telecytology
Educational Teleconsultation Services™

SonoPath.com *info@sonopath.com* *1.800.838.4268*

PATIENT

Bella St Denny

SPECIES

Canine

BREED

Pit Labrador

SEX

Female

AGE

13 years

WEIGHT

50.8 lbs

INTERPRETED BY

Remo Lobetti, BVSc, MMedVet (Med), PhD, Dipl. ECVIM

IMAGING PERFORMED BY

Danielle Shemanski, DVM, MA

HOSPITAL NAME

Western New York Vetererinay Service

REFERRING VET

Dr. Richard Beikirch

INVOICE

71345

DATE

2/6/26

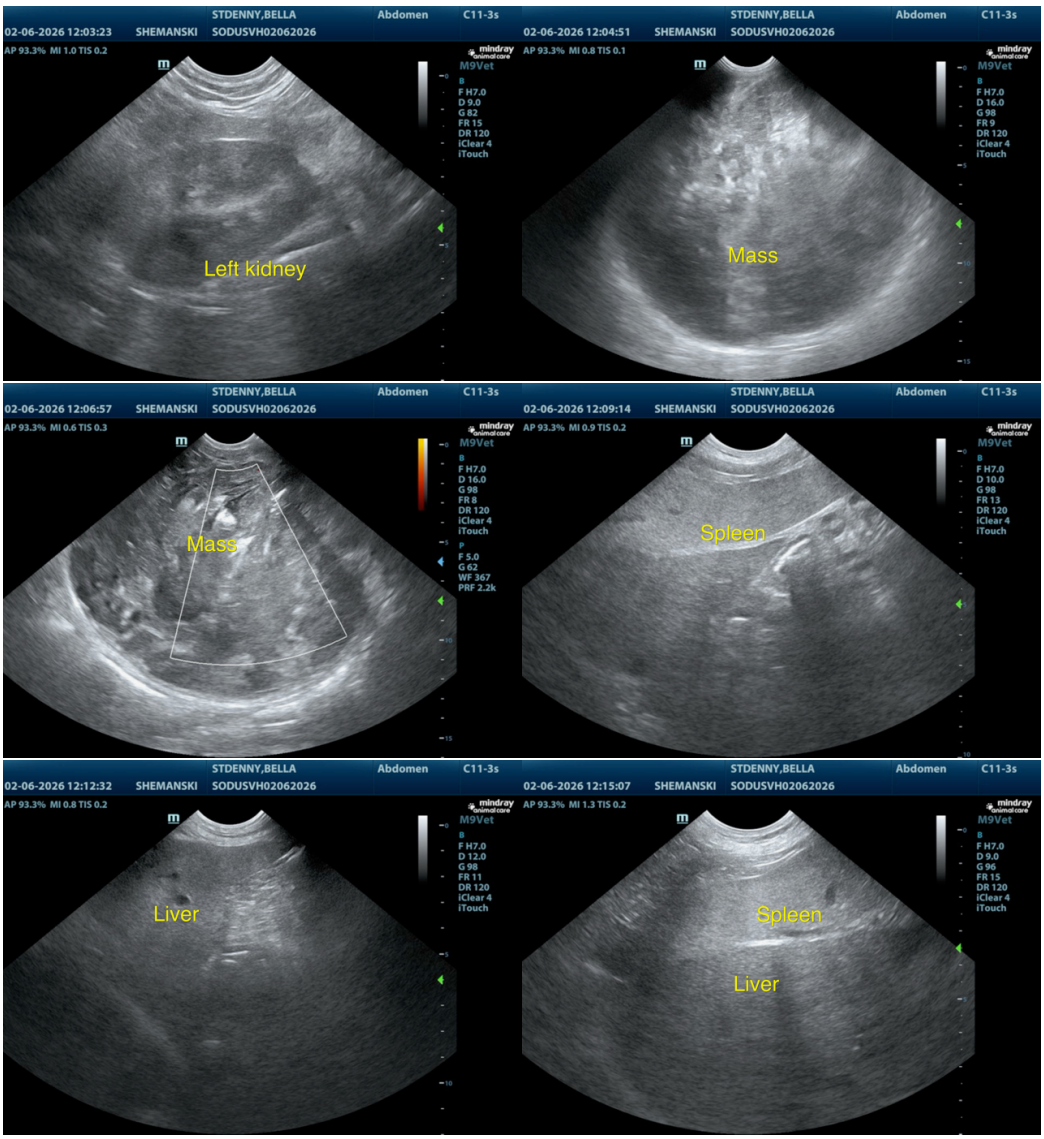

The information and recommendations provided are based on the images presented by the referring veterinarian/sonographer. No evaluation can be communicated regarding pathology that was not visible in the image/video clips provided.

Thank you for this referral. If the clinical or image interpretation does not parallel your findings or if I can be of any further assistance please contact me.

Remo Lobetti, BVSc, MMedVet (Med), PhD, Dipl. ECVIM (Internal Medicine)

info@sonopath.com